

Importance of Fluorescein Angiographic Study in Evaluating Early Retinal Changes in Takayasu Disease

Takayuki Baba,* Kyoko Itakura,* Ritsuko Tanaka,*
Tsutomu Kawasaki,* Motohiro Kiyosawa* and Fujio Numano[†]

**Department of Ophthalmology, and [†]Third Department of
Internal Medicine, Tokyo Medical and Dental University, School of Medicine, Tokyo, Japan*

Purpose: To determine the usefulness of fluorescein angiography in studying Takayasu disease.

Methods: We examined 31 eyes in 16 patients with Takayasu disease using indirect ophthalmoscopy, color photography, and fluorescein angiography. Ophthalmoscopic and fluorescein angiographic findings were compared.

Results: Fluorescein angiography revealed no additional retinal changes in 10 eyes that had no retinal vein dilatation as seen by indirect ophthalmoscopy. Seven (33%) of 21 eyes that had dilated retinal veins also had additional abnormal findings, such as microaneurysms, arteriovenous shunts, retinal neovascularization, and avascular areas. Some differences in grading the stages of retinopathy were noted with these newly found retinal changes, as compared with the classifications determined by ophthalmoscopy alone.

Conclusions: In Takayasu disease, studying the fundus of patients with fluorescein angiography is particularly important in correctly classifying the stages of retinopathy when the retinal vein appears dilated in ophthalmoscopic observation. **Jpn J Ophthalmol 1999;43:546-552**
© 1999 Japanese Ophthalmological Society

Key Words: Dilatation of retinal vessels, fluorescein angiography, stages of retinopathy, Takayasu disease.

Introduction

Takayasu disease is an autoimmune-related, chronic, inflammatory, and obstructive vascular disease distributed throughout the major branches of the aorta.¹ This disease occurs most often in young Asian women.² Systemic renovascular hypertension and hypertensive retinal changes have been observed when renal arteries are involved.³ The involvement of major branches of the aorta may reduce blood flow to the eyes, and hypoxic retinal changes may occur.⁴ In Japanese patients, the involvement of cervical vessels and poor perfusion to the eye are common.^{3,4} It has been reported that hy-

poxia-induced retinal changes include nonperfused areas, microaneurysms, arteriovenous anastomosis, and a corolla-shaped anastomosis of the retinal arteries around the optic disc.⁵⁻⁸ However, in many cases these changes may be quite subtle and located in the peripheral retina. Therefore, it is not easy to find minor retinal changes using indirect ophthalmoscopy. Accordingly, some authors have suggested the importance of fluorescein angiography in examining the fundus in patients with Takayasu disease to clearly reveal subtle changes.⁵⁻⁸ Tanaka and Shimizu⁸ have demonstrated that the progression of retinal changes shown by fluorescein angiography starts with venous dilatation and microaneurysms. Arteriovenous shunts and widening of the avascular area follow.⁸ We reported on the apparent reduction in the nonperfused area in a patient with Takayasu disease who had an artificial bypass operation from the femoral artery to the carotid artery,⁹ suggesting that retinal changes in Takayasu disease are not irreversible.

Received: October 3, 1998

Correspondence and reprint requests to: Motohiro KIYOSAWA, MD, Department of Ophthalmology, Tokyo Medical and Dental University, School of Medicine, Yushima 1-5-45, Bunkyo-ku, Tokyo 113-8519, Japan

Table 1. Features of Takayasu Patients

No.	Age (y)	Gender	Duration of Disease (y)	Corrected		Intraocular Pressure (R/L)	Cataract	Classification Using Ophthalmoscopy (R/L)		Classification Using FAG* (R/L)	No Abnormality*	Venous Dilatation*	Retinal Bleeding*	Microaneurysm*	Arteriovenous Shunts*	Neovascularization*	Avascular Area*
				Visual Acuity (R/L)	Visual Acuity (L)			Ophthalmoscopy (R/L)	Ophthalmoscopy (L)								
1	45	F	18	0.6/0.6		12/12	-	A/A	A/A	A/A	+/+	-/-	-/-	-/-	-/-	-/-	-/-
2	50	F	22	0.3/0.9		14/12	+	A/A	A/A	A/A	+/+	-/-	-/-	-/-	-/-	-/-	-/-
3	58	F	18	0.9/1.0		12/16	-	A/A	A/A	A/A	+/+	-/-	-/-	-/-	-/-	-/-	-/-
4	62	F	19	0.4/0.4		13/12	+	A/A	A/A	A/A	+/+	-/-	-/-	-/-	-/-	-/-	-/-
5	74	F	11	0.7/0.8		13/13	+	A/A	A/A	A/A	+/+	-/-	-/-	-/-	-/-	-/-	-/-
6	36	F	19	1.5/1.5		14/14	-	B1/B1	B1/B1	B1/B1	-/-	+/+	-/-	-/-	-/-	-/-	-/-
7	38	F	20	1.2/1.2		16/16	-	B1/B1	B1/B1	B1/B1	-/-	+/+	-/-	-/-	-/-	-/-	-/-
8	42	F	25	1.5/1.5		15/13	-	B1/B1	B1/B1	B1/B1	-/-	+/+	-/-	-/-	-/-	-/-	-/-
9	46	F	16	1.0/1.0		15/16	+	B1/B1	B1/B1	B3/B1	-/-	+/+	-/-	-/-	+/+	-/-	+/+
10	49	F	20	1.2/1.0		6/8	-	B1/B1	B1/B1	B1/B1	-/-	+/+	-/-	-/-	-/-	-/-	-/-
11	54	F	20	0.5/0.6		12/14	-	B1/B1	B1/B1	B3/B1	-/-	+/+	-/-	-/-	+/+	-/-	-/-
12	68	F	32	0.7/0.8		8/10	+	B1/B1	B2/B3	B2/B3	-/-	+/+	-/-	-/-	-/-	-/-	-/-
13	32	F	1	1.5/1.5		15/15	-	B2/B2	B2/B2	B2/B2	-/-	+/+	-/-	-/-	-/-	-/-	-/-
14	65	F	18	0.01/0.8		11/15	-	B2/B2	B2/B2	B2/B2	-/-	+/+	+/+	-/-	-/-	-/-	-/-
15	73	F	18	0.3/0.3		10/14	+	B2/B2	B2/B2	B2/B2	-/-	+/+	+/+	-/-	-/-	-/-	-/-
16	56	F	26	N.L./P0.5		9/9	+	Impossible/B3	Impossible/B3	Impossible/B3	-/-	+/+	-/-	-/-	+/+	-/-	+/+

R; right; L; left; FAG; fluorescein-angiography; F; female.

*Fundus findings observed using FAG.

Therefore, it is important to determine the clinical stage of retinopathy in Takayasu disease patients before planning retinal photocoagulation or a bypass operation.¹⁰ We choose the appropriate treatment based on the clinical stage demonstrated from ophthalmoscopic and fluorescein angiographic findings. Because previous reports do not indicate which patient should have fluorescein angiography, we routinely perform it on all patients diagnosed with Takayasu disease, with or without incidence of ophthalmoscopic retinal changes. Subsequently, we compare ophthalmoscopic and fluorescein angiographic findings to determine the clinical significance of any venous dilatation observed by ophthalmoscopy.

This study's protocol was planned according to the tenets of the Declaration of Helsinki. Informed consent was obtained from each patient studied.

Materials and Methods

The diagnosis of Takayasu disease was made according to the criteria issued by the Research Project Committee for Takayasu Disease of the Japanese Ministry of Health and Welfare in 1992.¹¹ In this study, we examined 16 female patients ranging in

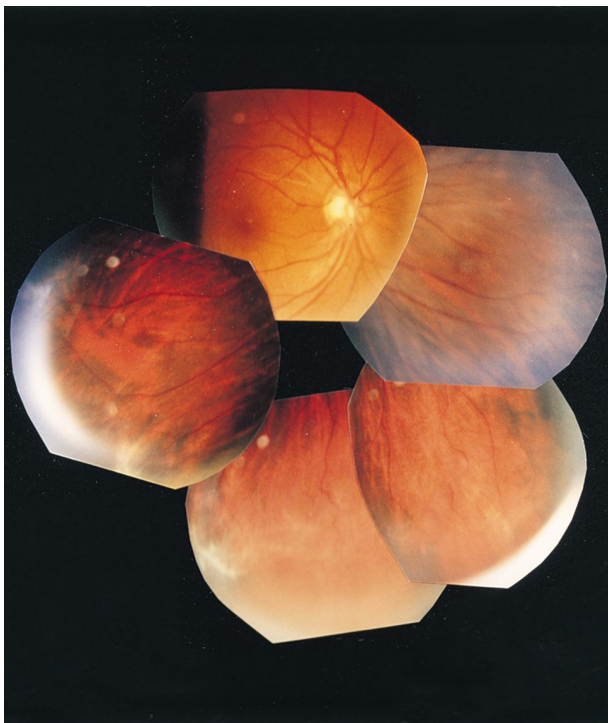

Figure 1. Right fundus of case 1. This patient with dilated and tortuous retinal vein was classified as stage B1 using ophthalmoscopy.

age from 31 to 74 years (mean = 52.9 years). The disease duration was between 1 and 32 years (mean = 19 years; Table 1).

Ophthalmological examinations included corrected visual acuity, intraocular pressure, and slit-lamp microscopy. Based on the ophthalmoscopic examination, retinal findings were recorded according to the modified Takayasu disease classification of retinal findings originally reported by Uyama.^{12,13} Patients with no abnormality were classified as stage A, and patients with some retinal abnormality were classified as stage B. Stage B patients with retinal venous dilatation only were further classified as stage B1, and those with microaneurysms, retinal bleeding, or soft exudate, in addition to retinal venous dilatation, were classified as stage B2. Patients with more progressive changes, such as arteriovenous shunts or retinal neovascularization, were

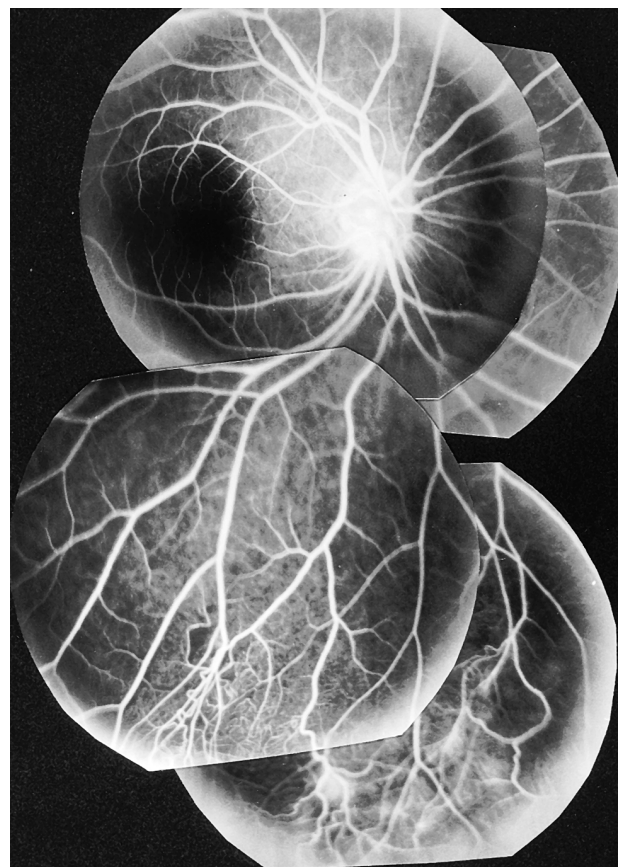


Figure 2. Fluorescein angiogram of right eye of case 1. Area of nonperfused retina, associated with arteriovenous shunts, seen in midperipheral retina, from inferonasal to inferotemporal region. Leakage of dye occurred from arteriovenous shunts. Patient's condition was reclassified as stage B3 using fluorescein angiography.

classified as stage B3. Color fundus pictures were taken to record these findings.

We also obtained fluorescein angiograms from each patient. The fundus findings were classified independently of the ophthalmoscopic findings. The fluorescein angiographic and ophthalmoscopic findings were compared for each patient.

Results

Table 1 compares the ophthalmoscopic and fluorescein angiographic findings in the 16 patients with Takayasu disease.

Ten eyes of 5 patients were classified as stage A using ophthalmoscopy. In these eyes, no additional abnormality was noted by fluorescein angiography. Ten of the 14 eyes of 7 patients were stage B1, having only a dilated retinal vein and showing no further abnormality by fluorescein angiography. However,

fluorescein angiography revealed a microaneurysm in 1 of the 14 eyes, indicating a stage B2 condition. Fluorescein angiography revealed more advanced changes, including arteriovenous shunts and avascular retinal areas in the remaining 3 eyes of the 14 eyes. In 6 eyes classified as stage B2 (3 patients), ophthalmoscopy revealed retinal bleeding in addition to venous dilatation. Fluorescein angiography showed that 4 of these eyes had no further abnormality and 2 had newly discovered microaneurysms. In both eyes classified as stage B3 (1 patient) by ophthalmoscopy, fluorescein angiography revealed retinal neovascularization and/or an avascular area.

Case Reports

Case 1. A 46-year-old woman (patient no. 9 in Table 1) presented with episodes of blurred vision lasting 10 minutes and fainting spells from the time she

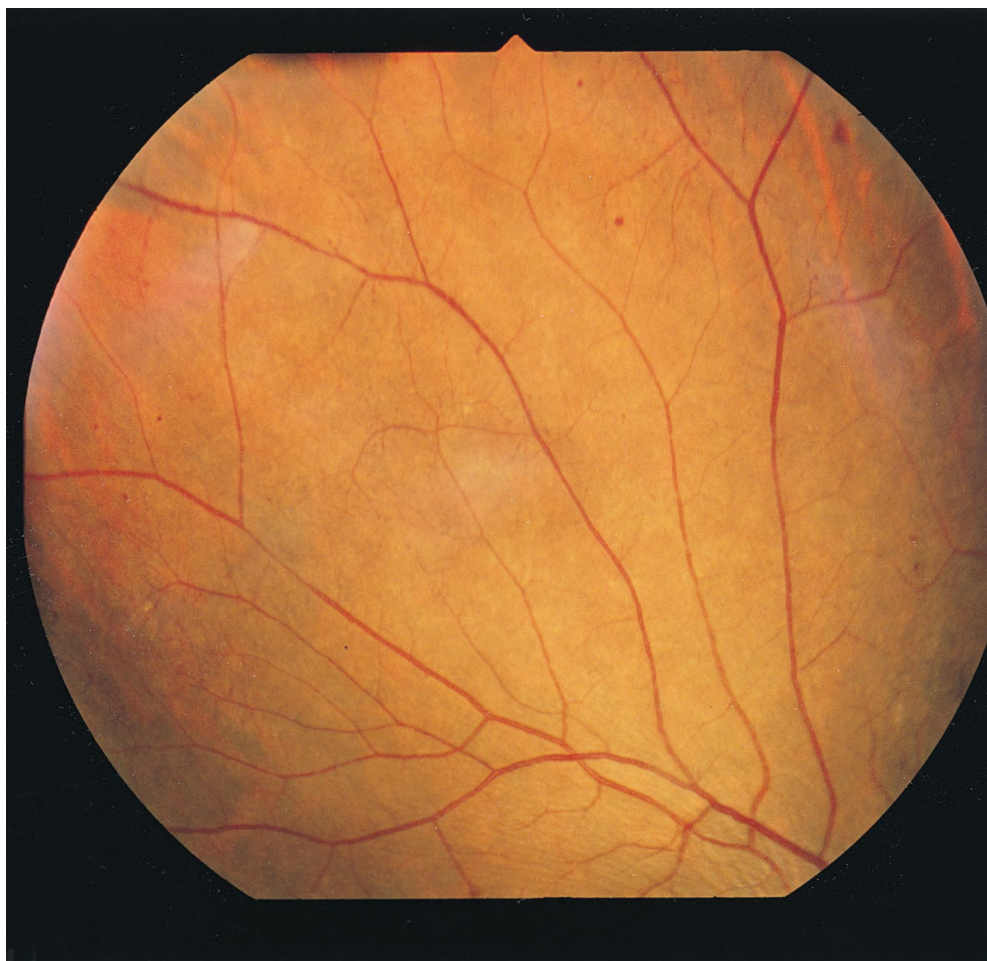


Figure 3. Right fundus of case 2. Dilatation of retinal vein and dot and blot-like bleeding at temporal peripheral retina were seen. Patient's condition was classified as stage B2 using ophthalmoscopy.

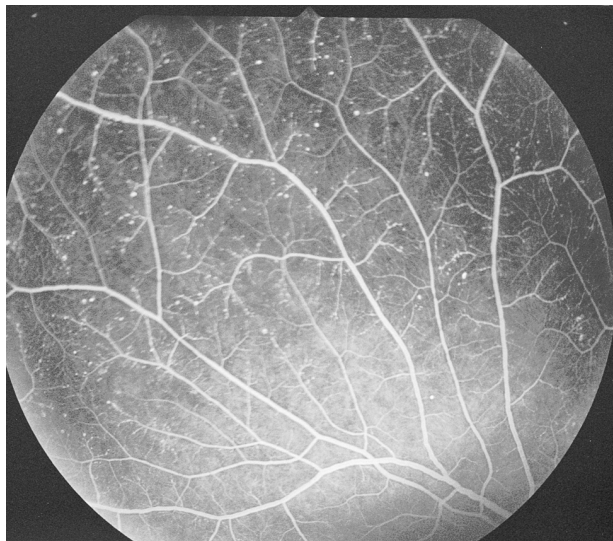


Figure 4. Fluorescein angiogram of right eye of case 2. Many microaneurysms appeared in same areas of retina shown in Figure 3.

was 22 years of age. Takayasu disease was diagnosed when she was 23 years of age. Subsequently, she developed a cerebrovascular disorder and right hemiparesis. Blood pressure could not be measured in the upper limbs; it was 260/90 mm Hg in the lower extremities. Her visual acuity in January 1994 was RE

0.9 (1.0×-1.50 D = cyl-1.00 D A30°) and LE 1.0 (n.c.). Intraocular pressure was 15 mm Hg in both eyes. The anterior segment and media were normal except for a bilateral incipient cataract. Dilated retinal veins were observed by ophthalmoscopy, and her Takayasu disease was classified as stage B1 (Figure 1). Fluorescein angiography showed areas of retinal nonperfusion associated with arteriovenous shunts in the right eye (Figure 2). Fundus grading using fluorescein angiography indicated a stage B3 case.

Case 2. A 32-year-old woman (patient no. 13 in Table 1) had noticed she was tiring easily during the previous 2 years. The diagnosis of Takayasu disease was made after a medical examination. Visual acuity was RE 0.5 (1.5×-0.50 D = cyl-0.50 D A60°) and LE 0.9 (1.5×-0.50 D = cyl-0.25 D A170°). The anterior segment and media appeared normal bilaterally. Central retinal arterial pressure was 30/20 mm Hg in the right eye and 35/20 mm Hg in the left. These were significantly low values. Dilated retinal veins and retinal bleeding existed in the nasal periphery of the right eye (Figure 3), indicating stage B2 based on ophthalmoscopic study. Fluorescein angiography revealed many additional microaneurysms (Figure 4), but the classification of the patient was not changed.

Case 3. A 56-year-old woman (patient no. 16 in Table 1) visited us in September 1997 complaining of low visual acuity in her right eye. She tired easily and

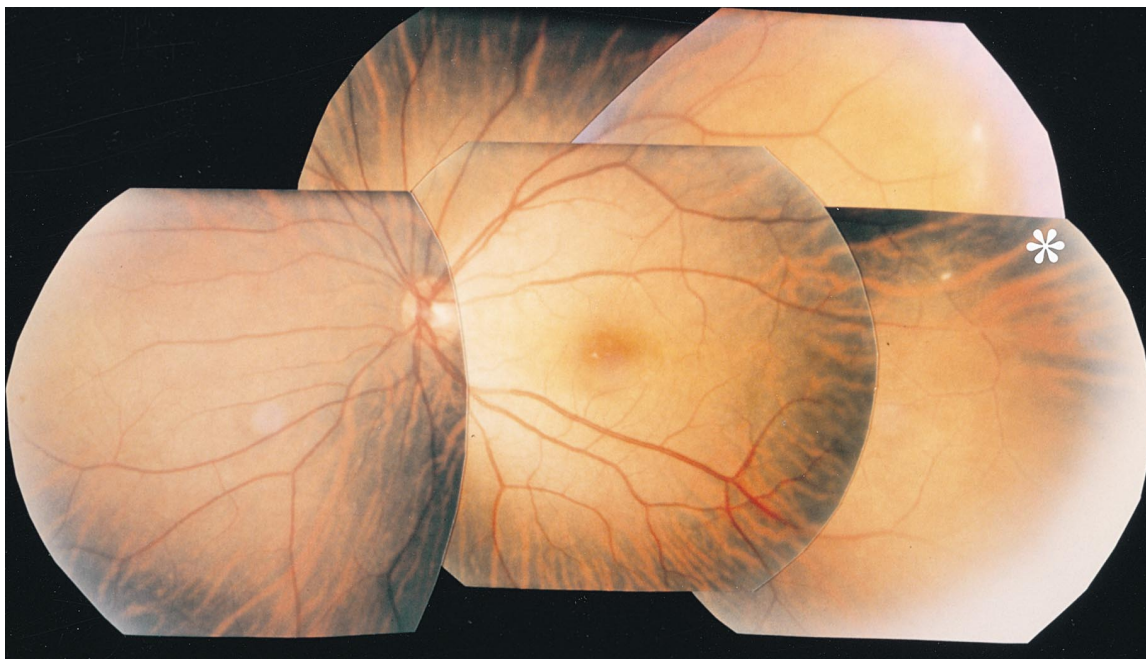


Figure 5. Left fundus in case 3. Venous dilatation and irregular diameter of retinal vein were seen. Arteriovenous shunts were found in temporal peripheral retina. (*). Patient's condition was classified as stage B3 using ophthalmoscopy.

had experienced pain in her jaw and shoulders since she was 30 years old. In addition to these episodes, she also suffered from dizziness and fainting spells. A diagnosis of Takayasu disease had been made when she lost vision in her left eye. Her visual acuity was RE no light perception, and LE 0.1 ($0.5 \times -0.50 \text{ D} = \text{cyl} -2.00 \text{ D A}180^\circ$). Total retinal detachment was detected by b-mode echography, under a mature cataract in the right eye. Except for a senile cataract, the anterior segment and media appeared normal in the left eye. Dilatation and irregularity of retinal vein diameter were observed. Arteriovenous shunts existed in the temporal periphery, and the condition of her left eye was classified as stage B3 from the ophthalmoscopic findings (Figure 5). Fluorescein angiography revealed microaneurysms in the midperipheral to peripheral area (Figure 6). A large nonperfusion area was observed in the peripheral retina. Marked fluorescein dye leakage resulting from neovascularization was observed in the temporal and nasal periphery, and slight leakage of dye close to the macula was also found. These additional retinal findings, observed with fluorescein angiography, did not alter the B3 classification determined on the basis of ophthalmoscopy.

Discussion

Importance of Fluorescein Angiography

In outpatient clinics, retinal evaluations are first done by ophthalmoscopy. Fluorescein angiography is performed only in selected cases, although its usefulness is widely accepted.⁵⁻⁸ To our knowledge, no report has yet to compare the results of ophthalmoscopy and fluorescein angiography in patients with Takayasu disease. Therefore, we studied the accuracy of determining the stage of Takayasu disease using ophthalmoscopy in comparison with fluorescein angiography. Presently, few severe complications are seen, and it is more important to detect slight changes in the retina. We modified Uyama's classification, bearing in mind the importance of retinal venous dilatation.

Using our modified classification, determination of the stage of retinal changes in Takayasu disease by ophthalmoscopy was identical to that made by fluorescein angiography in 87% of the patients in this study. Also, in 77% of patients, no additional fundus findings were detected by fluorescein angiography. The results obtained by ophthalmoscopy were, for the most part, accurate. Nevertheless, differences in the classification of the stage of retinopathy in Takayasu disease when using ophthalmoscopy

compared to using fluorescein angiography were found in 19% of stage B patients. Moreover, 33% of the patients who had additional retinal changes revealed by fluorescein angiography were stage B patients ($P < .05$, Fisher's exact test). Based on these results, we suggest that patients who exhibit retinal vein dilatation (stage B) should be examined not only by ophthalmoscopy, but also by fluorescein angiography.

Pathogenesis of Venous

Dilatation in Takayasu Disease

Uyama described the dilatation of the retinal vein in a relatively early phase of Takayasu disease,^{12,13} but it is not clear what causes the retinal vein to dilate in ocular ischemia.

Venous stasis retinopathy has been known to cause a venous dilatation similar to that seen in Takayasu disease. Chronic ocular ischemia resulted in low intraocular pressure and chronic retinal hypoxia, leading to venous dilatation accompanied by venous wall relaxation.¹⁴ In 1976, Hayreh proposed a mechanism by which venous stasis retinopathy resulted in chronic ocular ischemia.^{15,16} First, disorders in the circulation of the central retinal artery cause venous stasis in the retina. Then, changes in the artery induce the formation of venous thrombosis, leading to endothelial cell proliferation causing a venous blockage.

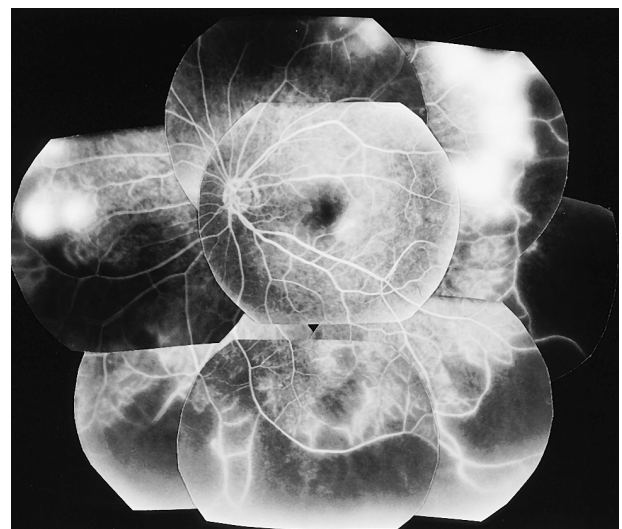


Figure 6. Fluorescein angiogram of left eye of case 3. Microaneurysms were seen from midperipheral to peripheral retina. Wide area of nonperfusion in peripheral retina and marked leakage of dye due to neovascularization in temporal and nasal peripheral retina were also observed.

Additional discussions on retinal ischemia and venous dilatation have suggested that the dilatation of retinal vessels reduces blood flow resistance, resulting in slightly reduced blood flow under low arterial pressure.¹⁷ On the other hand, it has been proposed that in the ischemic brain, the dilated cerebral vascular bed retains blood in the brain tissue longer than usual, and the oxygen extraction rate to brain tissue increases to keep the rate at almost normal levels.¹⁸ A similar mechanism could be assumed for the retinal vessels.

Some mechanisms explaining this phenomenon pharmacologically have been presented recently.¹⁹⁻²² The chronic hypoxia of retinal tissue, caused by insufficient retinal arterial circulation, could cause secretion of vasodilation factors, such as nitrogen oxide¹⁹ and endothelin (ET_B).^{20,21} Adenosine has also been implicated in dilating focal vessels, especially capillaries, with modulation controlled by the autocrine system and the adenosine A₂ receptor system.²² It is not clear which mechanism produces the venous dilatation observed in the ischemic retina in Takayasu disease, but either whole or focal retinal circulation regulation could cause venous dilatation. Further studies are needed to clarify which mechanism is responsible.

The authors thank Prof. Takashi Tokoro for his helpful advice.

References

1. Numano F, Kobayashi Y, Murayama Y, et al. Takayasu arteritis: clinical characteristics and the role of genetic factors in its pathogenesis. *Vascular Med* 1996;1:227-33.
2. Yajima M, Numano F, Park YB, Sagar S. Comparative studies of patients with Takayasu arteritis in Japan, Korea and India. *Jpn Circ J* 1994;58:9-14.
3. Sagar S, Kar S, Gupta A, Sharma BK. Ocular changes in Takayasu's arteritis in India. *Jpn J Ophthalmol* 1994;38:97-102.
4. Kiyosawa M, Baba T. Ophthalmological findings in patients with Takayasu disease. *Int J Cardiol* 1998;66(suppl.):141-7.
5. Shimizu K. Fluorescein fundus photography: part 4. Fluorescein studies of Takayasu's disease. *Nippon Ganka Gakkai Zasshi (Acta Soc Ophthalmol Jpn)* 1966;70:174-81.
6. Shimizu K. Takayasu's disease. Fluorescein angiographic study. *Jpn J Ophthalmol* 1967;11:23-36.
7. Okano T, Awane H, Inohara T, Tanaka T, Nitta A. Disorder of retinal vessels and retinal circulation in Takayasu's disease. *Nihon Ganka Kyo (Folia Ophthalmol Jpn)* 1981;32:1935-46.
8. Tanaka T, Shimizu K. Retinal arteriovenous shunts in Takayasu disease. *Ophthalmology* 1987;94:1380-8.
9. Kiyosawa M, Asano Y. A case of posterior ischemic optic neuropathy associated with pulseless disease. *Nippon Ganka Gakkai Zasshi (Acta Soc Ophthalmol Jpn)* 1982;86:2050-5.
10. Kishi S, Komatsu T, Masaika N, Sawada K. Retinal photocoagulation for a patient with Takayasu disease. *Nihon Ganka Kyo (Folia Ophthalmol Jpn)* 1997;48:619-24.
11. Committee report. Criterion of diagnosis of arteritis syndrome. A report by the Japanese Ministry of Welfare, 1992.
12. Uyama M. Takayasu disease, ophthalmological changes. *Nippon Rinsho (Jpn J Clin Med)* 1968;26:3325-31.
13. Uyama M. Takayasu disease (pulseless disease), recent concept, ophthalmological clinical features, and classification. *Ganka (Ophthalmology)* 1971;13:121-34.
14. Uyama M, Asayama K. Retinal vascular changes in Takayasu's disease (pulseless disease), occurrence and evolution of the lesion. In: Delaey JJ, ed. *Documenta Ophthalmologica Proceeding Series, Vol. 9. International Symposium on Fluorescein Angiography*. Hague: Junk Publishers, 1976:549-54.
15. Hayreh SS. So-called "central retinal vein occlusion" 1. Pathogenesis, terminology, clinical features. *Ophthalmologica* 1976;172:1-13.
16. Hayreh SS. So-called "central retinal vein occlusion" 2. Venous stasis retinopathy. *Ophthalmologica* 1976;172:14-37.
17. Rodney AS, George AT. *Blood and cardiovascular physiology. Medical physiology*. Boston: Little, Brown, 1995:309-10.
18. Baron JC, Bousser MG, Comar D, Soussaline F, Castaigne P. Noninvasive tomographic study of cerebral blood flow and oxygen metabolism in vivo. Potentials, limitations, and clinical applications in cerebral ischemic disorders. *Eur Neurol* 1981;20:273-84.
19. Palmer RM, Ashton DS, Moncada S. Vascular endothelial cells synthesize nitric oxide from L-arginine. *Nature* 1988;333:664-6.
20. Meyer P, Flammer J, Luscher FT. Endothelium-dependent regulation of ophthalmic microcirculation in the perfused porcine eye: role of nitric oxide and endothelins. *Invest Ophthalmol Vis Sci* 1993;34:3614-21.
21. Takei K, Sato T, Nonoyama T. Analysis of vasocontractile responses to endothelin-1 in rabbit retinal vessels using an ET_A receptor antagonist and ET_B receptor agonist. *Life Sci* 1993;53:111-5.
22. Matsugi T, Chen Q, Anderson DR. Adenosine-induced relaxation of cultured bovine retinal pericytes. *Invest Ophthalmol Vis Sci* 1997;38:2695-701.