



Do Microwave Ovens Affect Eyes?

Serap S. İnalöz,* Ahmet Aksünger,† İbrahim Sari,‡
Süleyman Daşdağ§ and Engin Deveci*

Departments of *Histology and Embryology, †Ophthalmology, ‡Pathology, §Biophysics,
Faculty of Medicine, University of Dicle, 21280-Diyarbakir, Turkey

Abstract: The cataractogenic effects of the microwave oven on rat eyes were investigated histologically. Twenty-one adult Wistar-Albino rats (2–2.5 months old) were divided into three groups (n = 7): a control group (sham-exposed) and two experimental groups. The experimental rats were confined in special cages and placed next to the closed door of a microwave oven. The first experimental group was given 15 minutes of daily exposure and the second, 30 minutes, for 1 month. Biomicroscopic examination detected no pathological damage to the lens in the experimental rats. Histologically, there was a lens of single-layered epithelium in the control group. In the first experimental group, there was slight pleomorphism in the superficial epithelial cell contours and vacuolizations in the lens fibers; the second experimental group, had pronounced pleomorphism and pyknosis of the nuclei in the superficial epithelium. Some of the superficial epithelial cells had disappeared and were histologically observed as acellular areas. Single-layered epithelium became disorganized and formed multilayered epithelial groups in the superficial epithelium. Vacuolization was more prominent in this group. Personal exposure from microwave ovens is generally minimal because of the rapid decrease in power density with distance. Microwave oven users do not normally stand as close to the oven as the rats in our study were placed; therefore, it is difficult to suggest that microwave ovens always have cataractogenic effects on human eyes. **Jpn J Ophthalmol 1997;41:240–243** © 1997 Japanese Ophthalmological Society

Key Words: Cataract, histopathology, microwave oven, non-ionizing radiation, rat lens.

Introduction

Urban radiation consists primarily of radio and television transmissions^{1,2}; however, microwaves are increasingly being used in household ovens, radar, satellite communications, and insect control. Microwave radiation (wavelength range: 700–2200 cm) is at the low frequency end of the electromagnetic spectrum. Frequency ranges considered here are 300 kHz to 300 MHz for radio frequency radiant energies (RF) and 300 MHz to 300 GHz for microwaves (MW).

The increase in human exposure to environmental sources of electromagnetic radiation has become a matter of serious concern focused primarily on the carcinogenic effects of radiant energy. However, the evidence increasingly suggests that microwave and ionizing radiation are cataractogenic.^{1,3} The catarac-

togenic effect of microwave radiation has been well documented in laboratory animals.^{4–8} Human case reports and epidemiological studies are more controversial and much less conclusive than the experimental studies above.⁹ It is believed that microwave-induced lens pathology is the result of an average temperature elevation that occurs as a function of the power absorbed by the lens.¹⁰ We investigated, histologically, the cataractogenic effect of microwave ovens on rat eyes.

Materials and Methods

Twenty-one adult Wistar-Albino rats (2–2.5 months old; 200–220 g), obtained from the Medical Science Application and Research Center of Dicle University, were caged and fed standard pellet food during the study. All animals were handled in accordance with the ARVO resolution on the care of animals in research. They were separated into three groups of seven rats: a control group, which was sham-exposed,

Received: February 15, 1996

Address correspondence and reprint requests to: Serap S. İNALÖZ, PhD, Departments of Histology and Embryology, Dicle University Medical Faculty, Diyarbakir, Turkey

Table 1. Histopathological Findings in Experimental Rats

Findings	Group	Rats (n = 7)						
		1	2	3	4	5	6	7
Vacuolization	1	-	+	+	+	+	-	+
	2	+	+	+	+	+	+	+
Pleomorphism	1	-	+	+	+	+	-	+
	2	+	+	+	+	+	+	+
Acellular areas	1	-	-	-	-	-	-	-
	2	-	+	+	-	+	+	+
Multilayered epithelium	1	-	-	-	-	-	-	-
	2	+	+	+	-	+	+	+
Pyknosis of nuclei	1	-	-	-	-	-	-	-
	2	-	+	+	-	+	+	+
Mean increase in rectal temperature (°C)	1	0.5	0.7	0.7	0.7	0.7	0.6	0.7
	2	0.9	1.1	1.0	0.9	1.0	1.1	1.1

and experimental groups 1 and 2. The experimental rat groups were confined in plexiglass cages (40 × 15 × 17 cm) and placed next to the closed door of a microwave oven (full power: 550 W, imperial V-8505T).

The average cooking time in microwave ovens usually varies between 15 and 30 minutes. For this reason, the first group of rats was exposed to the microwave oven at full power for 15 minutes daily, and the second group for 30 minutes daily, for 1 month. Leakage from the microwave oven was measured with a Detector Card (Microwave oven radiation leakage indicator, Enzone, USA) after each session. The pupils of the experimental rats were dilated with a solution of 10% phenylephrine hydrochloride and 1% cyclopentolate hydrochloride, and examined daily after exposure by an ophthalmologist using a biomicroscope. Rectal temperatures of the rats were recorded daily before and after each exposure.

At the end of the month, all rats were sacrificed and their eyes enucleated for histopathological examination. The enucleated eyes were bisected horizontally and fixed in a solution of 10% formaldehyde. The tissues were then embedded in paraffin wax, sectioned, and finally stained with hematoxylin-eosin. Histological assessments were done with a light microscope.

Results

All rats in the plexiglass cages moved towards the microwave oven during the first 10 minutes of each exposure. The mean rectal temperature of the first group increased by 0.7°C; of the second group, by 1.0°C (Table 1). Specific absorption rates (SARs) were 3.9 W/kg in group 1 and 1.9 W/kg in group 2.




Figure 1. Control group: Normal lens with single layered epithelium (ep) and lens fiber nuclei (n). (Hemotoxylin and eosin, original magnification × 200.)

Leakage from the microwave oven was within safety limits. Biomicroscopic examination detected no pathological damage to the lens.

A histologically normal lens of single-layered epithelium was found in the control group. A bow arrangement of the lens fiber nuclei and normal arrangements of the lens fibers were observed; there was no vacuolization in the lens fibers (Figure 1).

In the first experimental group, slight pleomorphism was observed in the epithelial cell contour with some vacuolizations in the outer lens fibers (Figure 2). Pleomorphism and vacuolization were noted in five of the seven rats. In the second experimental group, some of the superficial epithelial cells disappeared and were histologically observed as acellular areas in the lens (Figure 3). In the local fields of the superficial epithelium, single-layered epithelium became disorganized, forming multilayered epithelial groups. Pronounced pleomorphism and pyknosis of the nuclei in the superficial epithelium were also observed in this group (Figure 3). Pleomorphism and vacuolization were noted in all rats; acellular areas and pyknotic nuclei in the epithelial cells were noted in five of the seven animals; multilayered epithelial groups were seen in six of the seven. Histological findings and rates are shown in Tables 1 and 2.

Discussion

Many cases of cataract attributed to microwave radiation have been reported in the literature. A number of investigators have reported on the location, course, and appearance of microwave-induced cataracts. Preclinical signs of microwave radiation con-




Figure 2. First experimental group: Vacuolization of the outer lens fibers (arrows). (Hemotoxylin and eosin, original magnification $\times 200$.)

sist of roughening, thickening, and minute areas of opacification in the posterior capsule of the lens.¹¹ Both an anterior subcapsular defect resembling a lesion that might be seen after exposure to infrared radiation, and/or a posterior subcapsular opacity resembling a cataract causing by ionizing radiation, have been observed.^{1,4,12} The anterior defects developed within 24 hours and the posterior defects within days.^{4,12} The early defects have been described as small granules or vesicles, small holes, or small masses.^{6,12} In some cases, these lesions progressed to globular degeneration and even to complete opacification.⁶

Microwaves most commonly cause anterior and/or posterior subcapsular lenticular opacities in experimental animals, as described in epidemiological

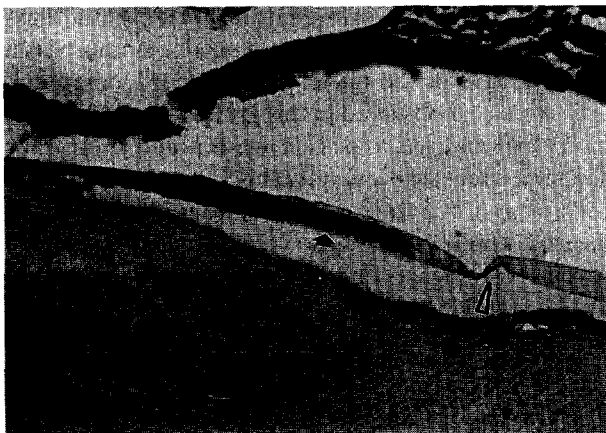

Figure 3. Second experimental group: Multilayered epithelial group (filled arrow) are attached to acellular areas (hollow arrow) in the superficial epithelium. (Hemotoxylin and eosin, original magnification $\times 200$.)

Table 2. Histopathological Findings in Experimental Groups

	Group	Positive Findings	
		(n = 7)	%
Vacuolization	1	5	71.43
	2	7	100.00
Pleomorphism	1	5	71.43
	2	7	100.00
Acellular areas	1	0	—
	2	5	71.43
Multilayered epithelium	1	0	—
	2	6	85.71
Pyknosis of nuclei	1	0	—
	2	5	71.43

studies and case reports of human subjects. In animals, acute changes in the conjunctiva and iris have been reported for daily MW exposure at power densities of 3, 4, or 5 kW/m² for 15 minutes.¹¹ In our study, biomicroscopic examination showed no pathology on the anterior segment of the eyes. Histologically, enlargement of equatorial epithelial cells, vacuolization of the outer lens fibers, and pyknosis of nuclei were noted in the superficial epithelium.¹³ We observed similar histological findings in the experimental rats (Figures 2,3). In the first group, slight pleomorphism was observed in the cell contour of the superficial epithelium and vacuolizations were noticed in the local fields of the outer lens fibers (Figure 2; Tables 1,2). In the second group, pronounced pleomorphism and pyknosis of the nuclei were noticed in the superficial epithelium. Some of the superficial epithelial cells disappeared and were histologically observed as acellular areas in the lens. Single-layered epithelium became disorganized and formed multilayered epithelial groups in the superficial epithelium. Vacuolization was more prominent in this group (Figure 3; Tables 1,2).

Microwaves act on living tissue in both thermal and nonthermal ways.¹⁴ The formation of cataracts is directly related to the power of the microwave and the duration of exposure. Increasing the dose of ionizing radiation causes an increase in the opacification of the lens; this occurs more rapidly with increased dosages. A single acute exposure of the eye to high-intensity radiofrequency radiation can cause cataracts and retinal changes in experimental animals if it is applied for sufficient time.² Although we cannot predict a threshold for microwave-induced cataractogenesis, the most likely frequencies appear to be in the range of 1–10 GHz. After 25 years of experimental studies of MW effects on the ocular lens, the principal conclusions are¹¹: (1) acute thermal insult from

high-intensity MW fields is cataractogenic in animals if intraocular temperatures reach 45–55°C; (2) the MW exposure threshold is between 1 and 1.5 kW/m² applied for 60–100 minutes; (3) there is the possibility of a cumulative effect on the lens from repeated “subthreshold” MW exposures. No cumulative rise in temperature can occur if the intervals between exposures exceed the time required for the tissue to return to normal temperature.

The expansion of microwave oven use presents a possible public health hazard if appropriate safety devices are absent. Although the energy is enclosed and emission of radiation is not intended in microwave ovens, there is usually some small amount of leakage. It is known that MW radiation is not hazardous to health if the total amount of leakage does not exceed 1 mW/cm² at 5 cm distance, and the total amount of microwave radiation does not exceed 5 mW/cm² in usage time. In our study, leakage from the microwave oven was found to be within normal safety limits.

Personal exposure to radiation from microwave ovens is minimal because of the rapid decrease in power density with distance. For instance, with a leakage of 50 W/m² at 5 cm from the oven, power density is less than 15 W/m² at 0.3 m and about 0.1 W/m² at 1 m.^{2,11} Microwave oven users are not usually exposed to the same radiation and proximity as in our experimental conditions; therefore, we cannot infer that these ovens will have similar cataractogenic effects on the human eye.

References

1. Lipman RM, Tripathi BJ, Tripathi RC. Cataracts induced by microwave and ionizing radiation. *Surv Ophthalmol* 1988; 33(3):200–10.
2. Elder JA, Czernski PA, Stuchly MA, Mild KH, Sheppard AR. Radiofrequency radiation. In: Suess MJ, Benwell-Morison DA, eds. *Non-ionizing radiation protection*. European Series No. 25. 2nd ed. Copenhagen: WHO Regional Publications, 1989:117–73.
3. Zaret MM. Cataracts following use of microwave oven. *NY State J Med* 1974;74(11):2032–48.
4. Daily L, Wakim KG, Herrick JF, Parkhill EM, Benedict WL. The effects of microwave diathermy on the eye: An experimental study. *Am J Ophthalmol* 1950;33:1241–54.
5. Hirsh S, Appleton B, Fine BS, Brown PV. Effects of repeated microwave irradiations to the albino rabbit eye. *Invest Ophthalmol Vis Sci* 1977;16(4):315–9.
6. Stewart-DeHaan PJ, Creighton MO, Larsen LE, Jacobi JH, Ross WM, Sanwal M, et al. In vitro studies of microwave induced cataract: Separation of field and heating effects. *Exp Eye Res* 1983;36(1):75–90.
7. Van Ummersen CA, Cogan FC. Effect of microwave radiation on the lens epithelium in the rabbit eye. *Arch Ophthalmol* 1976;94(5):828–34.
8. Kramar P, Harris C, Emery AF, Guy AW. Acute microwave irradiation and cataract formation in rabbits and monkeys. *J Microwave Power* 1978;13(3):239–49.
9. LaRoche LP, Zaret MM, Braun AF. An operational safety program for ophthalmic hazards of microwave. *Arch Environ Health* 1970;20(3):350–5.
10. Cleary SF, Pasternack BS. Lenticular changes in microwave workers: A statistical study. *Arch Environ Health* 1966; 12(1):23–9.
11. Michaelson SM. Microwave and radiofrequency radiation. In: Suess MJ, ed. *Non-ionizing radiation protection*. European Series No. 10. Copenhagen: WHO Regional Publications, 1982:97–174.
12. Carpenter RL, Van Ummersen CA. The action of microwave radiation on the eye. *J Microwave Power* 1968;3:3–19.
13. Stewart-DeHaan PJ, Creighton MO, Larsen LE, Jacobi JH, Ross WM, Sanwal M, et al. In vitro studies of microwave-induced cataract: Reciprocity between exposure duration and dose rat for pulsed microwaves. *Exp Eye Res* 1985;40(1):1–13.
14. Cutz A. Effects of microwave radiation on the eye: The occupational health perspective. *Lens Eye Toxic Res* 1989;6(1–2): 379–86.

This article is being published without the benefit of the authors' review of the proof, which was not available at press time.