

# Evaluation of Fungal DNA Sequence Using Polymerase Chain Reaction in Infection-free Vitreous Humor

Kiyofumi Mochizuki,\* Hirofumi Matsushita,\*  
Yuji Hiramatsu,\* Kazuo Yanagida,\* Gohzo Ueda† and Kohzo Hashimoto†

\*Yanagida Eye Clinic, 9-1 Mariko-serigaya, Shizuoka 421-0103,  
Japan; †Toyobo Gene Analysis, 10-24 Toyo-cho, Tsuruga 914-0047, Japan

**Abstract:** We evaluated the vitreous bodies from 14 clinically nonfungal infectious eyes to establish a baseline for the presence of a fungal genome using polymerase chain reaction (PCR). The vitreous samples were all PCR negative, except for one eye with chronic uveitis. Blood samples examined were all PCR negative. We concluded that fungal DNA sequences could not be amplified in vitreous specimens obtained from patients with clinically diagnosed proliferative diabetic retinopathy, macular hole, or epiretinal membrane. **Jpn J Ophthalmol 1998;42:213–217** © 1998 Japanese Ophthalmological Society

**Key Words:** Fungal infection, polymerase chain reaction, vitrectomy, vitreous humor.

## Introduction

Opportunistic intraocular infections have become increasingly frequent in immunocompromised patients. The variety of causative agents is expanding; for example, herpesviruses, *Toxoplasma gondii*, and fungal infection.<sup>1</sup> In most cases intraocular inflammation progresses rapidly in association with a poor visual prognosis. Therefore, an accurate diagnosis of the infection and specific surgical and/or antimicrobial therapy is needed. Conventional culture methods for detecting the causative agent are difficult and time consuming. Serologic laboratory examination has been used for early diagnosis. These methods, however, typically lack adequate sensitivity or specificity because the results are often negative in the early clinical course.<sup>2,3</sup> Recently, a polymerase chain reaction (PCR) method, which is a rapid and sensitive technique for detecting the DNA of microorganisms, was developed.<sup>4–9</sup> Polymerase chain reaction has already been used to detect various organisms causing ocular infection. For fungal infection, a species-specific PCR-diagnostic method has been ap-

plied to detect *Candida albicans*,<sup>7</sup> *Aspergillus fumigatus*,<sup>8</sup> *Pneumocystis carinii*,<sup>9</sup> and others. The development of a PCR method that can identify a broad variety of medically important fungi is needed because the incidence of fungal infection associated with uncommon fungi is increasing.<sup>10,11</sup> Makimura et al<sup>12</sup> reported that a new PCR primer system has been developed that is able to detect a wide range of medically important fungi. The purpose of this study was to determine whether infection-free vitreous humor contains fungal DNA by examining vitreous specimens obtained from noninfectious vitrectomy cases with the PCR method. We also examined the vitreous specimens from ocular inflammatory diseases using the same method.

## Patients and Methods

Vitreous specimens were obtained from 14 eyes of 14 patients (male:female = 8:6; mean age, 59.1 years; age range, 28–75 years) during a period between June and November 1996. In 11 patients without intraocular inflammation, clinical diagnoses were proliferative diabetic retinopathy (n = 5), macular hole (n = 4), and epiretinal membrane (n = 2). In three patients with intraocular inflammation, clinical diagnoses were retinal detachment with atopic dermatitis (n = 1), acute retinal necrosis (n = 1) and chronic uveitis with unknown etiology (n = 1). Blood sam-

Received: September 5, 1997

Address correspondence to: Kiyofumi MOCHIZUKI, MD, Magarikane Eye Clinic, 5-4-63 Magarikane, Shizuoka 422-8006, Japan

Address reprint requests to: Kazuo YANAGIDA, MD, Yanagida Eye Clinic, 9-1 Mariko-serigaya, Shizuoka 421-0103, Japan

ples were also drawn at the same time. All samples were stored at  $-80^{\circ}\text{C}$  until assayed. The vitreous humor and blood samples were prepared according to Buchman et al<sup>7</sup> and PCR was performed for target fungal DNAs.

### *Polymerase Chain Reaction*

The PCR primers of the medically important fungi had the following sequences: 5'-ACTTTCGATGGTAGGATAG-3' and 5'-TGATCGTCTTCGATCCCTA-3' (B2F and B4R, respectively). The primers were expected to amplify a fragment of 687-bp within the 18S-rDNA. Each PCR assay contained 10  $\mu\text{L}$  of  $10 \times$  reaction buffer (600 mM Tris-HCl [pH 8.5], 150 mM  $[\text{NH}_4]_2\text{SO}_4$ , 15 mM  $\text{MgCl}_2$ ), 100  $\mu\text{M}$  of each dATP, dCTP, dGTP, and dTTP, 2.5 U of Taq polymerase, 30 pmol of each primer, and DNA template solution. The volume was brought up to 100  $\mu\text{L}$  with distilled water. Each mixture was heated to  $94^{\circ}\text{C}$  for 5 minutes to denature the DNA. Thirty amplification cycles were then performed. Each cycle consisted of 1 minute at  $94^{\circ}\text{C}$  for denaturation, 2 minutes at  $55^{\circ}\text{C}$  to anneal the primers, and 3 minutes at  $72^{\circ}\text{C}$  for extension. Thermal cycles were terminated by polymerization at  $72^{\circ}\text{C}$  for 10 minutes.

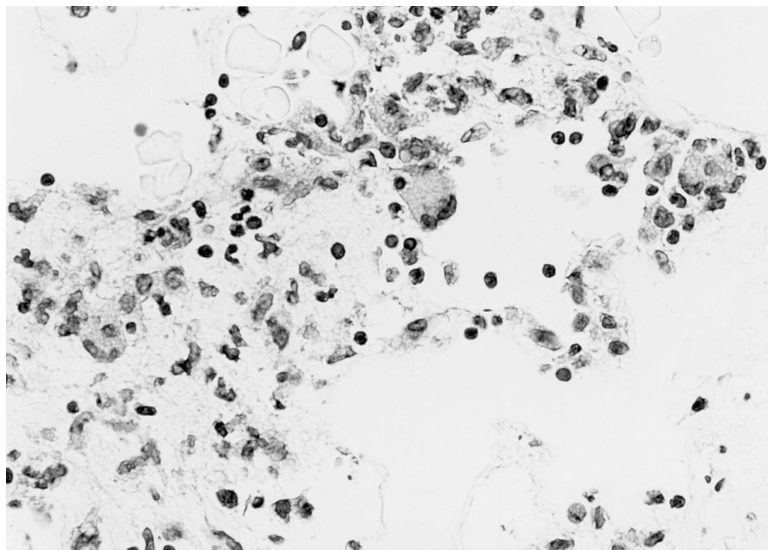
To examine the specificity of this system, the samples of genomic DNA extracted from the organisms were tested to see whether the primer pair amplified the same length of DNA products; 10 ng of template DNA was used per reaction and Southern blot analysis was used for confirmation of the results.

A portion of the PCR product (5–10  $\mu\text{L}$ ) was elec-

trophoresed in agarose gel and stained with ethidium bromide. Photographs were taken using an ultraviolet light transilluminator.

### *Case Report*

A healthy 68-year-old woman with no prior history of systemic disease complained of decreased vision in her right eye in September 1994. On examination in our eye clinic on October 25, 1994, corrected visual acuity was 0.7 in the right eye and 1.0 in the left; intraocular pressure was 24 mm Hg in the right eye and 19 mm Hg in the left. Slit-lamp examination revealed mild anterior chamber inflammation without keratic precipitates or nodules. The fundus of the right eye revealed a normal optic disc, peripheral retinal vasculitis, and vitreous opacities. The left eye was completely normal. We treated the patient with a topical corticosteroid and a topical antiglaucoma drug, suspecting uveitis with secondary glaucoma. The serum angiotensin-converting enzyme level was elevated (27.3 IU/L [normal, 8.3–21.4 IU/L]). Serum albumin was decreased (55.3% [normal, 61.0–73.0%]). Serum  $\alpha_2$ -globulin and  $\gamma$ -globulin were increased (9.3% [normal, 4.2–8.6%] and 22.5% [normal, 10.8–20.5%], respectively). Another workup in search for uveitis was negative, in particular serology for syphilis, toxoplasmosis, rheumatoid factors, direct Coombs test, and C-reactive protein. Additional laboratory studies included a normal chest x-ray. Echography showed the presence of vitreous opacity without retinal detachment. We performed diagnostic and therapeutic vitrectomy on October 17, 1995 because of decreased visual acuity and increased vit-



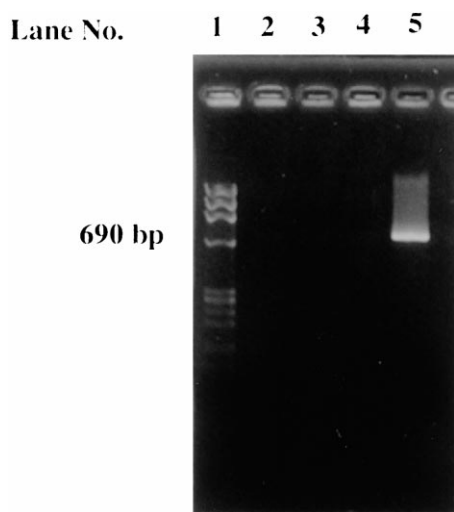
**Figure 1.** Infiltration of lymphocytes with giant cells (hematoxylin and eosin, original magnification  $\times 400$ ).

**Table 1.** Summary of Cases

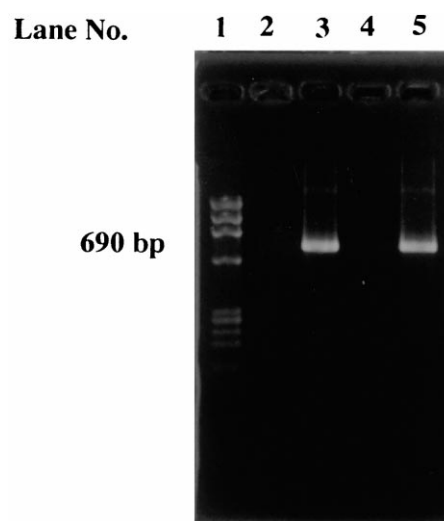
Case	Age (years)	Sex	Clinical Diagnosis	PCR	
				Blood	Vitreous
1	61	Female	Proliferative diabetic retinopathy	—	—
2	75	Male	Proliferative diabetic retinopathy	—	—
3	64	Female	Epiretinal membrane	—	—
4	59	Male	Proliferative diabetic retinopathy	—	—
5	59	Female	Macular hole	—	—
6	55	Male	Proliferative diabetic retinopathy	—	—
7	66	Female	Macular hole	—	—
8	44	Male	Proliferative diabetic retinopathy	—	—
9	28	Male	Retinal detachment with atopic dermatitis	—	—
10	68	Female	Chronic uveitis	—	+
11	60	Female	Epiretinal membrane	—	—
12	57	Male	Acute retinal necrosis	—	—
13	64	Male	Macular hole	—	—
14	67	Male	Macular hole	—	—

reous opacities in her right eye. Postoperatively, her right visual acuity improved to 1.2 with an intraocular pressure of 12 mm Hg. On September 19, 1996, the patient underwent diagnostic and therapeutic vitrectomy in her left eye because of the development of vitreous opacity and decreased visual acuity. A vitreous specimen was collected during the vitrectomy and was divided into two parts. One was used

for histopathologic examination and the other was preserved at  $-80^{\circ}\text{C}$  until PCR analysis. The vitreous specimen showed mainly infiltration of lymphocytes with giant cells (Figure 1). We did not perform immunohistopathologic examinations. Three months later, the patient had a left visual acuity of 1.2 with an intraocular pressure of 13 mm Hg. No retinal detachment occurred. The samples of ocular surface and



**Figure 2.** Agarose gel (2%) electrophoresis of polymerase chain reaction (PCR) products for fungi. Lane 1:  $\phi \times 174/HaeIII$  as size reference; lane 2: the PCR products from the blood of case 12 with acute retinal necrosis was not distinguishable.; lane 3: the PCR products from the vitreous humor of same case was not also distinguishable.; lane 4: negative control (human blood without fungus).; lane 5: PCR positive control (human blood supplemented with the intact cells of *Candida albicans*).



**Figure 3.** Agarose gel (2%) electrophoresis of PCR products for fungi. Lane 1:  $\phi \times 174/HaeIII$  as size reference; lane 2: the PCR products from the blood of case 10 with chronic uveitis was not distinguishable.; lane 3: band of 690-bp in length from vitreous humor of case 10.; lane 4: negative control (human blood without fungus).; lane 5: positive control (human blood supplemented with the intact cells of *Candida albicans*).

vitreous humor were not inoculated on chocolate agar, blood agar, and Sabouraud's media. We did not perform electroretinography prior to vitrectomy.

## Results

A summary of the PCR is given in Table 1. All the vitreous samples were PCR negative (Figure 2) except for one sample from an eye with chronic uveitis (Figure 3). Blood samples examined were all PCR negative.

## Discussion

The present study used a new PCR primer system using a primer-pair constructed of conserved DNA sequences of 18S-rRNA genes to detect a wide range of medically important fungi, including *Candida* spp., *Hansenula* spp., *Saccharomyces cerevisiae*, *Cryptococcus neoformans*, *Trichosporon beigelii*, *Malassezia furfur*, *Pneumocystis carinii*, *Aspergillus* spp., and *Penicillium* spp.<sup>12</sup> The PCR with the primer-pair B2F and B4R, was able to detect 1 pg of *Candida albicans* genomic DNA with ethidium bromide staining.<sup>12</sup> Serodiagnostic tests, such as Cand-Tec, Pastorex *Aspergillus*, and Fungitec G test, were less sensitive on the tested samples than the PCR technique.<sup>12</sup>

We performed a vitrectomy in 14 cases with clinically nonfungal infection and determined whether the vitreous humor contained fungal DNA by examining vitreous specimens with the PCR method. We found that fungal DNA sequences could not be amplified in vitreous specimens obtained from patients with clinically diagnosed proliferative diabetic retinopathy, macular hole, epiretinal membrane, retinal detachment, or acute retinal necrosis. There is evidence in this study that normal vitreous humor lacks fungal DNA, however, larger numbers of infection-free vitreous samples are required to verify the preliminary findings.

In three patients with intraocular inflammation, the vitreous sample of the patient with chronic uveitis was positive only for amplified fungal DNA. The patient had no history of ocular and systemic fungal infection and no signs of current infection in spite of detection of fungal DNA sequence. Giant cells occur in sarcoidosis, tuberculosis, toxoplasmosis, sympathetic uveitis, histoplasmosis, and other fungal infections.<sup>13</sup> In the patient with chronic uveitis, we found giant cells in the vitreous specimens (Figure 1), however, we did not perform any conventional microbiological analysis and immunohistopathologic exami-

nations. Further evaluation may be required and a greater number of vitreous humor samples of the patients with chronic uveitis will have to be analyzed by PCR and conventional microbiological methods.

Specific identification of the fungus will be needed to make a definite diagnosis. The primers provide a useful starting point for the detection of fungal DNA. Cloning and sequencing of the 18S-rDNA PCR products from the positive case might permit identification of the pathogen involved.<sup>14</sup>

It is unclear why PCR would amplify fungal DNA on the putatively fungal infection-free vitreous specimen. We treated the patient with a topical corticosteroid. This sample might be contaminated during the surgery at the time of vitreous sampling because long-term steroid therapy might alter the conjunctival flora, allowing fungal overgrowth. The false-positive result might be due to breakdown of the blood-ocular barrier, however the blood samples of the patient were PCR negative.

Takahashi et al<sup>15</sup> first reported that fungal species were detectable in vitreous specimens from patients with clinically diagnosed endogenous fungal endophthalmitis using the same primers, in spite of failing to confirm the presence of fungi using conventional techniques. The PCR seems to have significant advantages over traditional methods of identifying fungal organisms. Further studied on vitreous and blood samples from the immunocompromised patients will be needed to confirm the usefulness of the PCR, comparing with conventional techniques. In the future, the PCR method may allow accurate identification of the causative fungi and be useful for early diagnosis and treatment in a number of cases.

## References

1. Park KL, Smith RE, Rao NA. Ocular manifestation of AIDS. *Curr Opin Ophthalmol* 1995;6:82-7.
2. Boer JH, Luyendijk L, Rothova A, et al. Detection of intraocular antibody production to herpesviruses in acute retinal necrosis syndrome. *Am J Ophthalmol* 1994;117:201-10.
3. Bernard EM, Christiansen KJ, Tsang S-F, Kiehn TE, Armstrong D. Rate of arabinitol production by pathogenic yeast species. *J Clin Microbiol* 1981;14:189-94.
4. Fox GM, Crouse CA, Chuang EL, et al. Detection of herpesvirus DNA in vitreous and aqueous specimens by the polymerase chain reaction. *Arch Ophthalmol* 1991;109:266-71.
5. Boer JH, Verhagen C, Bruinenberg M, et al. Serologic and polymerase chain reaction analysis of intraocular fluids in the diagnosis of infectious uveitis. *Am J Ophthalmol* 1996;121:650-8.
6. Adleberg JM, Wittwer C. Use of the polymerase chain reaction in the diagnosis of ocular disease. *Curr Opin Ophthalmol* 1995;3:80-5.
7. Buchman TG, Rossier M, Merz WG, Charache P. Detection

- of surgical pathogens by in vitro DNA amplification. Part I. Rapid identification of *Candida albicans* by in vitro amplification of a fungus-specific gene. *Surgery* 1990;108:338-47.
8. Tang CM, Holden DW, Aufauvre-Brown A, Cohen J. The detection of *Aspergillus* spp. by the polymerase chain reaction and its evaluation in bronchoalveolar lavage fluid. *Am Rev Respir Dis* 1993;148:1313-7.
  9. Lipschik GY, Gill VJ, Lundgren JD, et al. Improved diagnosis of *Pneumocystis carinii* infection by polymerase chain reaction on induced sputum and blood. *Lancet* 1992;340:203-6.
  10. Kurosawa A, Pollock SC, Collins MP, Kraff CR, Tso MO. *Sporothrix schenckii* endophthalmitis in a patient with human immunodeficiency virus infection. *Arch Ophthalmol* 1988; 106:376-80.
  11. Glasgow BJ, Engstrom Jr RE, Holland GN, Kreiger AE, Wool MG. Bilateral endogenous *Fusarium* endophthalmitis associated with acquired immunodeficiency syndrome. *Arch Ophthalmol* 1996;114:873-7.
  12. Makimura K, Murayama SY, Yamaguchi H. Detection of a wide range of medically important fungi by the polymerase chain reaction. *J Med Microbiol* 1994;40:358-64.
  13. Yanoff MEM, Fine BS. *Ocular pathology*. Philadelphia: Harper & Row, 1975.
  14. Perara PD, Murayama SY, Makimura K, Yamaguchi H. Identification of fungal species from PCR-amplified products. *Jpn J Med Mycol* 1994;35 Suppl 1:128.
  15. Takahashi E, Mochizuki K, Ichien K, Tomatsu A, Jikihara S. Detection of fungal species in vitreous and aqueous specimens by the polymerase chain reaction in patients with endogenous fungal endophthalmitis. *Rinsho Ganka (Jpn J Clin Ophthalmol)*. 1998;52:93-7.