

# Visual Function Following Congenital Cataract Surgery

Misao Yamamoto, Murat Dogru, Makoto Nakamura,  
Hiroko Shirabe, Yasutomo Tsukahara, Yoshibumi Sekiya

*Department of Ophthalmology, Kobe University School of Medicine, Kobe, Japan*

**Abstract:** To evaluate the results of congenital cataract extraction and postoperative visual function, we retrospectively reviewed the records of 95 patients who underwent pars plana (plicated) lensectomy or aspiration surgery. Forty-nine percent of the patients with bilateral aphakia and 25% with bilateral pseudophakia had a Landolt visual acuity of 0.5 or above at the final visit. The figures were 31% and 66% for patients with unilateral aphakia and pseudophakia, respectively. Eight patients (16.3%) with bilateral and 2 patients (5.8%) with unilateral cataract for whom contact lenses were prescribed after surgery attained fine stereopsis. Five of 8 patients (62.5%) with unilateral cataract who had intraocular lens implantation ended up with gross or fine stereopsis. We stress that very early surgery and optical correction in the sensitive period of binocular visual development should be instituted, especially in the presence of dense opacities. A good postoperative visual outcome can be achieved in patients undergoing late surgery if the opacities are light or partial in nature. We also reemphasize the importance of aggressive and diligent visual rehabilitation and occlusion therapy against amblyopia. **Jpn J Ophthalmol 1998;42:411-416** © 1998 Japanese Ophthalmological Society

**Key Words:** Amblyopia, aphakia, congenital cataract, pars plana lensectomy, stereopsis.

## Introduction

An infantile cataract not only blurs the retinal image but also disrupts the development of visual pathways. Although cataracts are one of the most treatable causes of visual impairment during infancy, it is rather difficult to obtain a good visual function following congenital cataract surgery.

A good postoperative visual function requires proper selection and performance of the surgical method, early and proper correction of refractive errors, as well as keen and persistent rehabilitation. With the addition of newer surgical techniques, instrumentation, intraocular lens designs, and materials, cataract extraction with correction of aphakia in children continues to evolve. The purpose of this report is to evaluate the results of cataract extraction and postoperative visual function in a series of pa-

tients who received either contact lens fitting or posterior chamber intraocular lens implantation.

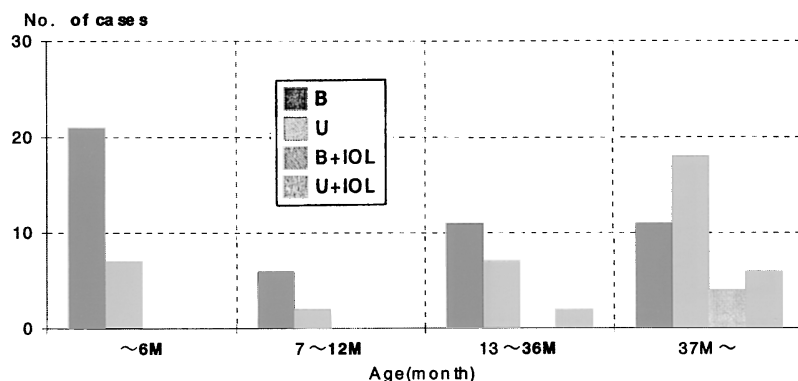
## Patients and Methods

Ninety-five children (48 boys, 47 girls) with cataracts were operated on and rehabilitated at Kobe University Hospital, Department of Ophthalmology between 1986 and 1996. We analyzed the visual function and prognosis of infantile cataracts when the visual functions could be assessed. As it was very difficult to establish the age of onset of cataracts with certainty, we did not attempt to distinguish the infantile cataracts as developmental or congenital in this study. All patients were examined by a pediatrician for systemic diseases and dysmorphic features. A routine ocular examination was then performed, if possible, including an assessment of visual acuity by preferential looking, the pupillary responses, ocular motilities, biomicroscopy, funduscopy, and B-scan ultrasonography in necessary cases. Seventy-three patients underwent pars plana or plicated lensectomy. Ten cases had aspiration. Intraocular lens (IOL) implantation was carried out in 12 cases after routine planned extracapsular extraction. All lenses were fixated intracapsularly.

Received: January 22, 1998

Address correspondence and reprint requests to: Misao YAMAMOTO, MD, PhD, Kobe University Hospital, Department of Ophthalmology, Chuo-ku, Kusunoki-cho 7-5-2, Kobe 650, Japan

This article was presented at the Second European Congenital Cataract Symposium, London, June 27, 1996.



**Figure 1.** Age at surgery. B: bilateral; U: unilateral; B + IOL: bilateral intraocular lens implantation, U + IOL: unilateral intraocular lens implantation.

Cataract surgery was bilateral in 53 and unilateral in 42 patients. The age at surgery varied between 1 and 192 months, with a mean value of  $49.3 \pm 51.9$  months (Figure 1). Intraocular lens implantation was performed bilaterally in 4 patients. Intraocular lens implantation was carried out in patients aged 2 years or older to avoid the complex problems related to aphakic rehabilitation seen frequently in children. We preferred polymethyl methacrylate single piece IOL implants (diameter: 12–13 mm), with powers calculated by the Sanders, Retzlaff, and Kraff formula. Although the Sanders, Retzlaff, and Kraff formula was taken into consideration, we aimed to undercorrect by choosing intraocular lenses with powers ranging between 21–25 D (mean:  $23 \pm 2$  D). Betamethasone and ofloxacin eyedrops were prescribed for the patients and were continued for 1 month, as well as a mydriatic-like tropicamide eye-drop for 2 or 3 weeks after the surgery. Posterior capsular opacification occurring after surgery was handled by yttrium-aluminum-garnet (YAG) laser capsulotomy in children above 5 years of age. Smaller children who could not comply with YAG laser capsulotomy procedures received operative secondary capsulectomy under general anesthesia. Patients received visual rehabilitation the day after surgery and preferential or Landolt visual acuities were assessed at each follow-up visit.

The mean age at the final postoperative visual acuity assessment was 9.2 years for bilateral and 8.2 years for unilateral cataract surgery. The figures were 10.8 years and 12.8 years for bilateral and unilateral IOL implantation patients, respectively. Aphakic rehabilitation in those patients without an intraocular lens implant was carried out by using hard gas permeable contact lenses after a thorough training of the parents before surgery. The children were fitted with trial lenses, after which the proper base curve and size were assessed by checking fluorescein

patterns and lens motility. Lens power was determined by careful retinoscopy. In the infantile period, contact lenses were adjusted for near vision whereas upon starting school, lenses designed for distant vision were preferred. Eye patching immediately after surgery was instituted to combat amblyopia and was tailored according to the needs of the individual patient.

Stereopsis (Titmus Stereo Tests) and eye position, compliance to contact lens wear and occlusion were also recorded at each examination. The follow-up period varied between 25 and 98 months (mean:  $61.5 \pm 36.5$  months).

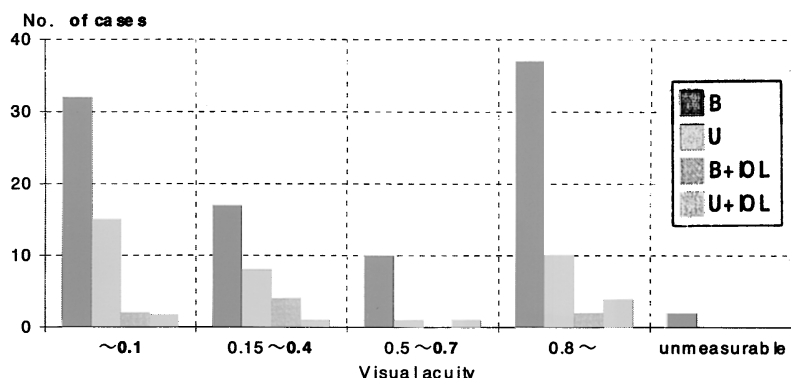
## Results

Systemic disorders associated with cataract were diagnosed in 14 patients (Table 1). Five patients had microcornea. One patient had optic nerve hypoplasia and another had hypertelorism. Patient age at surgery ranged between 1 month and 192 months. The overall visual acuity results following surgery

**Table 1.** Systemic and Ocular Disorders Associated with Cataract

Disorders	Number of Patients
Systemic disorders	
Rubella syndrome	3
Marinesco Sjögren syndrome	1
Cockayne syndrome	1
Down syndrome	1
Atopic dermatitis	1
Hypothyroidism	1
Cerebral palsy	1
Mental retardation	4
Ectodermal hypoplasia	1
Ocular disorders	
Microphthalmia	5
Optic nerve hypoplasia	1
Hypertelorism	1

**Figure 2.** Final visual acuity. Preferential looking method used for visual acuity assessment in 10 cases with bilateral, 1 case with unilateral cataract and 1 case with bilateral intraocular implantation. B: bilateral; U: unilateral; B + IOL: bilateral intraocular lens implantation; U + IOL: unilateral intraocular lens implantation.



are summarized in Figure 2. Forty-nine percent of the patients with bilateral cataracts who received contact lenses after surgery and 25% who had IOL implantation achieved a Landolt visual acuity of 0.5 or above. The figures were 31% and 66% for the patients with unilateral cataracts, respectively (Figure 3). The mean ages at surgery for patients depicted in Figure 3 were 5.4, 7.8, 13, and 8.3 years consecutively for bilateral, unilateral contact lens wear and bilateral, unilateral IOL implant patients. The relation of postoperative visual acuity to the age at surgery for contact lens wear or IOL implantation patients is shown in Figure 4. Forty-seven percent of the patients with bilateral cataract who received surgery before 2 years of age had a final visual acuity of 0.1 or below whereas those operated on thereafter, excluding two eyes, achieved better visual results. Over half the patients with unilateral cataracts who were operated on on or before the first birthday did not attain a visual acuity above 0.1. Cases with IOL implants were relatively older at the time of surgery, resulting in better visual acuities. Compliance was regarded as "good" if more than 80% of the criteria for visual rehabilitation as determined by the responsible physician were met by the patient. Compliance to visual rehabilitation was assessed as "good" in 59 patients. Three patients with bilateral cataract could not comply with contact lens wear and switched to spectacle use. Twenty-five patients with unilateral cataract showed good compliance to contact lens wear. Seven patients with bilateral and 18 patients with unilateral cataract had good compliance to occlusion (Figure 5).

The incidence of strabismus after cataract surgery was higher for unilateral cataract patients in this series. Fifty percent of unilateral and 40% of bilateral cataracts were associated with strabismus. Forty-four patients were orthophoric, 21 had exotropia, 14 had esotropia, and 3 cases were diagnosed as having

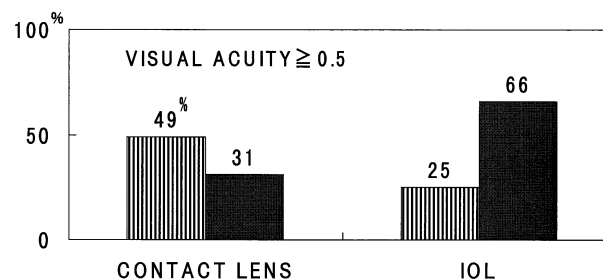
cyclotropia. Ten patients with bilateral and 3 patients with unilateral cataract had esodeviation. Esotropia was more common in bilateral cataracts. Ten individuals had to undergo strabismus surgery eventually.

Three patients (8.8%) with unilateral cataract who were rehabilitated with contact lens following surgery, compared to 8 patients (16.3%) with bilateral aphakia, achieved gross stereopsis.

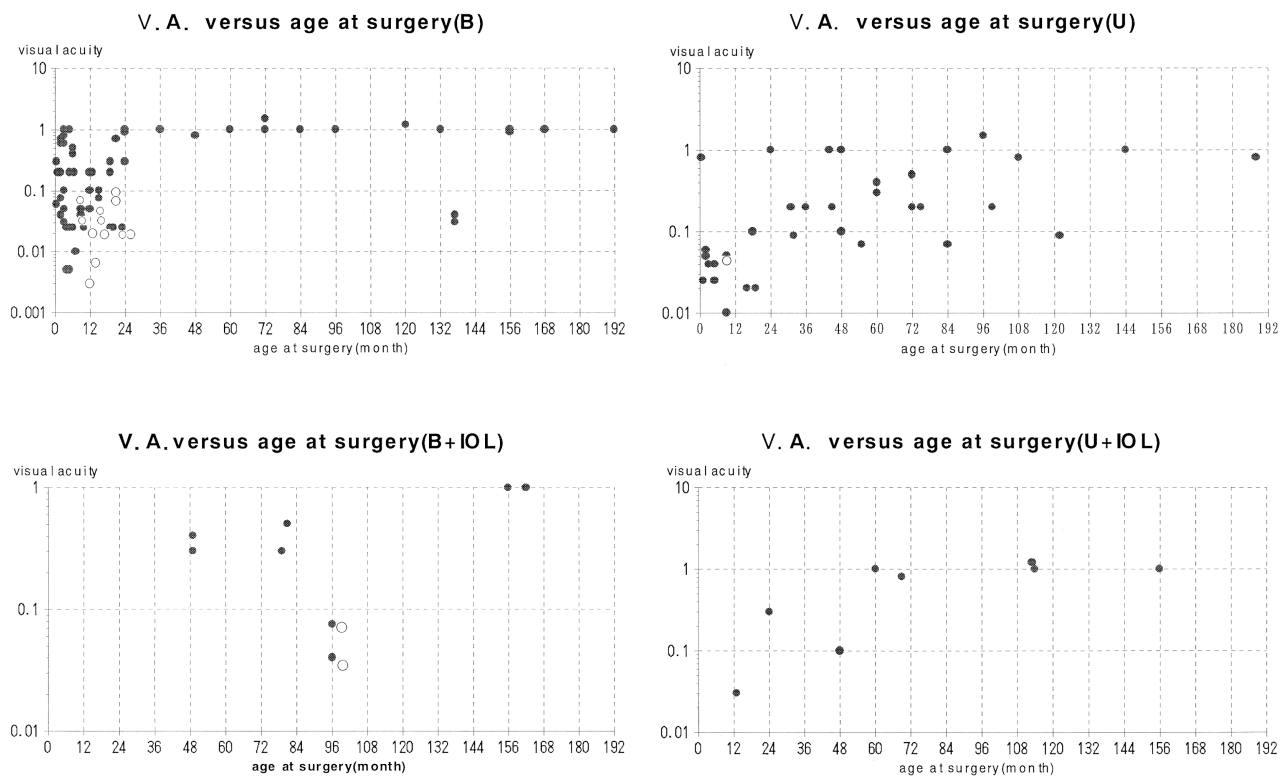
Eight patients (16.3%) with bilateral and 2 patients (5.8%) with unilateral cataract, who were prescribed contact lenses after surgery, attained fine stereopsis. Five of 8 patients (62.5%) with unilateral cataract who had IOL implantation achieved gross or fine stereopsis. The mean age at final stereopsis assessment was 11.6 years (Figure 6).

Preoperative nystagmus existed in 31 patients, 30 of whom had persistent nystagmus following cataract surgery (Figure 7). Nystagmus was more common in bilateral cataracts. Thirty-two patients with bilateral aphakia and 2 patients with bilateral IOL implants had persistent nystagmus.

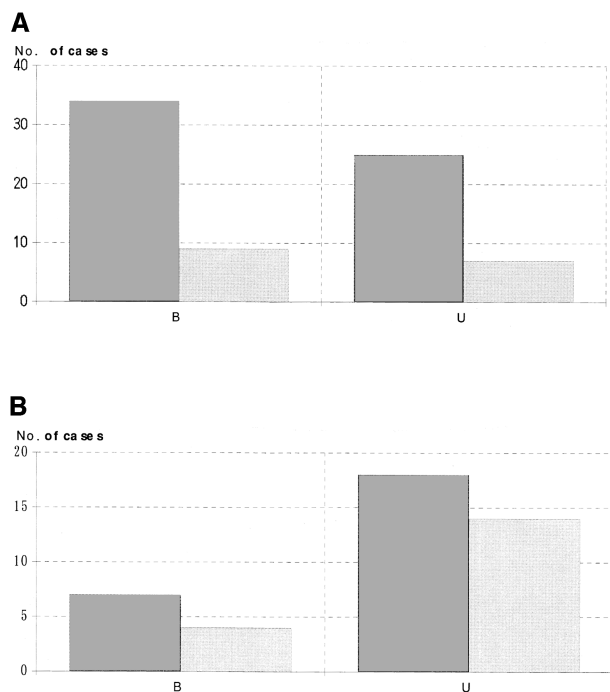
Posterior capsular opacification was almost universal in this series, but 15 patients (31.3%) needed secondary intervention. Six cases had a YAG laser



**Figure 3.** Comparison of visual results in relation to method of aphakic correction. Striped bar = bilateral, solid bar = unilateral.



**Figure 4.** Visual acuity versus age at surgery. ●: Landolt visual acuity data, ○: Preferential looking acuity data.



**Figure 5.** (A) Compliance to contact lens and spectacle wear. (B) Compliance to occlusion. Dark bar = good, light bar = poor.

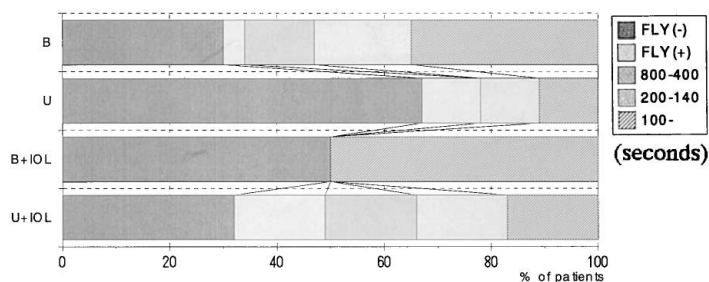
posterior capsulotomy, whereas 9 received secondary operative capsulectomy. Secondary glaucoma was diagnosed in 4 cases (4.2%). Five cases (5.2%) had pupillary deviation. Retinal detachment was not observed in this series.

## Discussion

Aphakic optical correction in children has been traditionally carried out with spectacles and contact lenses. Spectacles are associated with optical aberrations and are cosmetically undesirable. Contact lenses require diligent attendance by the patients and parents, who are also usually burdened with amblyopia therapy and expenses of lens care. Epikeratophakia may offer another form of optical correction to the older aphakic child, but at present is not widely available, and is expensive. The procedure may not allow a clear visual axis early enough, which is often slow to resolve. IOL implantation avoids many of these difficulties while potentially adding some of its own, which are universally known.<sup>1-13</sup>

The visual outcome for pediatric cataracts is dependent on many factors, including the age when the

**Figure 6.** Stereopsis using Titmus Stereo Test.

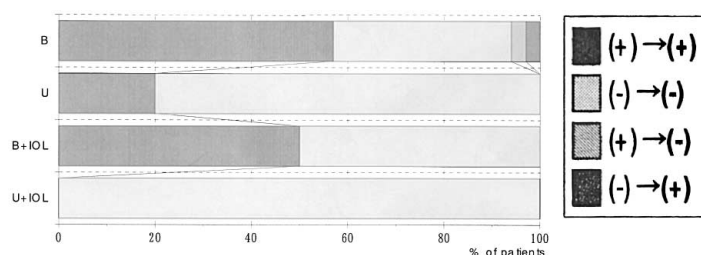


cataracts develop, the density of cataracts, the age at which optical correction is initiated, and the degree with which the fellow eye is occluded.<sup>1,3</sup> The visual prognosis is generally accepted to be better for bilateral cataracts.<sup>14,15</sup> Visual results were also promising in our bilateral cataracts. There were 32 eyes with bilateral congenital cataract in whom we could not attain a visual acuity of above 0.1. This, we believe, might have resulted from the association of systemic or ocular complications or the presence of mental retardation in these patients. The visual prospects were disappointing in unilateral compared to bilateral cataracts, similar to many other studies.<sup>16-19</sup> Still, there were cases who achieved a visual acuity of 0.8 or above. Those were the subjects with light partial lenticular opacities. Intraocular lens implantation was carried out in children aged 2 years or above. There were 2 cases who underwent surgery before 2 years of age who did not end up with a favorable visual prognosis. One of them was a unilateral cataract patient who had poor occlusion compliance; the other had bilateral cataract and contact lens wear was abandoned. Several reports state that the earlier the age at surgery the better the visual prognosis.<sup>20,21</sup> However, nearly 50% of the patients with bilateral cataract who received surgery before 2 years of age, or over half the patients with the unilateral cataract variety operated on on or before the first birthday, could not attain a visual acuity above 0.1. A recent report from Elston and Timms suggests that the first 6 weeks of life represents a sensitive pe-

riod for binocular development.<sup>22</sup> The variations in visual prognosis can be attributable to the degree of visual deprivation induced by cataract itself in the early period of life. The patients in this series were operated on rather late. Those patients who received early surgery were still not in the range of the aforementioned sensitive period because they had applied late to our facility or systemic problems did not allow us to carry out surgery earlier. Patients with poor visual prognosis were believed to have already acquired very severe visual deprivation in the early sensitive period. There was one case with unilateral cataract who underwent very early surgery in the sensitive period and showed tremendous visual improvement. There were similar bilateral cataract cases. Patients with IOL implantation were older at the time of surgery and had comparatively better visual acuities. Twenty-nine percent of the patients with unilateral cataract were rehabilitated by contact lens wear whereas 69.6% of those with bilateral cataract ended up with gross stereopsis. We could show gross or fine stereopsis in 5 of 7 patients with unilateral cataract who had IOL implantation. We believe that a one-stage correction in refractive error by IOL implant in conjunction with proper occlusion compliance favorably influences the development of stereopsis. This finding was in agreement with a previous report.<sup>23</sup>

Strabismus was more common in unilateral cataracts as in other studies.<sup>24</sup> Ten patients had to undergo eventual strabismus surgery. Patients with

**Figure 7.** Course of nystagmus before and after surgery. (+) → (+): Nystagmus present before and after surgery, (-) → (-): Nystagmus absent before and after surgery, (+) → (-): Nystagmus disappearing after surgery, (-) → (+): Nystagmus appearing after surgery due to poor compliance to visual rehabilitation.



strabismus in whom we could not achieve good visual results probably had established amblyopia despite successful surgery and rehabilitation efforts.

Another factor that affects the final visual outcome is nystagmus. Nystagmus was especially observed in those patients with bilateral cataracts with a delay in treatment or poor postoperative compliance to visual rehabilitation. We think that early surgery coupled with immediate optical correction can eliminate this problem.

We did not encounter major postoperative complications in this series. We experienced secondary cataracts in 31.3% and open angle glaucoma in 4.2% of the patients. Posterior capsular opacifications were treated with YAG laser posterior capsulotomy. Laser treatment at the first sign of opacification allows for earlier institution or continuation of amblyopia therapy. Cases in whom YAG laser could not be performed underwent uncomplicated operative capsulectomy. The incidence of glaucoma was low and similar to the Chrousos' series.<sup>25</sup> Medical and surgical therapy controlled the intraocular pressure effectively in our patients and it did not become a factor to influence the visual outcome, at least until now.

We agree with many other authors that very early surgery and optical correction in the sensitive period of binocular visual development should be instituted especially in the presence of dense opacities which are likely to be associated with severe deprivation amblyopia. Such attempts may yield excellent postoperative visual results. We also think that a good postoperative visual outcome can be achieved in patients undergoing late surgery if the opacities are light or partial in nature. We also reemphasize the importance of aggressive and diligent visual rehabilitation and occlusion therapy against amblyopia.

## References

1. Lambert S, Drack A. Infantile Cataracts. *Sur Ophthalmol* 1996;40:427-58.
2. Markham RHC, Bloom PA, Chandna A, Newcomb EH. Results of intraocular lens implantation paediatric aphakia. *Eye* 1991;6:493-8.
3. Brady KM, Atkinson S, Kilty L, Hiles DA. Cataract surgery and intraocular lens implantation in children. *Am J Ophthalmol* 1995;120:1-9.
4. Rosenbaum AL, Masket S. Intraocular lens implantation in children. *Am J Ophthalmol* 1995;120:105-7.
5. Sinsky RM, Stoppel JO, Amin P. Long term results of intraocular lens implantation in pediatric patients. *J Cataract Refract Surg* 1993;19:405-8.
6. Vasavada A, Chauhan H. Intraocular lens implantation in infants with congenital cataracts. *J Cataract Refract Surg* 1994;20:592-8.
7. Kora Y, Shimizu K, Inatomi M, Fukado Y, Ozawa T. Eye growth after cataract extraction and intraocular lens implantation in children. *Ophthalmol Surg* 1993;24:467-75.
8. Sinskey R, Amin P, Lingua R. Cataract extraction and intraocular lens implantation in an infant with a monocular congenital cataract. *J Cataract Refract Surg* 1994;20:647-51.
9. Kora Y, Shimizu K, Inatomi M, Fukado Y, Marumori M, Yaguchi S. Long term study of children with implanted intraocular lenses. *J Cataract Refract Surg* 1992;18:485-8.
10. Lorenz B, Worle J. Visual results in congenital cataract with the use of contact lens. *Graefes Arch Ophthalmol* 1991;229:123-32.
11. Moore BD. Pediatric aphakic contact lens wear: Rates of successful wear. *J Pediatr Ophthalmol Strabismus*. 1993;30:253-8.
12. Amos CF, Lambert SR, Ward MA. Rigid gas permeable contact lens correction of aphakia following congenital cataract removal during infancy. *J Pediatr Ophthalmol Strabismus* 1992;29:243-5.
13. Parks MM, Johnson DA, Reed GW. Long term visual results and complications in children with aphakia. *Ophthalmol* 1993;100:827-41.
14. Bradford GM, Keech RV, Scott WE. Factors affecting visual outcome after surgery for bilateral congenital cataracts. *Am J Ophthalmol* 1994;117:58-64.
15. Kugelberg U. Visual acuity following treatment of bilateral congenital cataracts. *Documenta Ophthalmol* 1992;82:211-5.
16. Birch EE, Stager DR. Prevalence of good visual acuity following surgery for congenital unilateral cataract. *Arch Ophthalmol* 1988;106:40-3.
17. Cheng KP, Hiles DA, Biglan AW, Pettapiece MC. Visual results after early surgical treatment of unilateral congenital cataracts. *Ophthalmol* 1991;98:903-10.
18. Catalano RA, Simon JW, Jenkins PL, Kandel GL. Preferential looking as a guide for amblyopia therapy in monocular infantile cataracts. *J Pediatr Ophthalmol Strabismus* 1987;24:56-63.
19. Lewis TL, Maurer D, Brent HP. Development of grating acuity in children treated for unilateral or bilateral congenital cataract. *Invest Ophthalmol Vis Sci* 1995;36:2080-95.
20. Birch EE, Swanson WH, Stager DR, Woody M, Everett M. Outcome after very early treatment of dense congenital unilateral cataract. *Invest Ophthalmol Vis Sci* 1993;34:3687-99.
21. Birch EE, Stager DR, Wright WW. Grating acuity development after early surgery for congenital unilateral cataract. *Arch Ophthalmol* 1986;104:1783-7.
22. Elston JS, Timms C. Clinical evidence for the onset of the sensitive period in infancy. *Br J Ophthalmol* 1992;76:327-8.
23. Tytla ME, Lewis TL, Brent HP. Stereopsis after congenital cataract. *Invest Ophthalmol Vis Sci* 1993;34:1767-73.
24. Hiles DA, Sheridan SJ. Strabismus associated with infantile cataracts. *Int Ophthalmol Clin* 1977;17:193-202.
25. Chrousos GA, Parks MM, O'Neill JF. Incidence of chronic glaucoma, retinal detachment and secondary membrane surgery in pediatric aphakic patients. *Ophthalmol* 1984;91:1238-1241.