

Clinical Phenotype of a Japanese Family With Primary Open Angle Glaucoma Caused by a Pro370Leu Mutation in the MYOC/TIGR Gene

Fumiko Taniguchi,*
Yasuyuki Suzuki,[†] Shiroaki Shirato[‡] and Shigeo Ohta[§]

**Eye Clinic, Ohmiya Red Cross Hospital, Saitama, Japan; [†]Department of Ophthalmology, Nippon Medical School, Tokyo, Japan; [‡]Department of Ophthalmology, University of Tokyo School of Medicine, Tokyo, Japan; [§]Division of Biochemistry, Institute of Gerontology, Nippon Medical School, Kanagawa, Japan*

Purpose: To present the phenotype of two patients with primary open angle glaucoma (POAG) caused by a mutation of the myocilin/trabecular meshwork-inducible glucocorticoid response (MYOC/TIGR) gene.

Methods: Complete ocular examinations were performed on the 13-year-old proband, her father, mother, and sister. DNA analysis was performed to detect the mutant gene.

Results: The proband and her father were found to have a mutation of the MYOC/TIGR gene. Both patients carried a heterozygous mutation in the 1,109th nucleotide, which corresponds to the 370th amino acid residue of the MYOC/TIGR gene. The clinical characteristics of both patients were: (1) development of POAG at an early age, (2) high peaks of intraocular pressure, and (3) poor response to medical treatment.

Conclusions: The phenotype of these patients with a mutation of the MYOC/TIGR gene agreed with reports of other patients with mutations at other loci in this gene. The discovery of the MYOC/TIGR gene not only makes early detection of glaucoma possible, but also presents a new direction for investigating the pathogenesis of glaucoma. **Jpn J Ophthalmol 1999;43:80-84** © 1999 Japanese Ophthalmological Society

Key Words: Glaucoma genetics, juvenile-onset primary open-angle glaucoma, myocilin/trabecular meshwork inducible glucocorticoid response gene.

Introduction

The myocilin/trabecular meshwork-inducible glucocorticoid response (MYOC/TIGR) gene is the first gene identified with a mutation that causes primary open angle glaucoma (POAG).¹ Stone et al¹ reported that three different mutations in exon 3 of the gene were responsible for causing glaucoma in some juvenile-onset and adult-onset primary open-angle glaucoma patients.¹ Thereafter, several other mutations also located in exon 3 of the MYOC/TIGR gene were reported to be responsible for the

development of POAG.² We have reported two new mutations, Pro370Leu and Gly367Arg, in the MYOC/TIGR gene in a Japanese family with POAG.³

Because the function and the metabolism of the protein produced by the MYOC/TIGR gene are unclear, it is important to establish the phenotype of subjects with mutations in this gene to determine the role of the MYOC/TIGR gene. In this report, we describe the clinical features of a Japanese family with the Pro370Leu mutation in the MYOC/TIGR gene.

Case Report

The Proband

The patient was a 13-year-old girl when she underwent her first ocular examination in 1993 at the De-

Received: March 12, 1998

Address correspondence and reprint requests to: Fumiko TANIGUCHI, MD, Eye Clinic, Ohmiya Red Cross Hospital, 8-3-33, Kami-ochiai, Yono-City, Saitama, 338, Japan

partment of Ophthalmology of the University of Tokyo. Intraocular pressure (IOP) was 28 mm Hg in both eyes and gonioscopic examination revealed normal open angles. Fundusoscopic examination showed no glaucomatous optic disc changes in either eye. The visual fields tested by Humphrey Field Analyzer, programs 30-1, 30-2, and 30-60 (Humphrey Instruments, San Leandro, CA, USA) were normal in both eyes. Her visual acuity was 24/20 with refractive error of spherical -0.25 diopters (D) in both eyes. Although her IOP remained in the mid- to high 20s, she was followed periodically at our clinic as an ocular hypertension patient without any medication.

At the age of 15 years, she developed a visual field defect in her right eye, corresponding to a nerve fiber layer defect and the diagnosis was changed to POAG (Figure 1). Administration of 2% carteolol hydrochloride (Mikeran®; Ohtsuka, Tokyo) twice a day was started, but her IOP remained in the high 20s. In addition to the carteolol medication, 0.12% isopropyl unoprostone (Rescula®; Fujisawa, Osaka) twice a day was also not effective and her IOP remained around 26 mm Hg in both eyes for 2 years.

In 1997, IOP rose to 33 mm Hg and 30 mm Hg and could not be lowered below the mid-20s, even with the administration of 2% pilocarpine (Sanpilo®;

Santen, Osaka) and 250 mg of oral acetazolamide (Diamox®; Lederle, Tokyo). Because her visual field defect had recently showed exacerbation, surgical intervention was considered. The results of retinal function tests including electroretinogram (ERG), oscillatory ERG, photopic ERG, and scotopic ERG were normal.

The Father

POAG was first diagnosed in her father at the age of 26 in 1980. He had had a history of halo vision several times a year in both eyes from the age of 19. He visited an ophthalmologist in 1980 complaining of recurrent and persistent halo vision for 2 years. He was diagnosed as having POAG with intraocular pressure over 50 mm Hg in both eyes, as measured by Shiøtz tonometer. He underwent trabeculectomy once in the left eye and twice in the right eye in 1980 because his IOP could not be controlled with tolerable antiglaucoma medication, including oral acetazolamide.

In 1981, 6 months after the second trabeculectomy on the right eye, he was referred to the University of Tokyo because of uncontrollable high IOP in both eyes under medication with 2% pilocarpine and 750

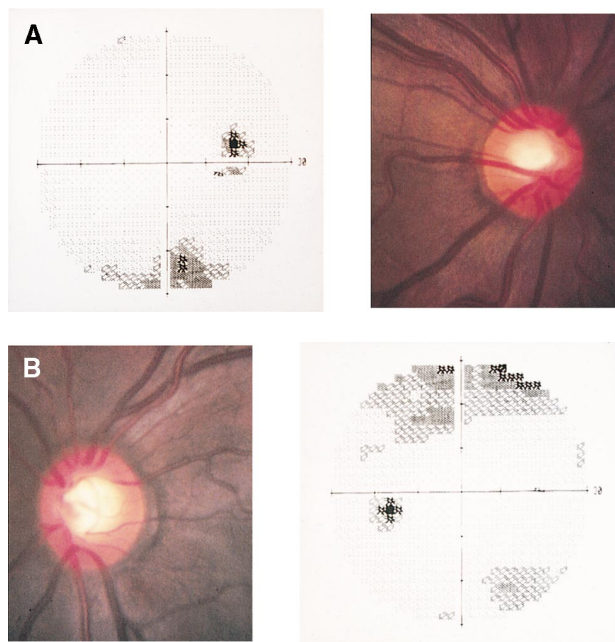


Figure 1. Visual field and optic disc of proband (girl, 13 years old) (A) right eye, (B) left eye. Nerve fiber layer defect that corresponds to visual field defect is observed in right eye.

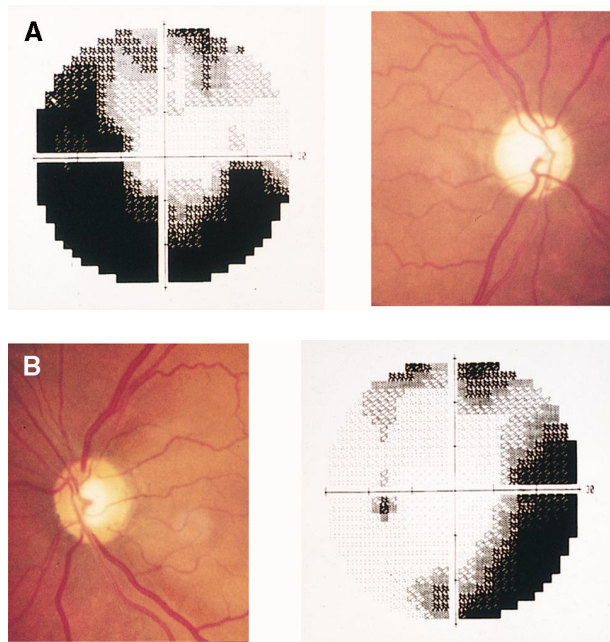


Figure 2. Visual field and optic disc of affected father (A) right eye, (B) left eye. Glaucomatous optic disc atrophy is recognized accompanied by visual field defects in both eyes.

mg oral acetazolamide. His IOP was 44 mm Hg in the right and 43 mm Hg in the left eye when he first visited us. Visual acuity of his right and left eyes was 24/20 and 30/20, respectively, with refractive error of -1.5 D in both eyes. Gonioscopic examination revealed that he had normal open angles. Glaucomatous optic disc atrophy was recognized with the cup:disc ratio of 0.85×0.85 in the right eye and 0.8×0.9 in the left eye, accompanied by visual field defects in both eyes (Figure 2). After the prescription of 1.25% epinephrine (Epista®; Senju, Osaka), 2% carteolol, 3% pilocarpine, and 150 mg methazolamide (Neptazan®; Lederle), his IOP was maintained around 20 mm Hg. After a second trabeculectomy on his left eye in 1982, his IOP remained between 16–20 mm Hg in both eyes with topical antiglaucoma medication. In 1988, his IOP gradually reached 48 mm Hg in his right eye and 26 mm Hg in the left eye. The third trabeculectomy, using postoperative subconjunctival 5-fluorouracil injection, was performed in both eyes in 1988. Since then his IOP in both eyes has been controlled around 10 mm Hg without any antiglaucoma medications and his visual field has shown no deterioration.

Other Family Members

We examined the sister and mother of the proband. Both had normal IOP with no glaucomatous optic disc change and normal visual field. The paternal grandfather and grandmother of the proband are deceased and we could not determine whether they had had ocular disease. The father's only brother has no ocular symptoms and was judged to be normal by an ophthalmologist.

Detection of the MYOC/TIGR Gene Mutation

Informed consent was given and peripheral blood samples of the proband (the daughter) and the three other family members were obtained. Genomic DNA was extracted with QIA amp Blood Kit (QIAGEN, Chatsworth, CA, USA). DNA fragment encoding a peptide of TIGR corresponding to the 317th–476th amino acid residue was amplified by the polymerase chain reaction (PCR) method with primers: ATACTGCCTAGGCCACTGGA (5'-sense direction) and CATGCTGCTGTACTTATAGCGG (3'-antisense direction). PCR was performed in a total volume of 100 μ L that consisted of 150 ng template, 8 μ L of the deoxynucleotides mixture, 10 pmol of each primer, 10 μ L of $10\times$ buffer containing 1.5 mmol/L MgCl₂, and 0.5 μ L of *Taq* polymerase (Ampli*Taq* Gold; Perkin Elmer, Foster City, CA, USA).

Amplification conditions consisted of 10 minutes of preincubation and 35 cycles under the following conditions: 94°C for 30 seconds, 55°C for 30 seconds, 72°C for 1 minute in a thermocycler (Takara, Tokyo). The nucleotide sequences of both strands of the PCR products were directly determined with the terminator cycle sequencing method using fluorescent dideoxynucleotides and an automatic DNA sequencer (model 373S; Perkin Elmer Applied Biosystems). When a mutation was detected, the whole procedure was repeated to confirm the mutation.

The proband and the father were found to carry a heterozygous mutation of cytosine (C) to thymine (T) at the 1,109th nucleotide, which corresponds to the second nucleotide of the 370th amino acid residue of MYOC/TIGR, resulting in amino acid change from proline to leucine (Pro370Leu) (Figure 3). The sister and mother of the proband carried no mutation in the MYOC/TIGR gene, and thus, the mutation was thought to be inherited in an autosomal dominant manner.

Discussion

In this family, two POAG patients carried the MYOC/TIGR gene mutation at the 370th amino acid residue and the other family members examined had no MYOC/TIGR gene mutation or ocular disease. The patients had been diagnosed with POAG at the ages of 15 and 26 years, but the development of the disease in the father could have been earlier than age 26 because he had a history of recurrent halo vision since age 19. Both patients had normal open angle, high IOP, which was uncontrollable with antiglaucoma medication, including oral carbonic anhydrase inhibitors. Glaucomatous optic disc changes with visual field defects were present. The patients, therefore, can be diagnosed as having juvenile glaucoma, defined conventionally as chronic open angle glaucoma with onset between 10 and 35 years of age.⁴

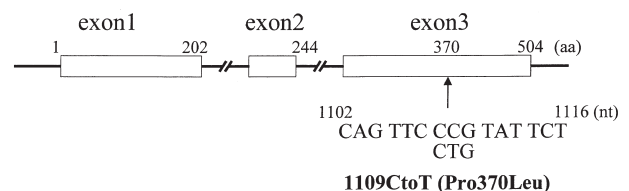


Figure 3. Structure of myocilin/trabecular meshwork inducible glucocorticoid response gene. C→T transition observed in patients of this family resulted in amino acid change from proline to leucine.

In heritable juvenile-onset open angle glaucoma, the gene *GLC1A* on chromosome 1q (q21–q31), where the *MYOC/TIGR* gene is found, has been considered as the causable gene. Most of the reported pedigrees linked to *GLC1A* had the following characteristics: (1) development of POAG at a very early age, (2) high peaking of IOP, and (3) poor response to medical treatment.^{5–9} Our patients had similar characteristics. On the other hand, Meyer et al¹⁰ and Morissette et al¹¹ demonstrated that *GLC1A* can be responsible for both juvenile- and adult-onset glaucomas. In the families they reported, some patients developed the disease in the early period of their lives but others did not (the age ranges of onset were 11–51 and 8–62 years, respectively). There might be some relationship between mutation site and clinical phenotype. Recently, eight French families with *MYOC/TIGR* gene mutation were reported.² In this report, the mutation of the 246th and 370th amino acid residue of *MYOC/TIGR* resulted in the very early onset of POAG (median age at diagnosis in 3 of 8 families was 10, 11, and 20 years); mutation of the 477th, 480th, and 499th amino acid residues resulted in the onset of the disease in middle age (median age in remaining 5 families was 30, 31, 32, 33, and 35). As was reported by us, another Japanese POAG patient with *MYOC/TIGR* gene mutation of Gly367Arg developed the disease at age 45.³ These data suggest that the location of the mutation in the *MYOC/TIGR* gene can influence the age of onset. The 246th and 370th amino acid change may result in an earlier onset of the disease compared with the 367th, 477th, 480th, and 499th amino acid changes.

The role of the *MYOC/TIGR* gene product in the development of POAG is unknown. It is reported that the *MYOC/TIGR* protein is expressed in cultured human trabecular meshwork cells after the prolonged exposure to glucocorticoid or oxidative stress.^{12–15} Because the immunofluorescence study using polyclonal *MYOC/TIGR* antibody showed the expression of the *MYOC/TIGR* protein in the trabecular meshwork layers of POAG eyes and in the uveal cells of normal eyes, the *MYOC/TIGR* protein is probably derived from the aqueous humor and plays a role in the reduction of the outflow facility of the aqueous humor.¹⁶ However, neither the exact mechanism of the expression and the regulation of the *MYOC/TIGR* gene nor the function of its product have been established.

Kubota et al¹⁷ reported that the *MYOC/TIGR* protein was preferentially localized in the ciliary rootlet and basal body of the connecting cilium of retinal photoreceptor cells. They suggested that mu-

tations in the *MYOC/TIGR* gene might be responsible for the pathogenesis of retinal diseases. In our study, the electrophysiological examination of the retinal functions of a patient with the *MYOC/TIGR* gene mutation did not reveal any abnormality. Whether the function of the *MYOC/TIGR* gene is the same in the trabecular meshwork, ciliary body, retinal photoreceptor cells, and other tissues has not yet been established.

The discovery of the *MYOC/TIGR* gene not only makes early detection of glaucoma possible, but also presents a new direction for investigating the pathogenesis of glaucoma. Further clinical and basic investigations of the *MYOC/TIGR* gene are expected to accelerate glaucoma study worldwide.

References

1. Stone EM, Fingert JH, Alward WLM, et al. Identification of a gene that causes primary open angle glaucoma. *Science* 1997;275:668–70.
2. Adam MF, Belmouden A, Binisti P, et al. Recurrent mutations in a single exon encoding the evolutionarily conserved olfactomedin-homology domain in *TIGR* in familial open-angle glaucoma. *Hum Mol Genet* 1997;12:2091–7.
3. Suzuki Y, Shirato S, Taniguchi F, et al. Mutation in *TIGR* gene in familial primary open angle glaucoma in Japan. *Am J Hum Genet* 1997;61:1202–4.
4. Ritch R, Shields MB, Krupin T. Clinical entities/congenital glaucoma. *The glaucomas*. St. Louis, MO: Mosby Year Book, 1996:730.
5. Sheffield VC, Stone EM, Alward WLM, et al. Genetic linkage of familial open angle glaucoma to chromosome 1q21–q31. *Nat Genet* 1993;4:47–50.
6. Johnson AT, Drack AV, Kwitek AE, Cannon RL, Stone EM, Alward WLM. Clinical features and linkage analysis of a family with autosomal dominant juvenile glaucoma. *Ophthalmology* 1993;100:524–9.
7. Graff C, Urbak SF, Jerndal T, Wadelius C. Confirmation of linkage to 1q21–31 in a Danish autosomal dominant juvenile-onset glaucoma family and evidence of genetic heterogeneity. *Hum Genet* 1995;96:285–9.
8. Wiggs JL, Haines JL, Paglinauan C, Fine A, Sporn C, Lou D. Genetic linkage of autosomal dominant juvenile glaucoma to 1q21–q31 in three affected pedigrees. *Genomics* 1994;21:299–303.
9. Richards JE, Lichter PR, Boehnke M, et al. Mapping of a gene for autosomal dominant juvenile-onset open-angle glaucoma to chromosome 1q. *Am J Hum Genet* 1994;54:52–70.
10. Meyer A, Bechettille A, Valtot F, et al. Age-dependent penetrance and mapping of the locus for juvenile and early-onset open-angle glaucoma on chromosome 1q (*GLC1A*) in a French family. *Hum Genet* 1996;98:567–71.
11. Morissette J, Cote G, Anctil JL, et al. A common gene for juvenile and adult-onset primary open-angle glaucoma confined on chromosome 1q. *Am J Hum Genet* 1995;56:1431–42.
12. Polansky JR, Kurtz RM, Alvarado JA, et al. Eicosanoid production and glucocorticoid regulatory mechanisms in cultured human trabecular meshwork cells. *Prog Clin Biol Res* 1989;312:113–38.
13. Polansky JR, Fauss DJ, Nguyen TD. Ophthalmic corticosteroids and steroid glaucoma mechanisms. *New Dev Glaucoma* 1995;2:215–28.

14. Polansky JR. HTM cell culture model for steroid effects on intraocular pressure: overview. In: Lutjen-Drecoll E, ed. Basic aspects of glaucoma research III. New York: Schattauer, Stuttgart, 1993:307-18.
15. Nguyen TD, Huang W, Bloom E, Polansky JR. Glucocorticoid (GC) effects on HTM cells: molecular biology approaches. In: Lutjen-Drecoll E, ed. Basic aspects of glaucoma research III. New York: Schattauer, Stuttgart, 1993:331-43.
16. Polansky JR, Fauss DJ, Chen P, et al. Cellular pharmacology and molecular biology of the trabecular meshwork inducible glucocorticoid response gene product. *Ophthalmologica* 1997; 211:126-39.
17. Kubota R, Noda S, Wang Y, et al. A novel myosin-like protein (Myocilin) expressed in the connecting cilium of the photoreceptor: molecular cloning, tissue expression, and chromosomal mapping. *Genomics* 1997;41:360-9.