

Effects of Aging on Fluorescein Leakage in the Iris and Angle in Normal Subjects

Kumiko Satoh,* Yoichi Takaku,*
Kiyoshi Ohtsuki[†] and Katsuyoshi Mizuno[‡]

*Eye Clinic, Sendai Shakaihoken Hospital,
Sendai, Miyagi, Japan; [†]Eye Clinic, NTT Tohoku Hospital,
Sendai, Miyagi, Japan; [‡]Eye Clinic, Toukai Memorial Hospital, Kasugai, Aichi, Japan

Purpose: To determine the presence of fluorescein leakage from the iris and angle in normal subjects, and how it is affected by aging.

Methods: The subjects were 92 normal volunteers and patients with senile cataract who ranged in age from 20 to 93 years and were free from any systemic or ocular diseases. Fluorescein iris and angle photography and color iris and angle photography were performed using a gonioscope and a photo slit lamp.

Results: Radial ciliary body vessels were found in 22 eyes (24%), radial iris vessels or trabecular vessels in 7 eyes (8%), and circular ciliary band vessels were seen in 4 eyes (4%). Gonio-vessels were found in 8 of 30 eyes (27%) of those under 50 years of age. No significant difference in the incidence of gonio-vessels was found between those over and under age 50 ($P < .01$). In the pupillary margin, fluorescein leakage was seen in 1 of 30 eyes (3%) in the age group under 50 years, whereas leakage was found in 30 of 62 eyes (48%) in the age group over 50 years. In the anterior chamber angle, leakage was seen in 4 of 30 eyes (13%) under age 50 years, and in 38 of 62 eyes (61%) over age 50 years ($P < .05$).

Conclusions: These findings suggested that the incidence of leakage of fluorescein from the pupillary margin and anterior chamber angle tends to increase with age. Thus, when leakage of fluorescein in angle and iris is observed, it is important to consider the physiological changes resulting from aging. **Jpn J Ophthalmol 1999;43:166-170** © 1999 Japanese Ophthalmological Society

Key Words: Aging, angle, blood-aqueous barrier, gonio-vessel, iris.

Introduction

Fluorescein iris and angle photography (FIAP) has been used clinically to evaluate the blood-aqueous barrier (BAB).¹ FIAP provides useful information on the degree of BAB dysfunction.² To evaluate the BAB function in patients who have intraocular disease, it is important to know first the appearance of the eyes of normal subjects when photographed by this technique and, particularly, the effect of aging.

Only a few studies have reported on the appearance of normal eyes in FIAP.^{3,4} In the present study, we photographed the eyes of normal subjects of various ages by FIAP to determine the changes in the BAB with aging. Color iris and angle photography (CIAP) was also performed. By CIAP and FIAP, we determined the relationship between the incidence of gonio-vessels and the age of the subject. In addition, we used FIAP to examine the profiles of fluorescein leakage from the pupillary margin and anterior chamber angle in different age groups.

Subjects and Methods

Our subjects included 92 normal volunteers and patients with senile cataract who ranged in age from 20 to 93 years. All subjects gave informed consent

Received: April 20, 1998

Correspondence and reprint requests to: Kumiko SATOH, MD, Iwakiri Central Eye Clinic 72-7, Dohnokuchi-higashi, Iwakiri Miyagino, Sendai, Miyagi Prefecture 983-0821, Japan

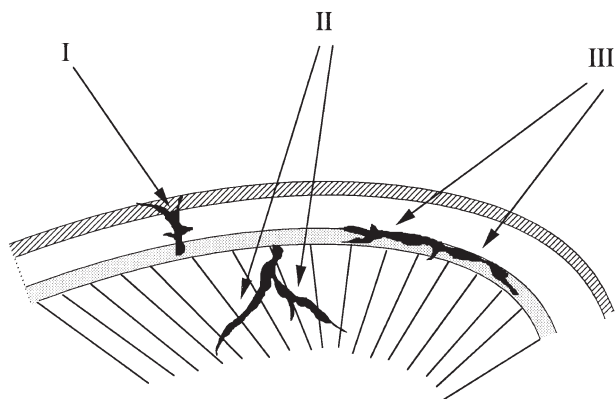


Figure 1. Henkind's grades and incidence of goniovascular in normal eyes.⁵ The following is a list of these grades and their incidence in the present study: (I) radial ciliary body or trabecular vessel, 22 eyes (24%); (II) radial iris vessel, 7 eyes (8%); and (III) circular ciliary band vessel, 4 eyes (4%).

and were free of any systemic and ocular disease other than senile cataract. FIAP and CIAP were performed on the iris and anterior chamber angle in all eyes using a gonio-lens¹ and a photo slit lamp (Carl Zeiss, Oberkochen, Germany) by the method reported previously.²

The photo slit lamp was equipped with an excitor filter (no. 485; Carl Zeiss) in front of the illuminator, and a barrier filter (no. 520; Carl Zeiss) in front of the camera. Settings of the photo slit lamp were: flash intensity of 720 W/s, an illumination aperture of 9, and lens aperture of 14. Kodak Tri-X film was

Table 1. Classification of Fluorescein Leakage in Pupillary Margin

Grade	Leakage
0	No leakage around pupillary margin
I	Some dot-shaped leakage around pupillary margin
II	Blot leakage less than halfway around pupillary margin
III	Blot leakage from halfway around to almost totally around pupillary margin
IV	Blot leakage all around pupillary margin

used. Five milliliters of 10% sodium fluorescein solution was injected into an antecubital vein as rapidly as possible. Photographs were taken at 1-second intervals.

Vessels that appeared in the anterior chamber angle on CIAP or FIAP were classified into three types, according to the classification of Henkind (Figure 1).⁵

By FIAP examination, fluorescein leakage was classified into five grades according to the extent of leakage (Table 1 and Figure 2). Leakage of fluorescein from the anterior chamber angle was also classified into five separate grades (Table 2). The data were tabulated according to each Table.

Results

Incidence of Goniovascular

Vessels that showed filling but no leakage of fluorescein were frequently observed in the angle by FIAP

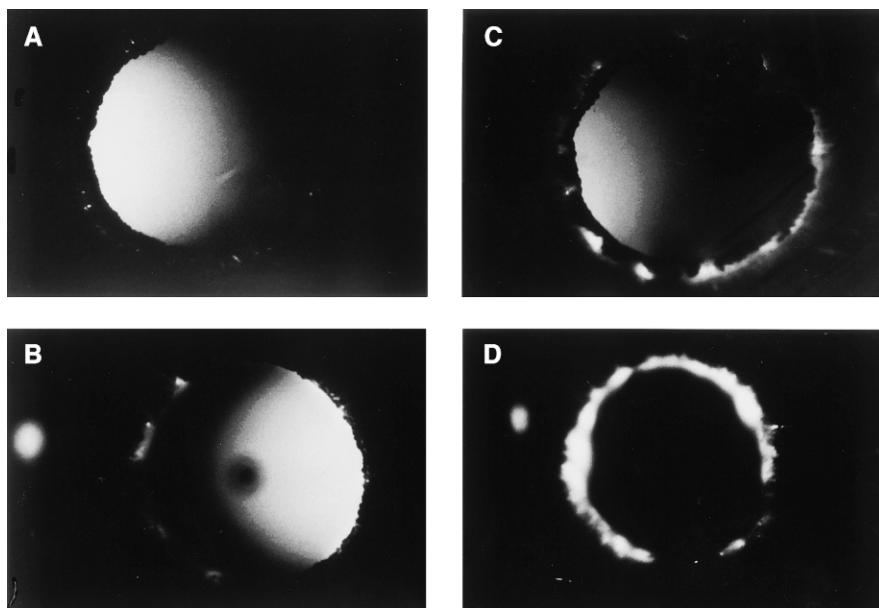


Figure 2. Representative photographs of fluorescein leakage from pupillary margin by fluorescein iris and angle photography (FIAP). (grade I) Some dot-shaped leakage around pupillary margin (A). (grade II) Blot leakage less than halfway around pupillary margin (B). (grade III) Blot leakage from halfway to almost entirely around pupillary margin (C). (grade IV) Blot leakage all around pupillary margin (D).

Table 2. Classification of Fluorescein Leakage in Anterior Chamber Angle

Grade	Leakage
0	No leakage around angle
I	Leakage in less than one-fourth of angle
II	Leakage in less than half of angle
III	Leakage in less than three-quarters of angle
IV	Leakage in almost entire angle

and were sometimes confirmed by CIAP. Vessels leaking fluorescein were found in 8 of 30 eyes (27%) of the subjects under 50 years old and in 17 of 62 eyes (27%) of the subjects over 50 years old (Table 3).

Incidence of Angle Vessels

Representative photographs of angle vessels in each of Henkind's grades are shown in Figure 3. The angle vessels in all the photographs were classified according to Henkind's grades: grade I, radial ciliary body or trabecular vessels were observed in 22 of 92 eyes (23.9%); grade II, radial iris vessels were seen in 7 eyes (8.7%); and grade III, circular ciliary band vessels were seen in 4 eyes (4.3%).

Difference in Fluorescein Leakage by Age

Changes in fluorescein leakage by age are shown in Table 4. In subjects under 50 years of age (30 cases), only one case of fluorescein leakage was seen in the pupillary margin and leakage in the angle was seen in 4 cases. On the other hand, in subjects over 50 years of age (62 cases), fluorescein leakage was seen only in the pupillary margin in 12 cases (19.4%), only in the angle in 20 cases (32.3%), and in both sites in 18 cases (29%).

The extent of leakage is shown in Figure 4. It was recognized that in both the iris and angle, marked fluorescein leakage (grades III and IV) was seen in subjects over 50 years old.

Case Reports

Case 1. A 52-year-old man had no fluorescein leakage in either the pupillary margin or in the angle as observed by FIAP (Figure 5).

Case 2. A 45-year-old man showed fluorescein leakage in the angle but not in the pupillary margin by FIAP. The angle vessel was also visible by CIAP (Figure 6).

Table 3. Incidence of Goniovessels Without Fluorescein Leakage

Age	No. of Eyes	Percentage
20-49	8/30	27%
50+	17/62	27%
Total	25/92	27%

Discussion

Henkind reported on the gonioscopic appearance of the anterior chamber angle in 265 normal eyes and reported that goniovessels were found in 62% of blue-eyed and in 9% of brown-eyed individuals.⁵ Fluorescein angle photography was also conducted by Ishigouoka et al⁴ and by Kimura.³ In brown eyes, Ishigouoka et al⁴ carefully observed the vessels in the angle by FIAP, and they concluded that vessels

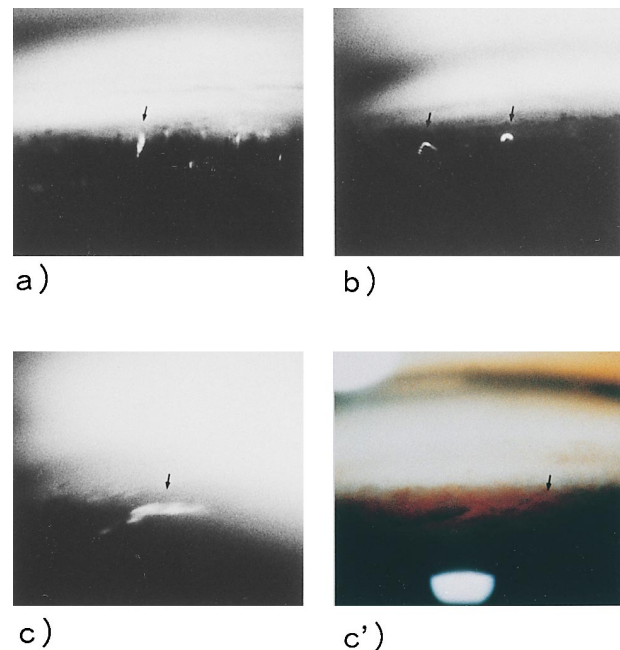


Figure 3. Representative photographs by FIAP of fluorescein filling of goniovessels. (a) Radial ciliary body or trabecular vessel of 57-year-old woman exhibiting linear-shaped fluorescein filling in anterior chamber angle at 6 o'clock (arrow). (b) Radial iris vessels of 89-year-old woman demonstrating hook-shaped fluorescein filling in anterior chamber angle at 6 o'clock (arrows). (c) Circular ciliary band vessel in 54-year-old man showing bow-shaped fluorescein filling in anterior chamber angle at 9 o'clock (arrow). (c') Same lesion as shown by color iris and angle photography (CIAP). Arrow indicates circular ciliary band vessel.

Table 4. Location and Incidence of Fluorescein Leakage by Age

Lesion Location	Age Range							Total Leakage Eyes/Location
	20-29	30-39	40-49	50-59	60-69	70-79	80 plus	
Only pupillary margin	0	0	0	1	3	6	2	12 (13%)
Only angle	0	2	1	4	8	8	0	23 (25%)
Angle and pupillary margin	0	0	1	1	6	6	5	19 (21%)
Total eyes with leakage	0	2	2	6	17	20	7	54 (59%)
Total eyes in age range	10	10	10	10	20	24	8	92 (100%)
Percent of eyes with leakage	0%	20%	20%	60%	85%	83%	88%	

detected in the angle by CIAP showed filling but no leakage of fluorescence by FIAP.

In the present study, we found that goniovessels were observed in 27% of the normal subjects (Table 3). This was a much higher incidence than the 9% in brown eyes reported.⁵ Brown eyes have dense pigmentation of the iris that would make it difficult to observe these vessels by gonioscopic examination. With FIAP, detection is easier even in the presence of heavy pigments. The incidence of goniovessels was not significantly different in the age groups under and over 50 years old.

According to Henkind, the circular ciliary band vessels (class III), that are derived from the major arterial circle of the iris were the type most frequently seen by gonioscopy.⁵ However, our observations, showed that ciliary body or trabecular vessels (class I) appeared to be portions of the arterial circle of Schlemm's canal or branches of the deep scleral venous plexus. These latter vessels were seen in 22 of 92 eyes (29.6%). It is unclear why there are these differences between our observations and those of the previous reports. The differences would reflect not only the differences in the investigational methods of FIAP and CIAP, but also interracial factors.

We then investigated the functional alterations of iris and goniovessels with aging. Iris capillaries have well-developed tight junctions with zonulae occludentes. In an electron microscopic study using intravenously injected tracer, it was confirmed that the tracer was blocked by the tight junctions.^{6,7} Previous studies that used fluorophotometry with sodium fluorescein as a tracer revealed that the permeability of the BAB increased significantly with age.⁸ Even in a morphological (light and electron microscopic) study, it was shown that with increasing age, there was a narrowing of the lumen of the iris vessels, an increase of the collagenous tissue, and an enlargement of the basement membrane of the blood vessels.⁹ In our examination by FIAP, only one case of

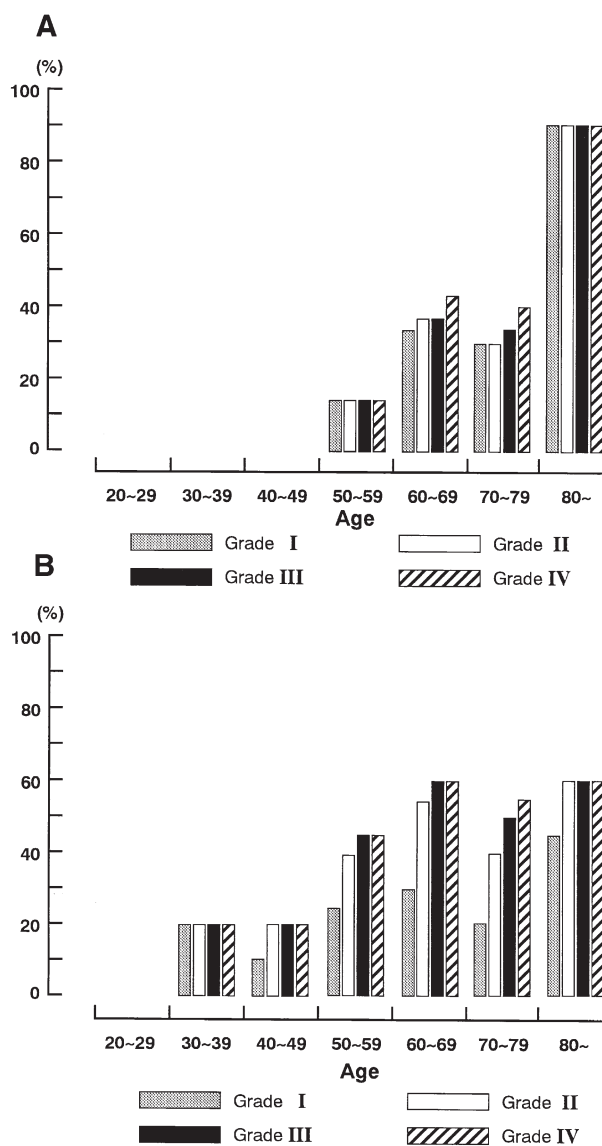


Figure 4. Relationships between age and (A) incidence of different grades of fluorescein leakage in iris and (B) incidence of different grades of fluorescein leakage in anterior chamber angle.

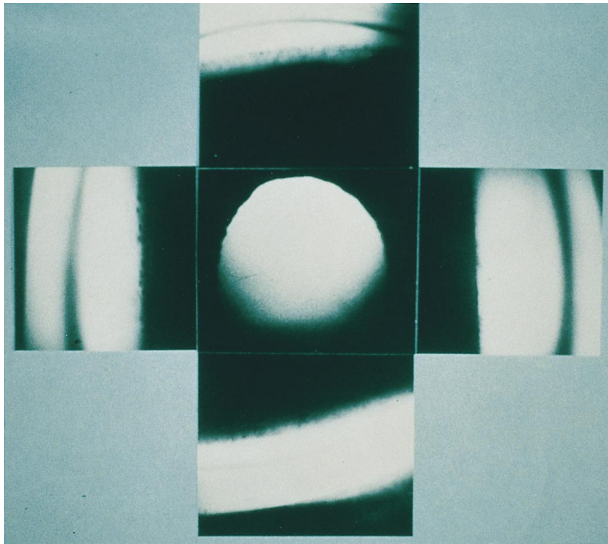


Figure 5. Representative photographs by FIAP. Case 1: pupillary margin (center) or angle (perimeter) of 52-year-old man, showing no fluorescein leakage.

leakage was noted in the pupillary margin in the group under 50 years old, whereas leakage was found in 48% of those over 50 years old. In the angle, fluorescein leakage was seen in only 13% of the cases under 50 years old, whereas it occurred in 61% of those over




Figure 6. Representative photographs by FIAP of fluorescein leakage from anterior chamber angle. Case 2: fluorescein leakage in angle at 3 o'clock (center, right) in 45-year-old man. Simultaneously, goniovessels are seen by CIAP (lower right). Arrows indicate same vessel at angle.

50 years old. Thus, our results also demonstrated a functional deterioration of the BAB with aging.

There were some recent reports on the iris and angle using fluorophotometry^{10,11} and the flare-cell meter.¹²⁻¹⁴ However, there have not been reports on the aging changes in the iris and angle using these techniques. Thus, it would be interesting and important to investigate the aging changes using fluorophotometry and the flare-cell meter. These investigations will provide additional information about the functional changes with age in the iris and angle.

This paper was published in the *Nippon Ganka Gakkai Zasshi (Acta Soc Ophthalmol Jpn)* 1992;96:657-63. It appears here in a modified form after undergoing the peer review and editing processes of the Japanese Journal of Ophthalmology.

References

- Mizuno K. A new multipurpose gonioscopes. *Arch Ophthalmol* 1988;106:1309-10.
- Satoh K, Obtsuki K, Mizuno K. Fluorescein photography of iris and angle. 1. A new method using the Mizuno Trabeculens. *Nihon Ganka Kiyo (Folia Ophthalmol Jpn)* 1987;38:1426-30.
- Kimura R. Fluorescein gonioscopy. *Glaucoma* 1980;2:359-67.
- Ishigouoka H, Asayama K, Ogino M. Gonio-vessels. *Rinsho Ganka (Jpn J Clin Ophthalmol)* 1979;33:78-81.
- Henkind P. Angle vessels in normal eyes. *Br J Ophthalmol* 1964;48:551-7.
- Raviola G. Effects of paracentesis on the blood aqueous barrier: an electron microscope study on *Macaca mulatta* using horseradish peroxidase as a tracer. *Invest Ophthalmol* 1974;13:828-58.
- Kottow MH. Anterior segment fluorescein angiography. Baltimore: Williams & Wilkins, 1978; 6-10.
- Sakanishi Y, Sawa M, Shimizu H. Fluorescein leakage through the blood aqueous barrier (BAB) after cataract surgery. *Rinsho Ganka (Jpn J Clin Ophthalmol)* 1984;38:115-20.
- Kimura T, Okisaka S, Hiwatari S. The aging changes of the peripheral iris-light and electron microscopic study. *Nihon Ganka Kiyo (Folia Ophthalmol Jpn)* 1981;32:2325-33.
- Virno M, Tavemiti L, De Gregorio F, Sedran L, Longo F. Increase in aqueous humor production following DI receptor activation by means of ibopamine. *Int Ophthalmol* 1996;20:141-6.
- Larsson LI, Rettig ES, Brubaker RF. Aqueous flow in open-angle glaucoma. *Arch Ophthalmol* 1995;113:283-6.
- Chin PK, Cuzzani OE, Gimbel HV, Sun R. Effect of commercial dilating agents on laser flare-cell measurements. *Can J Ophthalmol* 1996;31:362-5.
- Kuchle M, Nguyen NX, Horn F, Naumann GO. Quantitative assessment of aqueous flare and aqueous 'cells' in pseudoexfoliation syndrome. *Acta Ophthalmol* 1992;70:201-8.
- Onodera T, Gimbel HV, DeBroff BM. Aqueous flare and cell number in healthy eyes of Caucasians. *Jpn J Ophthalmol* 1993;37:445-51.