

Quantitative Evaluation of “Sunset Glow” Fundus in Vogt–Koyanagi–Harada Disease

Saburosuke Suzuki

*Department of Ophthalmology, Keio University,
School of Medicine, Shinjuku, Tokyo, Japan*

Purpose: To evaluate the color of the fundus quantitatively, especially the “sunset glow” fundus, in patients with Vogt–Koyanagi–Harada (VKH) disease.

Methods: The fundus of 39 patients (13 men and 26 women) who were diagnosed with VKH disease were photographed. The photographs were scanned by a film scanner and the amount of red, green, and blue pixels making up the image was determined by image analyzing software. A “sunset glow” index, the ratio of the number of red pixels to the total number of pixels, was determined for all patients as well as 31 normal controls.

Results: In comparison to the controls, the “sunset glow” indices at 3 months after onset of the “sunset glow” fundus showed significant increases in VKH patients. Six months after onset, the “sunset glow” indices showed further significant increases and continued to increase during the course of the disease.

Conclusions: The depigmentary changes can be found earlier by using our method rather than ophthalmoscopy. Because our method is more sensitive for slight depigmentary changes, the pigmentary changes in the fundus could be found in all the VKH patients. This quantitative evaluation of the fundus makes a correct diagnosis possible even in patients who do not demonstrate the “sunset glow” fundus by normal ophthalmoscopic examinations. **Jpn J Ophthalmol 1999;43:327–333** © 1999 Japanese Ophthalmological Society

Key Words: Quantitative evaluation, sunset glow fundus, uveitis, Vogt–Koyanagi–Harada disease.

Introduction

Vogt–Koyanagi–Harada (VKH) disease is a systemic disorder that involves tissues in many organs (eg, eye, ear, skin, meninges, and hair). VKH disease is thought to be an autoimmune disease directed against the melanocytes in systemic organs, especially the eyes. The most common ocular finding in VKH disease is bilateral granulomatous iridocyclitis with exudative retinal detachment. For diagnosis, the important symptoms are not only the characteristic ocular findings but also the systemic findings of poliosis, dysacusia, alopecia, vitiligo, cerebrospinal fluid pleocytosis, and meningeal symptoms. How-

ever, patients exhibiting the characteristic ocular findings, but who lack the systemic findings are reported as suffering from VKH disease.^{1–3}

In the ocular aspects of VKH disease, the “sunset glow” fundus has been thought to be the most important finding.⁴ Because the Vogt–Koyanagi type (iridocyclitis type) of VKH disease often shows granulomatous iridocyclitis but not exudative retinal detachment, its diagnosis can be done in the convalescent stage. These patients are diagnosed as having VKH disease by the presence of the “sunset glow” fundus that appears 2–6 months after the onset.

In the last two decades, widespread use of high-dose, systemic steroid therapy has changed the clinical features of VKH disease.^{3,5} Many VKH disease patients can be cured and have no severe complications or severe atrophic changes of the fundus and skin. In recent reports,^{3,6} some VKH disease patients did not show the “sunset glow” fundus after high-

Received: December 17, 1997

Correspondence and reprint requests to: Saburosuke SUZUKI, MD, Department of Ophthalmology, Keio University, School of Medicine, 35 Shinanomachi, Shinjuku, Tokyo 160-0016, Japan

dose systemic steroid therapy. Because the color of the fundus depends on race and the individual, the “sunset glow” fundus is a subjective and not an objective diagnostic criterion. Therefore, we have not been able to diagnose patients as having VKH disease if they have no systemic findings at the onset and also do not show the “sunset glow” fundus after high-dose, systemic steroid therapy.

In this report, we make a new attempt to evaluate the color of the fundus quantitatively, especially the “sunset glow” fundus, in patients with VKH disease.

Materials and Methods

We analyzed the records of 39 patients (13 men and 26 women) who were diagnosed with VKH disease at the uveitis clinic of the Keio University Hospital. All patients had the typical bilateral ocular findings of VKH disease as well as cerebrospinal fluid pleocytosis in the acute stage or marked “sunset glow” fundus in the convalescent stage. They met the criteria for Vogt–Koyanagi–Harada disease established in 1977 by the Third Japanese Uveitis Meeting,^{4,7} and also met the criteria established in 1978 by the American Uveitis Society.⁸

Fundus photographs were taken several times with a fundus camera (Kowa RC-W, TRC-50X; Topcon, Tokyo) on slide film (35 mm reversal color film RD ISO 100; Fuji, Tokyo) during the clinical course of their disease. The age at disease onset ranged from 16 to 77 years, the average age was 40.9 years.

All patients were treated with high-dose systemic steroids. The initial dose of steroids (drip infusion of betamethasone 16–20 mg per day) was tapered to oral prednisolone (30 mg per day) for 2 weeks. Then, it was gradually tapered off in 4–6 months. Despite treatment, some of these VKH disease patients showed prolonged inflammation.

Patient fundus slides (35 mm) were scanned by a film scanner (Coolscan; Nikon, Tokyo), and placed in the file of a personal computer (Quadra 800; Apple Computer, Cupertino, CA, USA) (Figure 1). The images were then analyzed by image analyzing software (Photoshop version 3.0; Adobe Systems, Mountain View, CA, USA) under full color conditions (16,400,000 colors). We measured the posterior part of the fundus, which did not contain the optic disc. On the monitor, the fundus images consisted of red, green, and blue components (the RGB images). As shown in Figure 2, we measured the number of red, green, and blue pixels that composed the RGB images of the fundus to determine the “sunset glow”

index (I). This index is the ratio of the number of red pixels to the total number of pixels (red, green, and blue) in a fundus image ($P_{\text{total}} = P_{\text{red}} + P_{\text{green}} + P_{\text{blue}}$): $I = P_{\text{red}}/P_{\text{total}}$.

We compared the “sunset glow” indices of VKH disease patients with the indices we had recorded in normal controls (31 eyes of 31 subjects, 15 men and 16 women, aged 10–77 years, average age = 32.9 years), who had no eye diseases except refractive disorders. We evaluated the “sunset glow” indices for the patients throughout the course of their disease.

In normal controls, the “sunset glow” indices ranged from 0.48 to 0.60, with an average of 0.55. Neither refractive disorders (Figure 3) nor age (Figure 4) significantly affected the “sunset glow” indices of the controls.

Because the distribution of the “sunset glow” indices was not normal, nonparametric methods were used in analysis. Statistical analysis for two independent samples was performed using the Mann-Whitney *U* test. The means and standard errors were calculated to help visualize the data, but were not used in the statistical analysis.

Case Reports

The following two case reports show two typical courses of change in the “sunset glow” indices of the VKH patients.

Case 1

The first case was a 17-year-old woman with moderate iridocyclitis and swelling of the optic disc with exudative retinal detachment surrounding the optic disc in both eyes (Figure 5). Because she showed common cold-like symptoms and cerebrospinal fluid pleocytosis, we diagnosed her as having VKH disease. She was treated with a high-dose of systemic steroids that was tapered over 4 months. After the systemic steroid treatment, we could not find any inflammation in her eyes. Her vision remained 1.2 in both eyes. However, her “sunset glow” indices gradually increased over the follow-up period of 2 years after her initial treatment. Figure 5 shows the relationship between the photographs and the “sunset glow” indices. Her “sunset glow” indices continued to increase during the course of her disease.

Case 2

A 23-year-old man showed granulomatous iridocyclitis with exudative retinal detachment in both

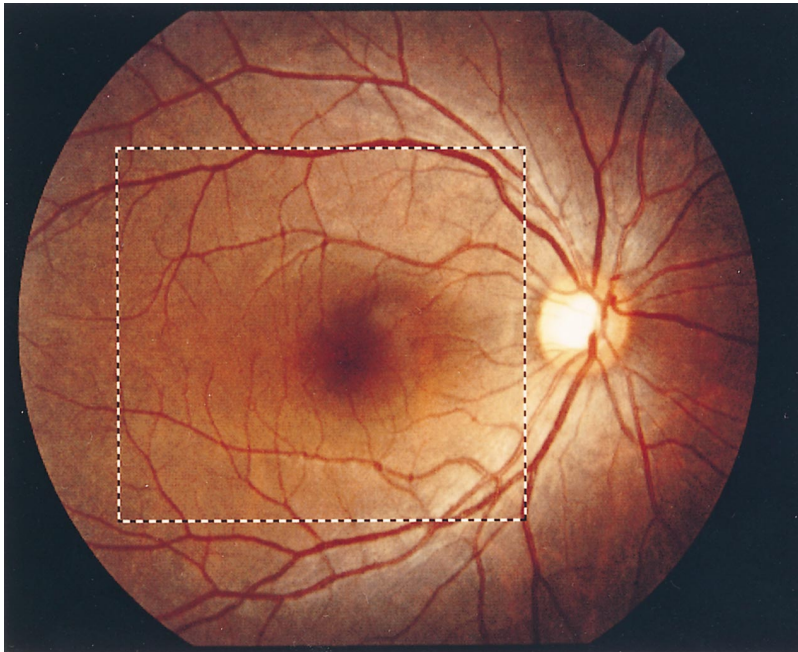


Figure 1. Fundus photograph scanned and displayed on monitor. Area surrounded by dotted line was measured.

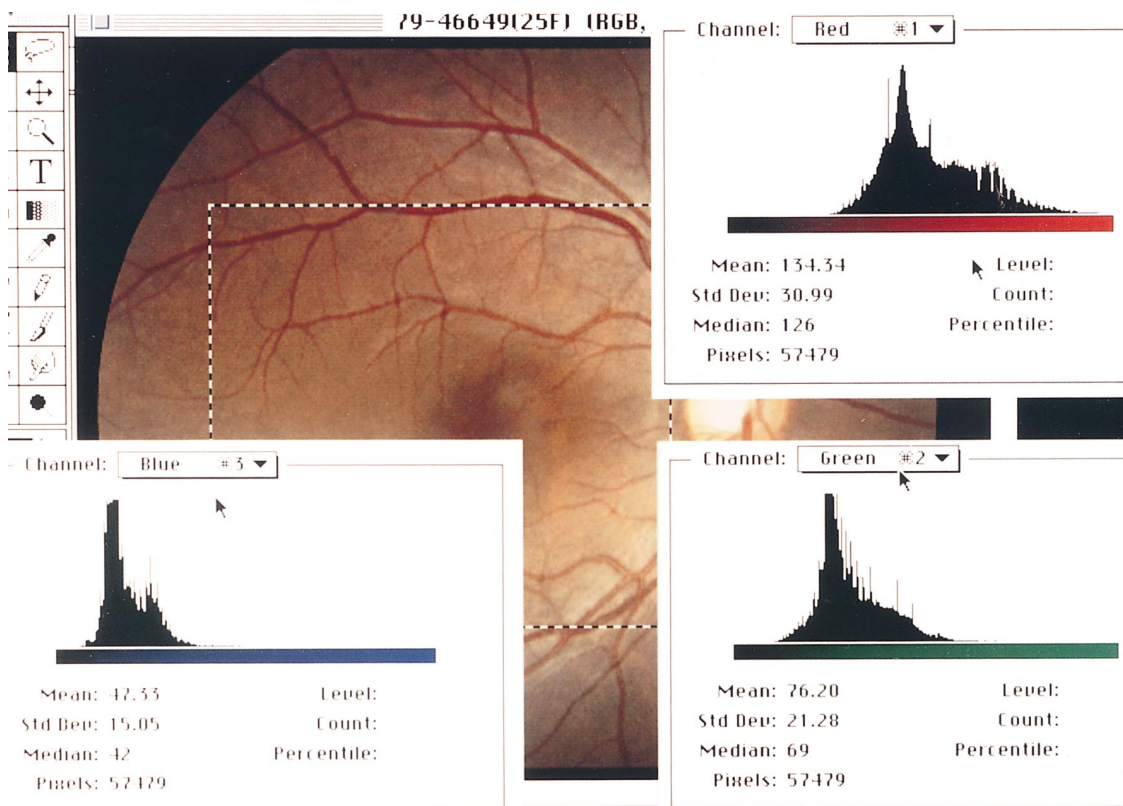


Figure 2. RGB (red, green, and blue) images of fundus are divided into three histograms. In histograms, horizontal bar shows brightness of each color. Below each histogram, mean, standard deviation, median, and total number of pixels for each color are shown. This figure is the mean of three measurements.

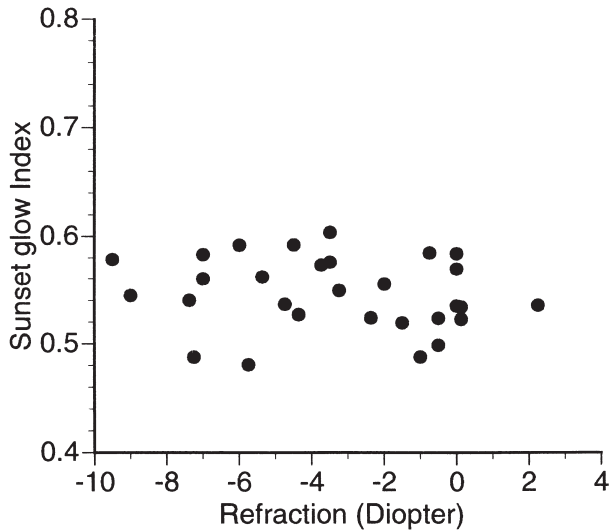


Figure 3. Relationship between “sunset glow” index and refraction in normal controls.

eyes, but without swelling or hyperemia of the optic disc (Figure 6). He was treated with a high dose of systemic steroids. After 6 months of steroid therapy, the ocular inflammation disappeared. His “sunset glow” indices increased in the first month, and remained at the same level during his 4-year follow-up.

Results

The “sunset glow” indices of all the patients with VKH and their disease courses are shown in Figure 7. In comparison with those of normal controls (Fig-

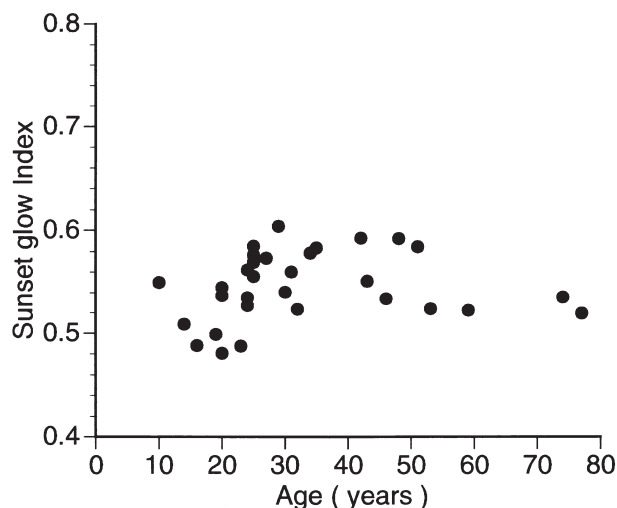


Figure 4. Relationship between “sunset glow” index and age in normal controls.

ure 7, top row of asterisks), the “sunset glow” indices of patients did not show significant increases at 1 month. Three months after onset, there were statistically significant increases in the “sunset glow” indices of all VKH patients. As compared with the stage (Figure 7, bottom row of asterisks) at which the exudative retinal detachments disappeared (1 M = 1 month after onset), the “sunset glow” indices at onset and those at 3 months after onset did not show statistical differences. However, 6 months after onset, the “sunset glow” indices showed statistically significant increases and continued to increase during the course of the disease.

Figure 8 shows the course of the different types of VKH disease. In the Harada type patients (open symbols) who were treated with high-dose, systemic steroid therapy and were cured without prolonged inflammation, “sunset glow” indices increased in the first 2 months, but then reached a plateau 2 months after onset. In other patients with the Harada type and peripapillary edema type (filled symbols), the inflammation persisted in spite of high-dose, systemic steroid therapy. Their “sunset glow” indices were relatively high at the beginning of treatment and gradually increased during the study.

We measured the “sunset glow” indices of bilateral posterior scleritis patients. These patients were initially difficult to distinguish from VKH disease patients because their ophthalmological findings were compatible with VKH disease, even though they had no systemic findings. They were treated with relatively low doses of steroid (6 mg of betamethasone) and their exudative retinal detachment and inflammation disappeared immediately. Their “sunset glow” indices did not show any increase during the course of their disease (data not shown).

Discussion

The diagnostic criteria for VKH disease is still debated, especially when patients have neither systemic symptoms nor “sunset glow” fundus in the convalescent stage.^{6,9} In this study, all VKH patients were diagnosed by cerebrospinal fluid pleocytosis in the acute stage or by marked “sunset glow” fundus with retinal pigment epithelial cell loss and Dalen-Fuchs nodules in the convalescent stage. It is difficult to diagnose uveitis patients with VKH disease without systemic findings in the acute stage, and an accurate diagnosis cannot be made without the “sunset glow” fundus.

About 20% of VKH patients lack systemic symptoms. Ohno et al¹⁰ reported that 84% of the cases

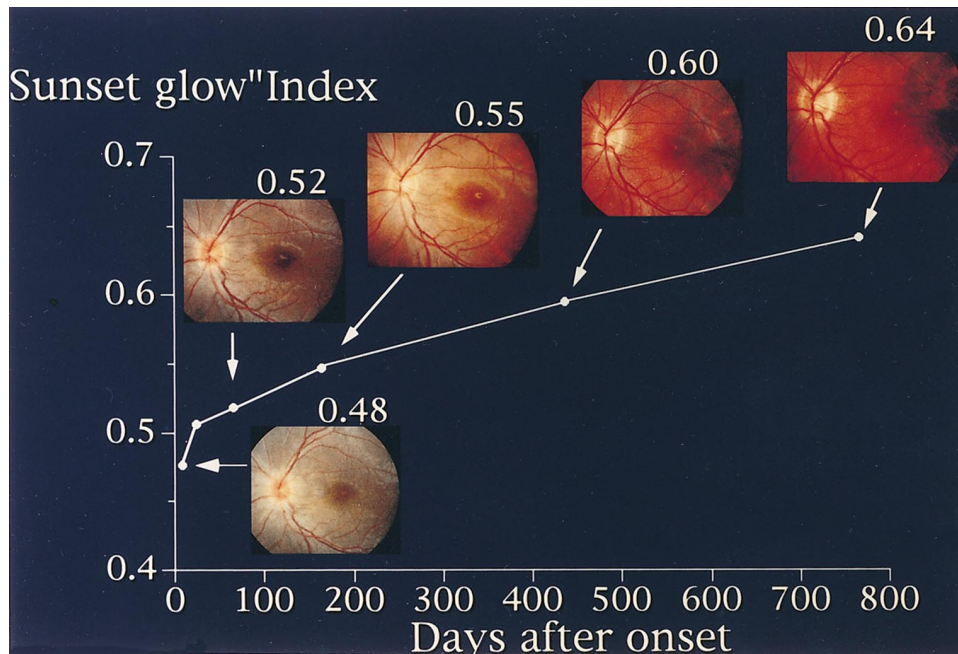


Figure 5. Fundus photographs and "sunset glow" indices of Case 1 (see text).

showed cerebrospinal fluid pleocytosis and 74% of the cases showed dysacusia during the course of VKH disease. In addition, Beniz et al³ reported finding even fewer extraocular findings in VKH disease

cases. In these patients, it was initially difficult to distinguish VKH disease from posterior scleritis and some retinal pigment epithelial disorders until the "sunset glow" fundus appeared in the convalescent

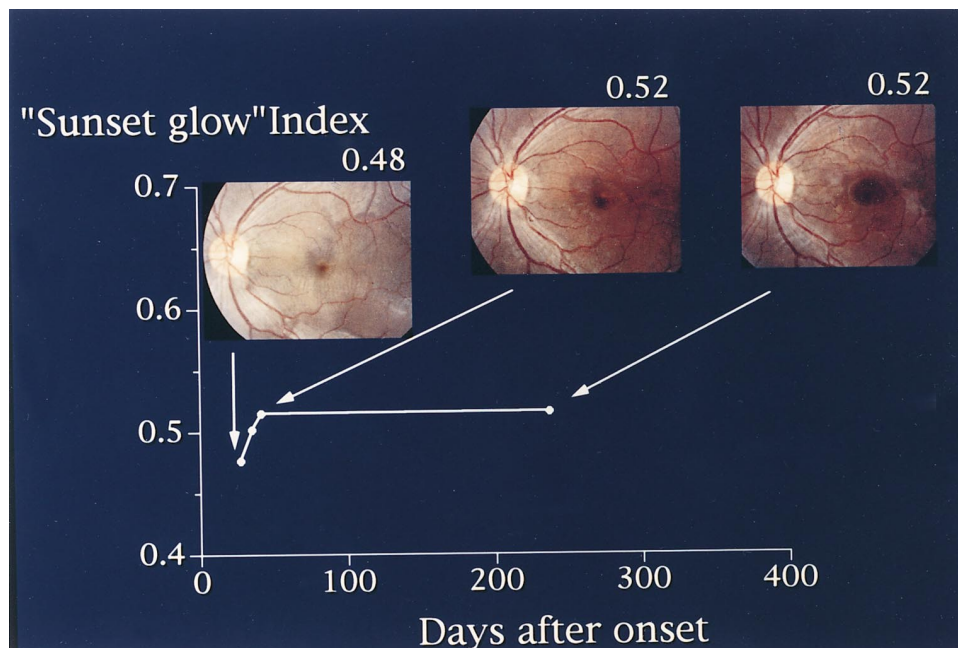


Figure 6. Fundus photographs and "sunset glow" indices of Case 2 (see text).

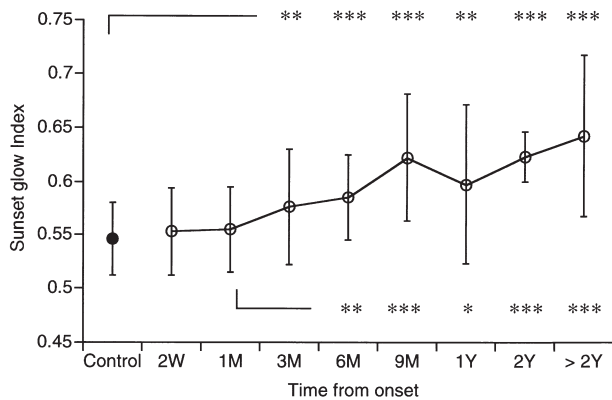


Figure 7. Means and standard deviations of “sunset glow” indices of VKH patients at each stage. Top row of asterisks indicates statistically significant increases between VKH disease and normal controls. Bottom row of asterisks indicates statistically significant increases between each stage of VKH patients and the stage in which exudative retinal detachment disappeared. Number of asterisks indicates *P* value of Mann-Whitney *U* test. **P* < .05, ***P* < .01, ****P* < .001.

stage. Whereas echographic findings are useful for the diagnosis of VKH disease, the findings are also very similar to those of the patients of posterior scleritis.^{11,12}

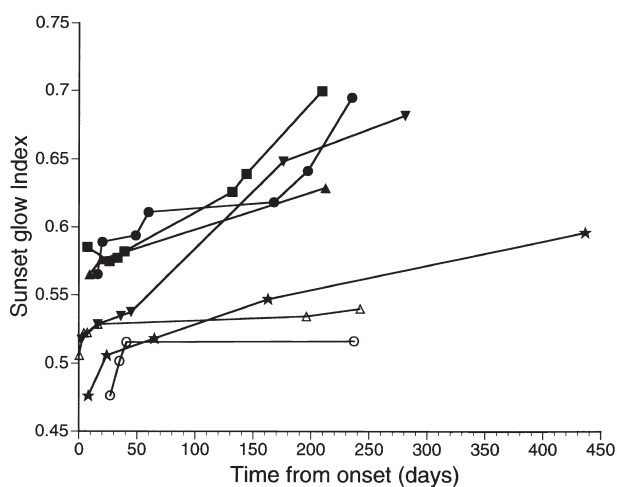


Figure 8. Courses of “sunset glow” indices in typical VKH disease patients in this study. Star symbols (★) show “sunset glow” indices of peripapillary edema type (Case 1). Open symbols (△, ○) and closed symbols (★, ▲, ▼, ●, ■) show the “sunset glow” indices for the Harada type. Cases of filled symbols showed prolonged inflammation in spite of high-dose systemic steroid therapy.

VKH disease is classified into three types: (1) the Vogt-Koyanagi type (or iridocyclitis type) with granulomatous iridocyclitis but no exudative retinal detachment; (2) the Harada type with posterior exudative retinal detachment; and (3) the peripapillary edema type with optic disc swelling and/or exudative retinal detachment surrounding the optic disc.¹³ In patients of the Vogt-Koyanagi type who have granulomatous iridocyclitis with or without systemic symptoms, it is often difficult to diagnose the disease as VKH. The “sunset glow” fundus, which appears 2–6 months after onset, can confirm the diagnosis in this type of patients. In the Harada and the peripapillary edema type of patients, the typical ocular findings such as bilateral exudative retinal detachment and optic disc swelling with granulomatous iridocyclitis make their diagnosis easier than in the Vogt-Koyanagi type in the acute stage.

Of all the ocular and extraocular findings, the “sunset glow” fundus is thought to be the most important. High-dose, systemic steroid therapy should be started within 10 days from disease onset.¹³ High-dose, systemic steroid therapy has changed the clinical features of VKH disease. This treatment not only cures VKH disease in many patients without severe complications but also reduces the severity of the atrophic ocular changes and depigmentation in the eyes and in the systemic organs. Ohno et al¹⁰ reported that only 64% of the cases showed depigmentation of the ocular fundus during the course of VKH disease. In a recent report, some of the VKH disease patients did not show “sunset glow” fundus after high-dose, systemic steroid therapy.⁶

In our study, all “sunset glow” indices in the VKH disease patients gradually increased during the course of their disease. The “sunset glow” fundus is a depigmentary change in melanocytes in the choroid that appears 2–6 months after VKH disease onset. The fundus pigmentation is variable even among normal individuals, and in its subjective evaluation by ophthalmoscopy, the fundus picture fails to provide a quantitative assessment.

The “sunset glow” indices we have calculated may provide far better assessment because they quantify the variable fundus pigmentation in normal individuals for comparison. Using these “sunset glow” indices, we were able to determine that some patients showed an increase in “sunset glow” within 2 months after disease onset. Because our method could detect slight depigmentary changes, the pigmentary changes in the fundus could be found in all VKH patients in this study. Furthermore, the greater sensitivity of our method makes it possible to diag-

nose VKH in patients who do not demonstrate the "sunset glow" fundus in normal ophthalmoscopic examinations.

In some of our cases, the anterior and posterior inflammatory findings completely disappeared after systemic steroid treatment. However, the "sunset glow" indices continued to increase after the treatment. This finding suggests that the patients with clinically silent VKH disease still have an active immune response against melanocytes and inflammatory cells in the uvea.^{14,15}

In the treatment of VKH disease, it is most important to start a high-dose, systemic steroid therapy as soon as possible, preferably within 10 days of onset of disease.¹³ However, treatment depends on the severity of ocular and extraocular symptoms. In spite of high-dose, systemic steroid therapy, some VKH disease patients have shown prolonged inflammation in eyes and systemic organs. Steroid treatment is less effective on the Vogt-Koyanagi type than on the Harada type of VKH disease.¹⁶ The patients with the Vogt-Koyanagi type tended to visit our clinic later in the course of their disease because of their milder ocular and systemic symptoms. In these cases, the time of onset was difficult to determine. Patients whose indices were relatively high showed prolonged inflammation in spite of high-dose, systemic steroid therapy. This may suggest that other immunosuppressive treatment or combined steroid treatment should be tried.

This is a preliminary report about the quantitative evaluation of the "sunset glow" fundus. It could also evaluate the color image of the fundus in other diseases. This method is very easy and does not depend on the quality of the fundus photographs because brightness and darkness do not affect the RGB images. This method can be an important diagnostic criterion of VKH disease, and as such can prove useful in the quantitative evaluation of the "sunset glow" fundus and the effectiveness of its treatment.

References

1. Perry HD, Font RL. Clinical and histopathologic observations in severe Vogt-Koyanagi-Harada syndrome. *Am J Ophthalmol* 1977;83:242-54.
2. Yoshioka H, Iwami H. Vogt-Koyanagi-Harada disease without extraocular findings. *Nihon Ganka Kiyo (Folia Ophthalmol Jpn)* 1984;35:2580-4.
3. Beniz J, Forster DJ, Lean JS, Smith RE, Rao NA. Variations in clinical features of the Vogt-Koyanagi-Harada syndrome. *Retina* 1991;11:275-80.
4. Mimura Y. Survey of etiology and diagnosis of Harada's disease. *Nihon Ganka Kiyo (Folia Ophthalmol Jpn)* 1984;35:2676-83.
5. Sasamoto Y, Ohno S, Matsuda H. Studies on corticosteroid therapy in Vogt-Koyanagi-Harada disease. *Ophthalmologica* 1990;201:162-7.
6. Mimura Y. New criteria for Vogt-Koyanagi-Harada disease without sunset glow fundus. *Nihon Ganka Kiyo (Folia Ophthalmol Jpn)* 1991;42:715-8.
7. Sugiura S. Vogt-Koyanagi Harada disease. *Jpn J Ophthalmol* 1978;22:9-35.
8. Snyder DA, Tessler HA. Vogt-Koyanagi-Harada syndrome. *Am J Ophthalmol* 1980;90:69-75.
9. Asai K, Bando Y, Mimura Y, Bando K, Yuasa T. Harada's disease unaccompanied by fundus depigmentation. *Rinsho Ganka (Jpn J Clin Ophthalmol)* 1985;39:133-7.
10. Ohno S, Minakawa R, Matsuda H. Clinical studies of Vogt-Koyanagi-Harada's disease. *Jpn J Ophthalmol* 1988;32:334-43.
11. Forster DJ, Cano MR, Green RL, Rao NA. Echographic features of the Vogt-Koyanagi-Harada syndrome. *Arch Ophthalmol* 1990;108:1421-6.
12. Michimata R, Nagao K, Yuzawa M, Matsui M. A case of Harada's disease associated with posterior scleritis. *Rinsho Ganka (Jpn J Clin Ophthalmol)* 1990;44:539-42.
13. Mimura Y, Asai K, Yuasa T, Hara Y, Bandoh K. Studies of diagnosis and treatment of Vogt-Koyanagi-Harada's disease. *Nihon Ganka Kiyo (Folia Ophthalmol Jpn)* 1984;35:1900-9.
14. Chan CC, Palestine AG, Kuwabara T, Nussenblatt RB. Immunopathologic study of Vogt-Koyanagi-Harada syndrome. *Am J Ophthalmol* 1988;105:607-11.
15. Inomata H, Sakamoto T. Immunohistochemical studies of Vogt-Koyanagi-Harada disease with sunset sky fundus. *Curr Eye Res* 1990;9(suppl.):35-40.
16. Hayasaka S, Okabe H, Takahashi J. Systemic corticosteroid treatment in Vogt-Koyanagi-Harada disease. *Graefes Arch Clin Exp Ophthalmol* 1982;218:9-13.