

# Therapeutic Keratoplasty Using Preserved Corneas From Keratoconus Eyes

Shin Goto, Akiko Fukuhara and Hideyo Miyasaka

*Department of Ophthalmology, Teikyo University School of Medicine, Tokyo, Japan*

---

**Purpose:** To report and discuss cases of lamellar keratoplasty using corneas obtained during previous penetrating keratoplasty in keratoconus eyes.

**Methods:** Corneal buttons were obtained from 7 keratoconus patients and stored in a preserving solution for 7–60 days (average, 32.4 days) before use. The recipient eyes comprised recurrent pterygium 3 eyes, primary pterygium 1 eye, pseudopterygium 1 eye, corneal perforation with iris prolapse due to fungal corneal ulcer 1 eye, and limbal dermoid 1 eye.

**Results:** The recipient eyes ran favorable courses in general. Graft rejection developed in 2 eyes and was successfully treated with topical and systemic corticosteroid.

**Conclusions:** Preserved corneas from keratoconus eyes were found useful in therapeutic lamellar keratoplasty. By this procedure, the current inadequate supply of donor corneas in eye banks in Japan can be augmented. **Jpn J Ophthalmol 1999;43:517–521** © 1999 Japanese Ophthalmological Society

**Key Words:** Donor cornea from keratoconus eyes, eye bank, storage of donor corneas, therapeutic lamellar keratoplasty.

---

## Introduction

Currently, it is difficult to obtain fresh corneas for keratoplasty in Japan. It may be possible to use a cornea obtained during another keratoplasty as a donor cornea in a domino pattern. Such an attempt<sup>1</sup> was made in which deep lamellar keratoplasty was successfully performed to treat macular dystrophy using a corneal button obtained from an eye with bullous keratopathy.

Similarly, we have used corneas from keratoconus eyes obtained during penetrating keratoplasty. These donor corneas had been preserved for eventual therapeutic lamellar keratoplasty as an emergency procedure. The recipient eyes included those with corneal perforation and severe corneoconjunctival burns, among others.

Use of keratoconus cornea for another keratoplasty may be a new and promising method for augmenting the currently inadequate supply of donor corneas in eye banks in Japan.

## Materials and Methods

Seven patients (7 eyes) were treated by therapeutic lamellar keratoplasty in the current series. There were 3 patients with recurrent pterygium who had undergone 3, 4, and 5 resections, respectively. One patient had pterygium bilaterally: primary affection in 1 eye, and in the contralateral eye, three recurrences necessitating surgery. One patient each had pseudopterygium, corneal perforation with iris prolapse resulting from fungal corneal ulcer, and limbal dermoid. The patients ranged in age from 9 to 72 years (average, 48 years).

The donor corneas had been obtained from keratoconus patients during penetrating keratoplasty (PKP). The donors ranged in age from 20 to 63 years (average, 34 years). Only 1 eye, used for keratoepithelioplasty (KEP) (case 1), had a history of acute hydrops. The resected donor corneas were either 7.0 or 7.5 mm in diameter. They had been preserved in a sclerocorneal solution (Optisol™-GS; Chiron Vision, Irvine, CA, USA) at 4°C.

The preservation solution and the stored cornea were tested by bacterial/fungal culture 1 week before surgery. All specimens were found to be negative.

---

Received: November 4, 1998

Correspondence and reprint requests to: Shin GOTO, MD, Department of Ophthalmology, Teikyo University School of Medicine, 2-11-1 Kaga, Itabashiku, Tokyo 173-8505, Japan

After a thorough explanation and discussion of the nature of the planned procedure, signed informed consent was obtained from all donors and recipients.

The stored corneas were then used for lamellar keratoplasty (LKP) or KEP. The duration of storage ranged from 7 to 60 days (average, 32.4 days). Donor corneas for LKP were abraded to achieve a consistent thickness (to match the thinnest vertex area). The thicker stromal layer was removed at the peripheral corneal zone because of the thinning of the vertex area in keratoconus eyes. For KEP, a crescent-shaped lenticle was sutured onto the limbal sclera of the recipient. In both instances, utmost care was taken not to damage the epithelium of the donor cornea.

All operated eyes were fitted with therapeutic soft contact lenses (SCL) until reepithelization. Oral prednisolone was given to all patients in a tapering dosage of 20 or 30 mg/day during the first postoperative month. Fluorometholone and ofloxacin eye drops were also used postoperatively for 2-3 months. Fibronectin and cyclosporin (in 1% olive oil solution) eye drops were given for 1 postoperative month. Systemic cyclosporin (100 mg/day, or sufficient to maintain blood trough level 50-100 ng/mL) was additionally used in 2 cases (cases 3 and 4) who had a history of corneal infection.

## Results

The profiles and the clinical course of the 7 cases are shown in tabulated form (Table 1). In all cases, the donor corneal epithelia did not adhere well upon initial application. This tendency was more pro-

nounced in cases receiving corneas with longer storage time. It took 4-33 days, average 11.7 days, for reepithelization to be complete. In all cases except case 2, recovery was completed within 2 weeks.

Figure 1 shows the pre-, intra-, and postoperative findings in case 3. Pre- and postoperative findings in cases 4, 5, and 6 are shown in Figures 2-4, respectively. The grafted cornea became clear immediately after LKP in cases 3, 4, and 6 (Figure 1B, 1C). There was no recurrence of pterygium or pseudopterygium in 5 cases (cases 1, 2, 4, 5, and 7). The ulcer and inflammation of the ocular surface disappeared quickly after surgery in case 3, who had corneal perforation with iris prolapse resulting from fungal corneal ulcer. Remarkable cosmetic improvement could be seen on day 2 of surgery in the patient (case 6) with limbal dermoid. Stromal rejection of the graft occurred at day 62 or 120 after surgery in cases 2 and 3, respectively. The rejection in both cases subsided after topical and systemic corticosteroid treatment.

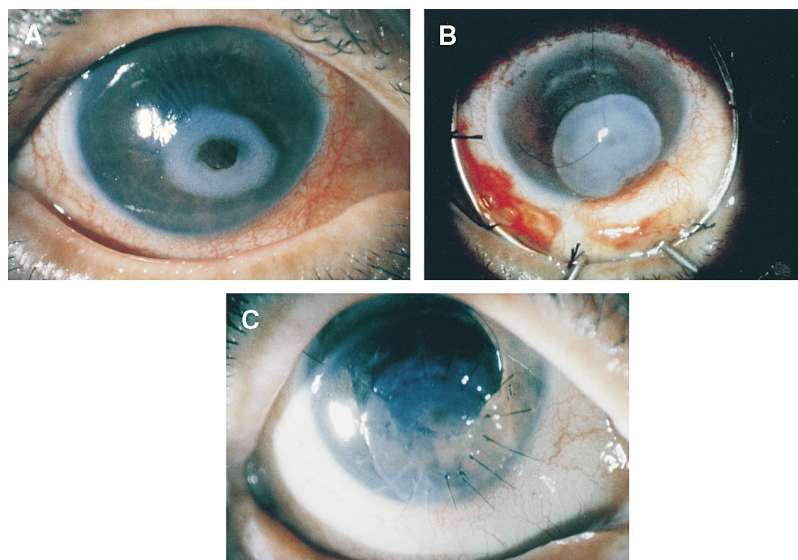
## Discussion

In all 7 cases in the present series, corneas from keratoconus eyes were successfully used for lamellar keratoplasty after preservation in Optisol™-GS for 1-8 weeks. Preserving corneas by storage in glycerin or in a frozen state may induce death of the cell constituents. Previous reports<sup>2,3</sup> have shown that donor corneas preserved in Optisol™ can be used in the clinic, in the same manner as fresh corneas, for up to 2 weeks. However, data are incomplete for corneas preserved beyond 2 weeks. Unlike healthy donor corneas, it is not appropriate to use corneas from

**Table 1.** Results of Therapeutic Keratoplasty Using Corneas Obtained From Keratoconus Patients

Case No.	Age (y)	Gender	Corneal Disorders	Operative Method	Donor Cornea (Keratoconus)			Postop Recovery of Epithelium (days)	Follow-up Period (Months)
					Age	Gender	Days Preserved		
1	40	F	Recurrent pterygium (twice)	KEP	63	F	23	14	33
2	38	M	Recurrent pterygium (four times)	KEP	20	M	7	33	22
3	68	F	Corneal ulcer perforation	LKP	45	F	35	4	15
4	72	M	Recurrent pterygium (three times)	LKP	25	M	22	10	9
5	42	F	Primary pterygium	KEP	20	M	59	5	9
6	9	F	Limbal dermoid	LKP	20	M	21	10	8
7	67	M	Pseudopterygium	KEP	44	M	60	6	6

F: female, M: male, KEP: keratoepithelioplasty, LKP: lamellar keratoplasty.



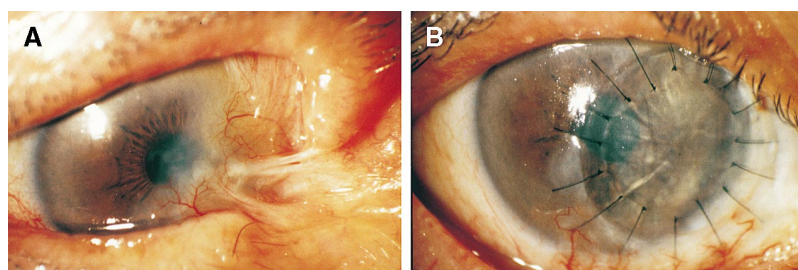
**Figure 1.** Case 3, fungal corneal ulcer, right eye. (A) Slit-lamp finding at initial examination. Corneal ulcer and perforation with iris prolapse developed after extracapsular cataract extraction and intraocular lens implantation at another clinic. Visual acuity: 20 cm/FC. Keratomycosis was suspected from clinical findings. Patient was treated with therapeutic soft contact lens and antifungal medication. Cornea, which had been preserved for 1 month before this patient's admission and was taken from a keratoconus patient, was prepared for emergency keratoplasty. (B) Intraoperative finding (1 week after admission). Lamellar keratoplasty, 7 mm in diameter, was performed after inflammation had subsided. Donor cornea, preserved for 5 weeks, had developed notable edema and opacity. (C) Slit-lamp finding 2 weeks after operation. Edema and opacity on graft quickly cleared from day after surgery because of compression effect. Ulcer and accompanying inflammation disappeared rapidly. Fifteen months after surgery, visual acuity improved to 0.1.

keratoconus eyes in PKP even if the preservation period is less than 2 weeks. The term “relatively fresh cornea” is therefore used to describe the donor corneas in the ensuing discussions.

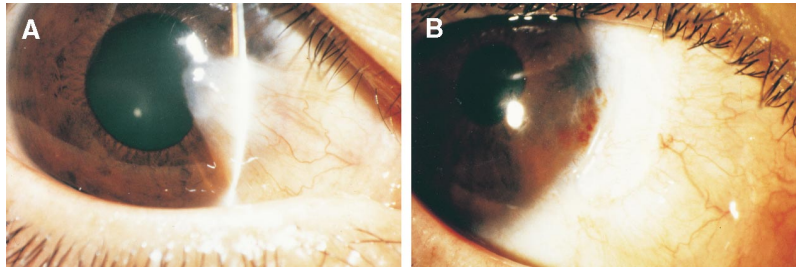
There is a significant advantage in using corneas from keratoconus eyes compared with those from fresh donor patients, namely, the ready availability of donor corneas in emergency situations. Results in

the present series indicate that relatively fresh corneas can be used for therapeutic lamellar keratoplasty after a storage period of up to 2 months. This method was particularly successful in case 3, which had a corneal ulcer and perforation needing urgent treatment.

Lamellar keratoplasty and KEP are recommended for recurrent and primary pterygium and limbal der-



**Figure 2.** Case 4, recurrent pterygium, right eye. (A) Preoperative slit-lamp finding. Patient underwent three operations at another clinic 10 years earlier. This was his fourth operation for recurrent pterygium/symblepharon on the nasal side. Lamellar keratoplasty 7 mm in diameter was performed using donor cornea preserved for 3 weeks. Autoconjunctival flap taken from healthy upper bulbar conjunctiva was transplanted to defective area of bulbar conjunctiva. Defect was caused by pterygium excision and symblepharon ablation. (B) Slit-lamp finding 2 months after operation. Opacity in deep layers of cornea had been excised and graft had remained transparent. There has been no recurrence of pterygium for 9 months after surgery.



**Figure 3.** Case 5, primary pterygium, right eye. (A) Preoperative slit-lamp finding. Pterygium had recurred twice on contralateral eye, and third operation required keratoepithelioplasty (KEP) using fresh cornea. Crescent-shaped lenticle made from donor cornea preserved for 8 weeks was used in KEP. (B) Slit-lamp finding 3 weeks after surgery. Progression of pterygium tissue to cornea was prevented by lenticle. There has been no recurrence of pterygium for 9 months after surgery.

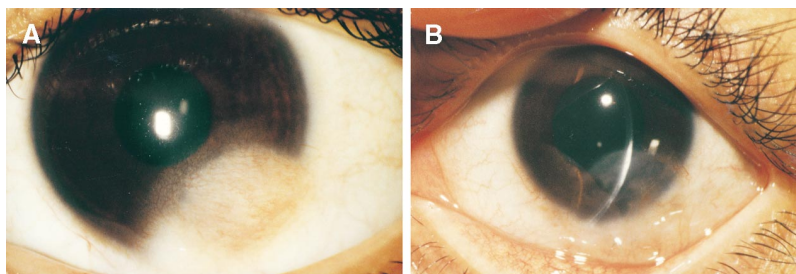
moid, which may recur or may develop pseudopterygium after a simple resection.<sup>4,5</sup> There are also clinical reports<sup>6,7</sup> showing that preserved corneas are as effective as fresh corneas in creating a barrier effect and suppressing inflammation. The results of these reports on preserved corneas are compatible with those of our 6 cases (patients with recurrent or primary pterygium, pseudopterygium, and limbal dermoid).

Other advantages of our method include: availability of cost-free donor cornea, lower antigenicity of the donor cornea after preservation, lesser risk of immune reaction to the graft, and lesser susceptibility to biological contamination when compared with donor cornea obtained postmortem. The rate of postoperative rejection is higher with fresh corneas than with preserved corneas, even after therapeutic keratoplasty.<sup>8,9</sup> Signs of graft rejection developed in 2 of our 7 cases but were quickly treated by topical and systemic corticosteroid. This can be attributed to the lowered antigenicity of the donor cornea preserved for an intermediate term.

The possibility of biological contamination in the present method is extremely low, as the entire procedure, from obtaining the cornea during PKP on the keratoconus eye until the actual lamellar keratoplasty, is performed under aseptic conditions in the operating room.

Difficulty may occur in using a corneal button from a keratoconus eye if the central cornea of the donor eye is extremely thin. We tried to avoid this problem by not using such eyes. Also, it is not suitable to use thin corneas for eyes with corneal ulcer or perforation that require LKP of sufficient thickness.

For the present, it is desirable that the use of corneas from keratoconus eyes be restricted to LKP or KEP. This caution is based mainly on the still unclarified cause of keratoconus.<sup>10</sup> In addition, recent studies show higher-than-normal levels of lysosomal enzyme activity and decrease of  $\alpha$ 1-proteinase inhibitor in keratoconus corneas.<sup>11,12</sup> Further, it is necessary to watch for long-term postoperative complications that may result from such donor corneas.



**Figure 4.** Case 6, limbal dermoid, left eye. (A) Preoperative slit-lamp finding. Limbal dermoid 6 mm in diameter on inferotemporal corneal limbus was removed. Underlying layer was resected by half-layer incision of sclera and cornea. With a trephine 6.5 mm in diameter, lamellar keratoplasty was then performed using donor cornea that had been preserved for 3 weeks. (B) Slit-lamp finding 4 months after surgery. Remarkable cosmetic improvement was seen beginning day after surgery. Preoperative visual acuity of 10/20 was maintained. Neovascularization, which developed at the 5-7 o'clock position 8 months after surgery has remained stationary. Postsurgical course has been uneventful.

We conclude that corneas obtained from keratoconus eyes and preserved in Optisol™ for 1–8 weeks can be used in therapeutic lamellar keratoplasty. Using preserved corneas in the present patients, we achieved favorable anatomical and visual improvements. We have shown that preserved corneas can be effective substitutes for fresh donor corneas.

### References

1. Kurata N, Kazusa R, Tetsumoto K, et al. Deep lamellar keratoplasty using donor cornea from bullous keratopathy. *Atarashii Ganka (Jpn J Eye)* 1998;15:1273–6.
2. Kaufman HE, Beurman RW, Steinemann TL, et al. Optisol corneal storage medium. *Arch Ophthalmol* 1991;109:864–8.
3. Lass JH, Bourne WM, Musch DC, et al. A randomized, prospective, doublemasked clinical trial of Optisol vs DexSol corneal storage media. *Arch Ophthalmol* 1991;110:1404–8.
4. Yamaguchi T, Ohkoshi K, Matsuba H, et al. Modified keratoepitheloplasty for recurrent pterygium. *Nihon Ganka Kyo (Folia Ophthalmol Jpn)* 1989;40:835–9.
5. Nagae Y, Kinoshita S, Shimomura Y, et al. Peripheral lamellar keratoplasty in limbal dermoid. *Rinsho Ganka (Jpn J Clin Ophthalmol)* 1987;41:69–72.
6. Kokawa N, Nishida K, Yokoi N, et al. Keratoepitheloplasty using donor cornea without epithelium for treatment of marginal corneal ulcer. *Atarashii Ganka (Jpn J Eye)* 1995;12:1151–3.
7. Sai Y, Watanabe H, Kiritoshi A, et al. A case of lamellar keratoplasty for pseudopterygium using preserved cornea. *Atarashii Ganka (Jpn J Eye)* 1995;12:1420–2.
8. Yamada M, Mashima Y, Murata H, et al. Therapeutic lamellar keratoplasty for perforated corneal ulcer. *Atarashii Ganka (Jpn J Eye)* 1988;5:463–7.
9. Killingsworth DW, Stern GA, Driebe WT, et al. Result of therapeutic penetrating keratoplasty. *Ophthalmology* 1993;100:534–41.
10. Berman ER. Keratoconus. *Biochemistry of the eye*. New York: Plenum Press, 1991:132–4.
11. Sawaguchi S, Yue BYJT, Sugar J, et al. Lysosomal enzyme abnormalities in keratoconus. *Arch Ophthalmol* 1989;107:1507–10.
12. Sawaguchi S, Twining SS, Yue BYJT, et al. Alpha-1 proteinase inhibitor levels in keratoconus. *Exp Eye Res* 1990;50:549–54.