

# Mobility of Hydroxyapatite Orbital Implant Covered With Autologous Sclera

Shin-ichiro Kawai, Tsuneko Suzuki and Katsuhito Kawai

*Department of Ophthalmology,  
Saitama Medical Center, Saitama Medical School, Saitama, Japan*

**Purpose:** To evaluate the mobility of a hydroxyapatite implant covered with autologous sclera from the enucleated globes of patients with severe atrophy of the eyeball or eyelid retraction.

**Methods:** This implant was used in seven patients with phthisis bulbi. We measured the movement of the implant by photographic analysis of the anterior orbit and by using a strain gauge.

**Results:** At 1–3 years after surgery, neither infection nor prolapse of the implant had occurred in any of the patients. The implant remained stable in the orbit; the extraocular muscles sutured to the sclera of the implant were functioning satisfactorily, and the implants showed great conjugate mobility to the ocular movement of the healthy eye. On photographic analysis of the anterior orbit, the adducting efficiency of the implant was  $92.6 \pm 3.3\%$ ; the abducting efficiency was  $85.9 \pm 5.4\%$ ; the supraducting efficiency was  $84.9 \pm 5.6\%$ , and the infraducting efficiency was  $90.9 \pm 3.9\%$ . The mean tugging weight, as determined using a strain gauge, was  $344.2 \pm 29.2$  g for adduction, and  $327.6 \pm 33.4$  g for abduction. These values corresponded to  $90.4 \pm 4.4\%$  and  $89.5 \pm 5.3\%$  of the respective movements of the healthy eye.

**Conclusions:** Fitting an artificial eye to the peg of this implant did not greatly impair the movement of the implant, and its mobility was greater than that of the artificial eye of the controls in which a semi-integrated magnetic implant, previously available, had been used. This new technique makes it possible to wear an artificial eye earlier than with other prosthetic procedures. **Jpn J Ophthalmol 2000;44:68–74** © 2000 Japanese Ophthalmological Society

**Key Words:** Hydroxyapatite, mobility, oculoplastic surgery, orbital implant, phthisis bulbi.

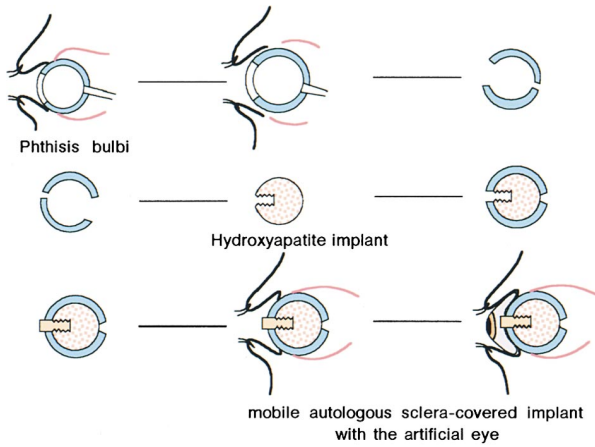
## Introduction

For cosmetic treatment of eyelid retraction after enucleation and evisceration of the eyeball, it is essential not only to correct the tissue defect by inserting an orbital implant, but also to ensure movement of the artificial eye. Semi-integrated magnetic implants and hydroxyapatite implants covered with a grafted sclera and Lyodura® have been developed as implants with imparted mobility.<sup>1–5</sup> However, there

are recent clinical descriptions of extrusion or prolapse of the hydroxyapatite implants, whereas in clinical practice, the use of a magnet and Lyodura® have been shown to involve safety problems.<sup>6–12</sup> On the other hand, many reports on the mobility of the implants available heretofore have dealt with the qualitative evaluation of the movement of the prosthesis and that of the healthy eye, whereas no quantitated analyses have reported on the movement of the implants themselves.<sup>13</sup> To improve the movement of the prosthesis and implant and their biocompatibility with the eye socket for patients with phthisis bulbi, we developed an implant made of hydroxyapatite and covered it with autologous sclera from the enucleated globe. This implant is placed in the orbit and then sutured to the extraocular muscles.

Received: November 16, 1998

Correspondence and reprint requests to: Shin-ichiro KAWAI, MD, Department of Ophthalmology, Saitama Medical Center, Saitama Medical School, 1981, Tsujido, Kamoda, Kawagoe-shi, Saitama 350-8550, Japan

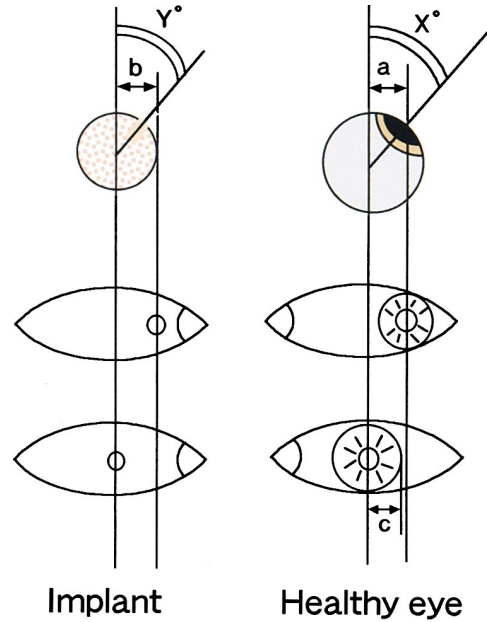


**Figure 1.** Surgical procedure for placing the autologous sclera-covered implant.

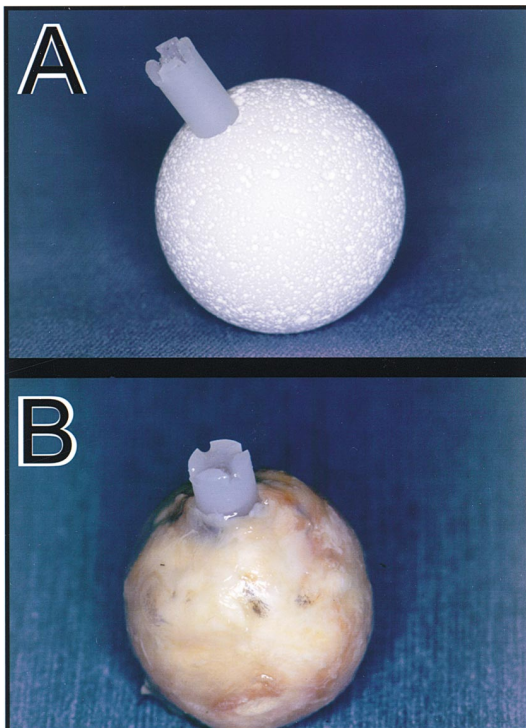
In this study, we examined the autologous sclera-covered implant for intraorbital stability and movement by a photographic analysis of the anterior orbit as well as electrophysiologically by means of a strain gauge, after follow-up for  $1.8 \pm 0.6$  years.

### Materials and Methods

We evaluated seven patients (mean age  $\pm$  SD:  $48.1 \pm 20.2$  years) with severe phthisis bulbi (dura-

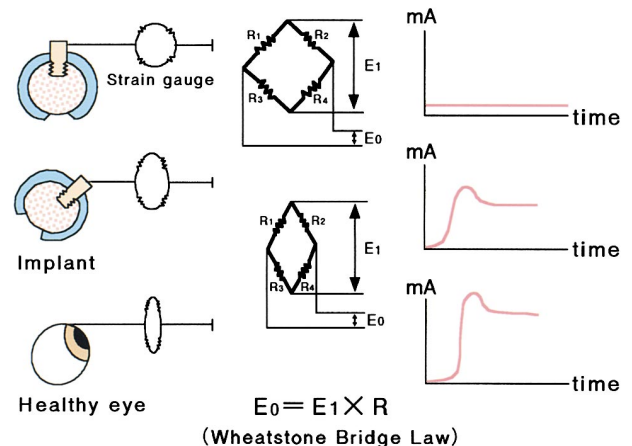


**Figure 3.** Measurement of movements of the health eye and the implant by photographic analysis of the anterior orbit. **a:** maximum movement (mm) of the healthy eye; **b:** maximum movement (mm) of the implant; **c:** corneal radius (mm) of the healthy eye. Movement angle ( $^{\circ}$ ) of the healthy eye:  $X = 45 \times a/c$  (movement angle,  $X = 45^{\circ}$  at  $a = c$ ; movement angle ( $^{\circ}$ ) of the implant:  $Y = 45 \times b/c$ ; mobility efficiency (%):  $Z = Y/X \times 100$ .



**Figure 2.** The autologous sclera-covered implant.

tion:  $3.6 \pm 2.0$  years) and eyelid retraction, who had been followed-up for a mean of  $1.8 \pm 0.6$  years after the eyeball enucleation for cosmetic purposes. The underlying causes of phthisis bulbi were traumatic in all patients: corneoscleral laceration in four, chemical burn of the eye in one, siderosis in one, and traumatic detachment of the retina in one.



**Figure 4.** Measurement of movements of the healthy eye and of the implant using a strain gauge.

### *Autologous Sclera-Covered Implants*

The newly designed implant is a hydroxyapatite sphere, 14–18 mm in diameter, having a 55% void volume, with a 3-mm peg hole toward its center. The peg, which provides mobility to the ocular prosthesis, is an adjustable length polyethylene screw. The implant was placed according to the following procedure (Figure 1). First, the cornea of the enucleated eyeball is removed from the corneoscleral limbus. Then, the intraocular contents are removed. A hole, 3 mm in diameter, is left at the site of the optic nerve. The whole implant is covered with the patient's own sclera, and a peg is passed through the hole at the site of optic nerve in the sclera (Figures 2A,B). The autologous sclera-covered implant (hereafter referred to as the implant) is then inserted in the orbit. After that, the four rectus muscles are sutured to the sclera at a site 10 mm posterior to the peg. In the last step, the bulbar conjunctiva is sutured to the sclera of the implant at the anterior portion with 6-0 absorbable sutures.

### *Measurement of Movement of Implant by Photographic Analysis*

Photographic analysis of the anterior orbits in gaze positions showed four directions for both the healthy eye and the implant. The maximum horizontal and vertical movements of the healthy eye and those of the implant were measured (in mm) with a caliper; the respective movements were compared in terms of the movement angle calculated (in degrees) from the measurements (Figure 3). Three patients

with conventional semi-integrated magnetic implants (mean age:  $57.2 \pm 16.4$  years) were chosen as controls.

### *Measurement of Movement of the Implant Using a Strain Gauge*

A quantitated forced-duction tester with a built-in strain gauge was used.<sup>14</sup> The tip of the pressure sensor was attached to the insertion sites of the extraocular muscles of the healthy eye and to the peg of the implant. The respective maximum horizontal and vertical movements were measured three times in each patient (Figure 4). The physical resistance (tugging weight) applied both to the implant peg and at the insertion sites of the extraocular muscles of the healthy eye was converted to variations in electric current from an electric resistance ( $1g = 12.2$  mA). This was done using the Wheatstone Bridge Law to calculate the movement as tugging weight in grams. Statistical analysis of the difference in movement between the implant and the healthy eye was calculated by means of the Mann-Whitney *U*-test.

## **Results**

### *Postoperative Course of Autologous Sclera-Covered Implant*

About 2 weeks after insertion of the autologous sclera-covered implant, the portion of the sclera in the anterior socket was covered by the conjunctiva proliferating from the adjacent area, and a large conjunctival cul-de-sac and eye socket had formed. At follow-up,  $1.8 \pm 0.6$  years after the operation, nei-

**Table 1.** Clinical Background Data of Patients and Postoperative Course

No.	Patient		Phthisis Bulbi			Postoperative Course of the Implant	
	Age	Sex	Affected Eye	Cause	Duration (years)	Implant Sphere (mm)	Complications
1	24	Female	Left	Perforating injury	2.4	14	(-)
2	57	Male	Right	Perforating injury	6.0	14	Conjunctival polyp
3	42	Female	Left	Siderosis	1.3	16	(-)
4	67	Male	Left	Perforating injury	3.0	14	(-)
5	26	Female	Right	Perforating injury	1.5	14	(-)
6	83	Male	Left	Traumatic amotio retinae	7.0	16	(-)
7	38	Male	Left	Chemical burn	4.0	14	(-)
					48.1 $\pm$ 20.2	3.6 $\pm$ 2.0	

Mean  $\pm$  SD.

**Table 2.** Maximum Movements of Implants and Healthy Eyes as Determined by Photographic Analysis of the Anterior Orbit in 4 Directions

Patient		Implant				Healthy Eye			
No.	Postoperative Period (year)	Adduction	Abduction	Supraduction	Infraduction	Adduction	Abduction	Supraduction	Infraduction
1	1.5	70.2	64.1	45.9	60.7	76.3	74.0	63.8	65.8
2	1.2	61.8	56.5	46.6	52.2	66.9	65.9	58.4	60.8
3	2.5	69.8	61.6	51.4	58.2	74.2	72.8	58.9	65.4
4	1.5	59.1	53.7	45.5	55.2	68.3	68.4	56.3	62.1
5	2.0	73.1	66.8	59.7	63.5	75.3	76.2	63.2	64.5
6	3.0	64.2	56.7	48.1	53.1	68.2	67.4	54.7	58.2
7	1.0	62.4	57.7	45.7	57.1	67.5	68.8	58.3	62.8
	1.8 ± 0.6	65.7 ± 4.8	59.6 ± 4.3	50.2 ± 4.9	57.1 ± 3.7	70.9 ± 3.8	70.5 ± 3.5	59.1 ± 3.1	62.8 ± 2.5

Mobility angles are expressed in degrees (°).  
(Mean ± SD.)

ther intraorbital infection nor prolapse of the implant had occurred; the implant remained stable in the orbit of these patients (Table 1).

*Measurement of Movement of Implant by Photographic Analysis*

Table 2 shows the maximum angles of movement for the implants and healthy eyes. Taking the mean values obtained for healthy eyes as 100%, the adducting, abducting, supraducting, and infraducting efficiencies of the implants were calculated to be 92.6 ± 3.3%, 85.9 ± 5.4%, 84.9 ± 5.6%, and 90.9 ± 3.9%, respectively. The supraducting efficiency of the implant tended to be lower than its adducting, abducting, and infraducting efficiencies and those of the healthy eye in all patients. The adducting and abducting efficiencies of the implant with regard to the lateral and medial gazes of the healthy eye were 93.2 ± 3.2% and 83.9 ± 2.8%, respectively. The adduction

of the implant was closely conjugated to the movement of the healthy eye. When the prosthesis was fitted to the implant, the mobility efficiency of the artificial eye became lower than that of the implant in all patients. The adducting efficiency of the artificial eye was 72.1 ± 2.7%, and the abducting efficiency was 75.3 ± 4.3% of the respective movements of the healthy eye. In other words, prosthetic wear restricted the adduction of the implant. The adducting and abducting efficiencies of the artificial eye in the controls were 60.4 ± 4.1% and 64.3 ± 5.5% of the respective movements of the healthy eye.

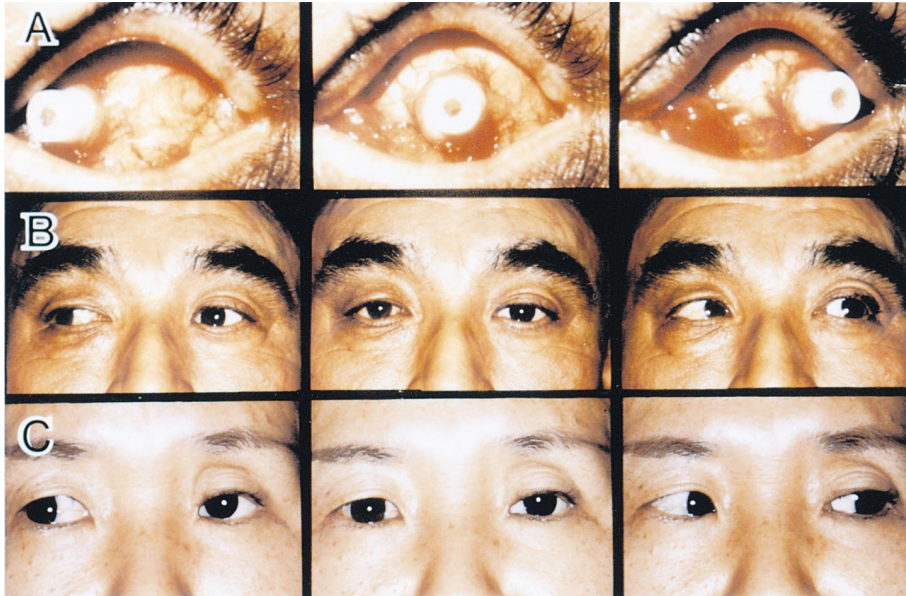*Measurement of Movement of Implant Using Strain Gauge*

The tugging weight applied to the strain gauge at the maximum horizontal and vertical movements (mean ± SD tugging weight for the seven patients) was 381.0 ± 29.5 g for adduction, 365.5 ± 21.4 g for

**Table 3.** Tugging Weights of Healthy Eyes and Implants Measured Using a Strain Gauge

Patient		Implant				Healthy Eye			
No.	Number of Measurements	Adduction	Abduction	Supraduction	Infraduction	Adduction	Abduction	Supraduction	Infraduction
1	3	351.2 ± 20.1*	344.9 ± 33.7	317.7 ± 33.4	311.7 ± 37.6	383.5 ± 37.7	375.2 ± 25.7	329.8 ± 31.7	339.6 ± 32.7
2	3	334.6 ± 34.6	330.7 ± 10.1	294.1 ± 31.4	301.7 ± 25.0	377.0 ± 25.4	370.5 ± 13.6	311.4 ± 28.4	330.6 ± 22.3
3	3	350.9 ± 24.5	316.0 ± 43.9	313.8 ± 22.9	308.1 ± 30.8	378.7 ± 37.2	366.6 ± 24.4	321.6 ± 22.5	336.9 ± 25.2
4	3	324.5 ± 24.5	316.2 ± 26.5	295.1 ± 34.9	290.2 ± 40.6	376.4 ± 31.6	357.2 ± 26.4	317.3 ± 34.7	333.8 ± 19.8
5	3	380.9 ± 42.5	363.4 ± 25.6	321.5 ± 31.4	323.3 ± 37.5	393.7 ± 38.9	373.8 ± 29.2	329.3 ± 28.9	339.7 ± 36.5
6	3	324.4 ± 17.1	294.9 ± 27.9	279.4 ± 32.9	281.9 ± 36.2	375.8 ± 36.8	358.7 ± 15.8	328.3 ± 19.7	329.3 ± 15.6
7	3	343.0 ± 11.7	326.8 ± 38.1	294.4 ± 35.4	313.2 ± 33.7	381.8 ± 32.3	355.2 ± 27.1	316.5 ± 33.8	329.3 ± 30.3
	21	344.2 ± 29.2	327.6 ± 33.4	302.3 ± 30.5	304.3 ± 32.1	381.0 ± 29.5	365.5 ± 21.4	322.0 ± 25.2	334.2 ± 23.0

\*Tugging weight is expressed in grams.  
(Mean ± SD.)



**Figure 5.** Movements of the healthy eye, artificial eye, and autologous sclera-covered implant as determined by photographic analysis of the anterior orbit in four directions of gaze. (A) Movement of implant in patient 2 (left eye). When the adducting efficiency of the healthy eye was calculated as 100%, the adducting efficiency of the implant (left side) was 92.4%, and its abducting efficiency (right side) was 85.7%. (B) Movements of the artificial eye (left eye) and healthy eye (right eye) in patient 2. The adducting efficiency of the artificial eye (left side) was 72.4%, and its abducting efficiency (right side) was 82.7%. (C) Movements of the artificial eye (left eye) and healthy eye (right eye) in patient 3. The adducting efficiency of the artificial eye (left side) was 73.5%, and its abducting efficiency (right side) was 82.7%.

abduction in the healthy eye, and  $344.2 \pm 29.2$  g and  $327.6 \pm 33.4$  g for the respective movements of the implant. The tugging weight applied to the implant corresponded to  $90.4 \pm 4.4\%$  of the weight for adduction, and to  $89.5 \pm 5.3\%$  of that for abduction of the healthy eye. The mean adducting, abducting, supraducting, and infraducting efficiencies of the implant corresponded to  $94.1 \pm 4.6\%$ ,  $85.8 \pm 4.60\%$ ,  $93.8 \pm 4.5\%$ , and  $90.9 \pm 4.9\%$ , respectively, for the movements of the healthy eye. That is, the adduction and supraduction of the implant were significantly conjugated to those of the healthy eye (Table 3).

### Discussion

For insertion of implants, the affected eye is either enucleated or eviscerated, depending on the presence or absence of endophthalmitis, or an intraocular tumor, or on the severity of atrophy of the eyeball. The implant is then placed intraorbitally or in the globe. However, if the atrophy of the eyeball is severe, the intraocular cavity volume becomes too small for the placement of an implant even if the intraocular contents are removed.

The implant we have developed is made of hydroxyapatite, a hydroxylated compound of calcium and phosphoric acid, a light, less-irritating, and less-absorbable biomaterial. The implant is a sphere with

a 55% void volume (Figure 2A). It has proved to be highly biocompatible when compared with the silicone implants and resin spheres previously in use. Excellent results have been achieved with the use of this material at many institutions in recent years. Along with an increase in the number of patients receiving such orbital hydroxyapatite implants in recent years, postoperative complications, such as separation of the conjunctiva of the eye socket, loss of the peg, and extrusion or prolapse of the implant, have been reported.<sup>6–12</sup>

These reports on the implant prolapse appear to involve not only problems of intraorbital biocompatibility, but also the tissue strength of Lyodura® and scleral graft coverings of the implant. The point of insertion of the autologous sclera-covered implant — because the hydroxyapatite implant is covered with the patient's own fresh sclera from the enucleated eyeball — has a high degree of biocompatibility with the eye socket. Moreover, the autologous fresh sclera is stronger histo-anatomically than Lyodura® or the scleral grafts that have been used previously (Figure 2B). Furthermore, suturing of the four rectus muscles to the autologous sclera-covered implant inserted into the Tenon's capsule in the posterior fornicies of the orbit provides the implant with stable intraorbital fixation and results in more natural movement of the artificial eye.

The patients described in this study have been followed for 1–3 years after the operation. None of these developed postoperative complications, such as intraorbital infections, extrusion or prolapse of the implant. The hydroxyapatite implant remained stable in the orbit. The four rectus muscles sutured to the covering sclera retained sufficient function, with the implant showing mobility well conjugated to the ocular movement of the healthy eye (Tables 1 and 2). However, this technique is not indicated for patients with a history of endophthalmitis or intraocular tumor, even if they have phthisis bulbi. The procedure is indicated only in carefully selected patients.

On photographic analysis of the anterior orbit, the movement of the implant was less than that of the healthy eye in all patients. Abduction was more restricted than adduction, and supraduction was more restricted than infraduction. The tugging weights of the strain gauge on the medial and lateral rectus muscles sutured to the implant were  $90.4 \pm 4.4\%$  and  $89.5 \pm 5.3\%$  of the values of the respective muscles of the healthy eye (100%). There was no great difference in movement between the eyes (Table 3). In the ocular movement of the healthy eye when following a target, low movement of the implant for abduction appeared when the healthy eye was in the maximum visible movement angle of adduction, and also the abducting efficiency of the implant was less than that of the healthy eye, whereas the maximum visible movement range of the healthy eye in lateral gaze was high; and the adduction of the implant conjugate to the abduction of the healthy eye was also high. In our study, the four rectus muscles were sutured to the sclera 10 mm posterior to the peg in all patients. Fitting an artificial eye to the peg of the implant did not greatly reduce the movement of the implant (Tables 2 and 3). To improve the movement of implants in the future, it is essential to determine the optimal diameter of the implant and the sites on the covering sclera where the four rectus muscles should be sutured. The restricted movement of the autologous sclera-covered implant after fitting the prosthesis indicates that to improve the movement of an artificial eye in the future, it will be necessary to form not only a larger conjunctival cul-de-sac, but also to study the integration of the prosthesis to the implant, or to make the prosthesis thinner and lighter.<sup>15,16</sup> (Figure 5) In none of the patients receiving the implant did the autologous sclera-covered implant have greater movement than the healthy eye, nor was the movement of the implant influenced by the ocular movement of the healthy eye. Even with fixation of the implant peg or with modulated movement, such

as passive movement, the ocular movement of the healthy eye was not greatly affected. The most significant feature of this technique is that it is possible to wear an artificial eye earlier than with other procedures.<sup>17</sup>

## Conclusion

In seven eyes, we evaluated the mobility of a newly designed orbital implant made of hydroxyapatite. This orbital implant has a screw peg and is covered with a piece of sclera from the enucleated eye of the patient. The implant was well tolerated, and there were no cases of proptosis during the follow-up of  $1.8 \pm 0.6$  years. Assuming the mobility of a healthy eye as 100%, photographic analysis showed the mobility of the anterior orbit to be  $92.6 \pm 3.3\%$  in adduction,  $85.4 \pm 5.4\%$  in abduction,  $84.9 \pm 5.6\%$  in supraduction, and  $90.9 \pm 3.9\%$  in infraduction. The mean tugging weight of the implant was, when measured by a strain gauge,  $344.2 \pm 29.2$  g in adduction, and  $327.6 \pm 33.4$  g in abduction. These values corresponded to  $90.4 \pm 4.4\%$  and  $89.5 \pm 5.3\%$ , respectively, compared with those in a healthy eye.

The artificial eye that was fitted to the peg of this implant has greater mobility than the artificial eye of the controls in whom a semi-integrated magnetic implant had been used.

---

This manuscript has been published in a Japanese language publication by S Kawai, T Takano, T Suzuki, K Kawai. Mobility of orbital implant covered by own sclera. *Nippon Ganka Gakkai Zasshi* 1998;102(3):193–199. It appears here in a modified form after peer review and editing for *The Japanese Journal of Ophthalmology*.

---

## References

1. Perry AC. Advances in enucleation. *Ophthalmic Plast Reconstr Surg* 1985;4:173–82.
2. Dutton JJ. Coralline hydroxyapatite as an ocular implant. *Ophthalmology* 1991;98:370–7.
3. Ferrone PJ, Dutton JJ. Rate of vascularization of coralline hydroxyapatite ocular implants. *Ophthalmology* 1992;99:376–9.
4. Shields CL, Shields JA, De Potter P. Hydroxyapatite orbital implant after enucleation. *Arch Ophthalmol* 1992;110:333–8.
5. McNab A. Hydroxyapatite orbital implants. Experience with 100 cases. *Aust NZ J Ophthalmol* 1995;23:117–23.
6. Goldberg RA, Holds JB, Ebrahimpour JBS. Exposed hydroxyapatite orbital implants. *Ophthalmology* 1992;99:831–6.
7. Buettner H, Bartley GB. Tissue breakdown and exposure associated with orbital hydroxyapatite implant. *Am J Ophthalmol* 1992;113:669–73.
8. Jordan DR. The popping peg phenomenon. *Arch Ophthalmol* 1994;112:300–1.
9. Shields CL, Shields JA, de Potter P, et al. Problems with the hydroxyapatite orbital implant: experience with 250 consecutive cases. *Br J Ophthalmol* 1994;78:702–6.

10. Remulla HD, Rubin PAD, Shore JW, et al. Complications of porous spherical orbital implants. *Ophthalmology* 1995;102:586-93.
11. Oestreicher JH, Liu E, Berkowitz M. Complications of hydroxyapatite orbital implants. *Ophthalmology* 1997;104:324-9.
12. Triendl R. CJD link prompts ban on brain tissue use. *Nature* 1997;387:5.
13. Homblase A, Biesman BS, Eviatar JA. Current techniques of enucleation: a survey of 5439 intraorbital implants and a review of the literature. *Ophthalmic Plast Reconstr Surg* 1995;11:77-88.
14. Hatami H, Ishikawa K, Fujiu Y, et al. Quantitated forced-duction test with strain gauge. *Rinsho Ganka (Jpn J Clin Ophthalmol)* 1988;42:692-3.
15. Takano T, Kawai K. Reconstruction surgery of orbital component using hydroxyapatite. *Ganka Shujutsu (Jpn J Ophthalmol Surg)* 1995;8:506-10.
16. Jacob-LaBarre JT, DiLoreto DA. Total integration of an ocular implant/prosthesis: preliminary in vivo study of a new design. *Ophthalmic Plast Reconstr Surg* 1995;11:200-6.
17. Jordan DR, Allen LH, Eells A, et al. The use of vicryl mesh (polyglactin 910) for implantation of hydroxyapatite orbital implants. *Ophthalmic Plast Reconstr Surg* 1995;11:95-9.