

Retinopathy in a Patient With Thrombotic Thrombocytopenic Purpura Complicated by Polymyositis

Toshihiko Matsuo, Sachiko Matsuura and Hideki Nakagawa

Department of Ophthalmology, Okayama University Medical School, Okayama City, Japan

Background: Cotton wool spots are known to be a complication in patients with thrombotic thrombocytopenic purpura or with polymyositis.

Case: A 53-year-old woman developed numerous cotton wool spots around the optic disc of both eyes.

Observations: Fluorescein angiography disclosed capillary obstruction and microaneurysms in the early phase, followed by dye leakage in the late phase. Systemically, she showed fever, hemolytic anemia, fragmented red blood cells, thrombocytopenia, proximal muscle weakness, and elevation of serum muscle enzymes. This led to a diagnosis of thrombotic thrombocytopenic purpura complicated by polymyositis.

Conclusion: We believe that this is the first case of thrombotic thrombocytopenic purpura complicated by polymyositis to develop cotton wool spots. **Jpn J Ophthalmol 2000;44:161-164** © 2000 Japanese Ophthalmological Society

Key Words: Cotton wool spots, polymyositis, thrombotic thrombocytopenic purpura.

Introduction

Polymyositis is one of the collagen vascular diseases with an autoimmune background and involves striated muscles. When skin lesions are found in addition to muscle involvement, the condition is called dermatomyositis. Thrombotic thrombocytopenic purpura is diagnosed by a triad of signs: microangiopathic hemolytic anemia, thrombocytopenia, and neurologic manifestations, or, with the addition of fever and renal impairment, a pentad of signs. The etiology remains unknown, but immunological abnormalities have been suggested as an underlying cause. Thrombotic thrombocytopenic purpura is known to be associated with polymyositis or dermatomyositis on rare occasions.¹⁻⁵

Cotton wool spots in the fundus reflect local retinal infarction underlain by retinal capillary obstruction. Well-known conditions that develop cotton wool spots are systemic hypertension, diabetes mellitus, renal diseases, collagen vascular diseases such as

systemic lupus erythematosus, and retinal vein occlusion.⁶ Cotton wool spots have been reported to occur occasionally in patients with either polymyositis or dermatomyositis alone,⁷⁻¹³ or with thrombotic thrombocytopenic purpura alone.¹⁴⁻¹⁶ We report a patient who developed cotton wool spots in both eyes during the course of thrombotic thrombocytopenic purpura complicated by polymyositis.

Case Report

A 53-year-old woman developed morning stiffness of the wrists and knee joints and fever up to 38°-39°C in May 1996. She had been diagnosed with rheumatoid arthritis 15 years earlier and was treated with intramuscular injections of sodium aurothiomalate once a week for the following 5 years. She had been free of symptoms for the next 10 years. This time, she was again given intramuscular sodium aurothiomalate for 2 months but without effect. She was then given bucillamine (150 mg daily) and oral prednisolone (2 mg daily), which reduced the fever to a low grade.

At referral on August 20, 1996, she had proximal muscle weakness, arthralgia of the wrists and knees, leg edema, low grade fever, proteinuria, and lung fi-

Received: August 3, 1998

Correspondence and reprint requests to: Toshihiko MATSUO, MD, Department of Ophthalmology, Okayama University Medical School, 2-5-1 Shikatacho, Okayama City 700-8558, Japan

brosis on plain chest x-ray film. Bucillamine was discontinued, and she was hospitalized on August 30. Blood examinations revealed anemia with an increase of reticulocytes, presence of fragmented red blood cells, leukocytosis mainly with neutrophils and their left shift, abruptly aggravating thrombocytopenia, marked elevation of muscle enzymes, elevated bilirubin, hypergammaglobulinemia, elevation of C-reactive protein and erythrocyte sedimentation rate (Table 1). Rheumatoid factor was positive, but other autoantibodies were negative. Urinalysis showed proteinuria (1167.5 mg/day); the 24-hour creatinine clearance was 78.8 L/day. Bleeding time was longer than 15 minutes, while the coagulation system was normal with coagulation time of 9 minutes, normal levels of fibrinogen and fibrin degradation products, and normal durations of prothrombin time and activated partial thromboplastin time.

The patient had noticed blurred vision in the left eye around August 27. In ophthalmological testing, the best-corrected visual acuity was 1.2 in the right eye and 0.1 in the left eye. The anterior segments in both eyes were unremarkable. Both eyes had numerous cotton wool spots around the optic disc together with macular edema in the left eye (Figure 1). Fluorescein angiography disclosed capillary nonperfusion and microaneurysms around the optic disc in the early phase, followed by dye leakage in the late phase in both eyes (Figure 2).

On September 7, she developed an acute subdural hematoma and underwent transcranial drainage. She

died of acute renal failure on September 12. Renal necropsy demonstrated fibrinoid thrombi and endothelial damage of afferent and efferent arterioles, and thickened loops of the glomeruli. Necropsy of the thigh muscle detected no inflammation.

Discussion

Anemia with the increased number of reticulocytes suggested hemolytic anemia, and the presence of fragmented red blood cells in circulation indicated microangiopathic hemolytic anemia in this patient. Thrombocytopenia associated with microangiopathic hemolytic anemia with the background of a normal coagulation system supported the diagnosis of thrombotic thrombocytopenic purpura. Acute subdural hematomas are caused by thrombocytopenia. Acute retinal failure at the end stage and endothelial damage of the renal arterioles found at necropsy are consistent with thrombotic thrombocytopenic purpura.

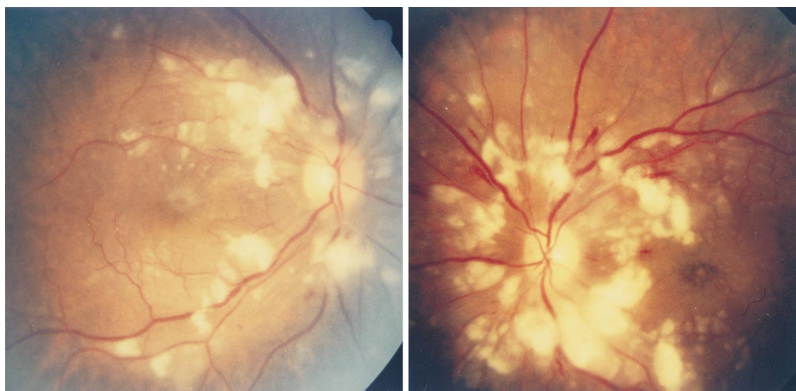
Proximal muscle weakness and elevation of serum muscle enzymes in this patient led to the diagnosis of polymyositis. Continuous high grade fever and the elevation of C-reactive protein and erythrocyte sedimentation rate long before the onset of thrombocytopenia is explained by the polymyositis. Also consistent with the diagnosis was the fact that high grade fever became low grade in response to oral prednisolone. Histopathological diagnosis for polymyositis

Table 1. Blood Examinations

	Normal Range	August 20	September 2
White blood cell	3.0–9.4 × 10 ³ /μL	11.4	11.0
Red blood cell	3.70–4.90 × 10 ⁶ /μL	3.52	2.92
Hemoglobin	11.5–14.5 g/dL	10.1	8.6
Platelet	150–400 × 10 ³ /μL	259	63
Reticulocyte	0.7–2.0%	5.5	7.3
	30–100 × 10 ³ /μL	189	210
Lactate dehydrogenase	236–455 IU/L	1268	1925
Aldolase	1.6–5.9 IU/L	29.8	41.2
Creatine kinase	41–258 IU/L	1146	1030
Myoglobin	<63 ng/mL	n.d.	1213
Aspartate aminotransferase	11–32 IU/L	63	72
Alanine aminotransferase	6–39 IU/L	62	57
Total bilirubin	0.33–1.28 mg/dL	0.87	1.31
Direct bilirubin	0.08–0.28 mg/dL	n.d.	0.38
C-reactive protein	<0.3 mg/dL	6.9	5.2
Erythrocyte sedimentation rate (mm/hour)		65	n.d.
Rheumatoid factor	<18 IU/mL	33.4	17.7
Immunoglobulin G	1000–2100 mg/dL	2489	2217

n.d.: not determined.

Figure 1. Fundus photographs of 53-year-old woman with numerous cotton wool spots around the optic disc of both eyes (Right eye: left, left eye: right).



could not be obtained at necropsy, which might be attributable to the site of the necropsy.

Thrombotic thrombocytopenic purpura has been known to be complicated, though rarely, with polymyositis,¹⁻⁵ as seen in this patient. Diagnosis of rheumatoid arthritis in this patient was based on morning stiffness, arthralgia of the wrists and knee joints, and positive rheumatoid factor. However, the diagnosis

was questioned by the absence of joint swelling and bone destruction of the joints in x-rays.

Massive cotton wool spots around the optic disc of both eyes have been reported to occur in polymyositis⁷⁻¹³ or in thrombotic thrombocytopenic purpura.¹⁴⁻¹⁶ To our knowledge, this is the first patient to develop massive cotton wool spots with a background of thrombotic thrombocytopenic purpura

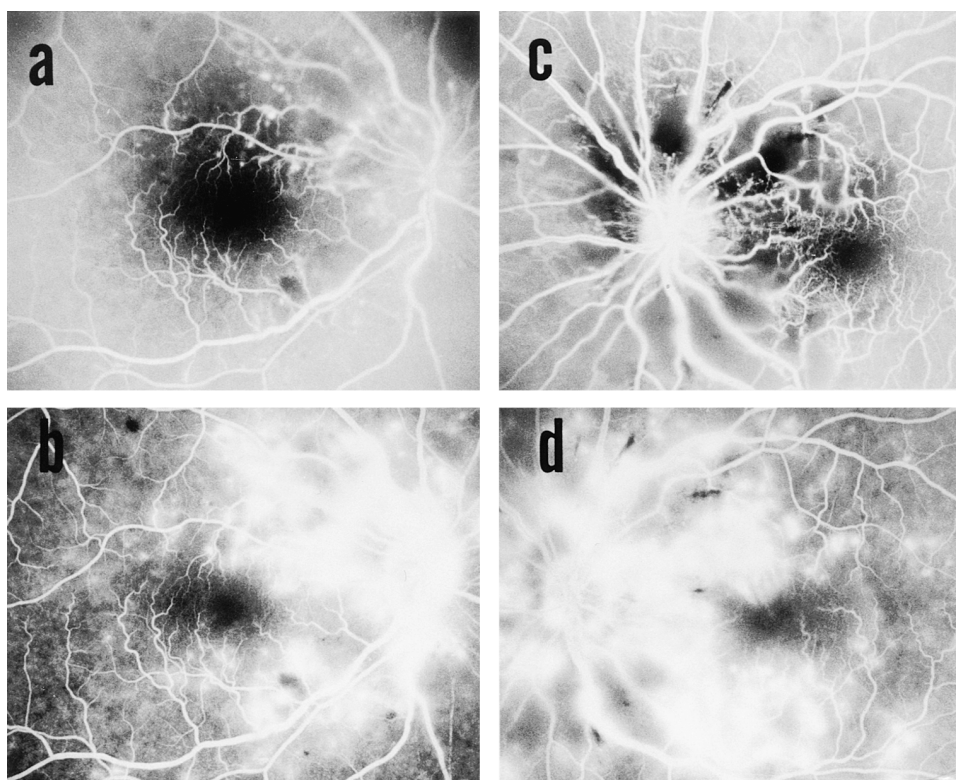


Figure 2. Fluorescein angiogram in same patient. Note capillary obstruction and microaneurysms on the early phase (a,c) and late-phase dye leakage (b,d).

complicated by polymyositis. Retinal capillary obstruction, underlying cotton wool spots, would be the same as capillary and arteriolar obstruction that occurs in other organs, including the kidneys, as in this patient. Serous retinal detachment is another ophthalmic complication reported previously in thrombotic thrombocytopenic purpura and considered to be caused by obstruction of choroidal vessels.^{17,18} This patient, however, did not show any sign of chorioidopathy on fluorescein angiography.

In conclusion, the presence of cotton wool spots in both eyes suggests the involvement of systemic diseases and, therefore, blood examinations are mandatory for the correct diagnosis.

References

1. Sawdyk MA, Jundt J. Dermatomyositis complicated by thrombotic thrombocytopenic purpura. *Henry Ford Hosp Med J* 1985;33:214–8.
2. Noda M, Kitagawa M, Tomoda F, Iida H. Thrombotic thrombocytopenic purpura as a complicating factor in a case of polymyositis and Sjögren's syndrome. *Am J Clin Pathol* 1990;94:217–21.
3. Ellingson TL, Wilske K, Aboulafia DM. Case report: thrombotic thrombocytopenic purpura in a patient with polymyositis: therapeutic importance of early recognition and discussion of pathogenic mechanisms. *Am J Med Sci* 1992;303:407–10.
4. Miyaoka Y, Urano Y, Nameda Y, et al. A case of dermatomyositis complicated by thrombotic thrombocytopenic purpura. *Dermatology* 1997;194:68–71.
5. Saito Y, Hamamura K, Kurata Y, Sugimoto T. A case of dermatomyositis complicated by thrombotic thrombocytopenic purpura (TTP) which responded to combination of gamma globulin and vincristine: clinical analysis on TTP cases in the Japanese literatures. *Rinsho Ketsueki (Jpn J Clin Hematol)* 1993;34:68–73.
6. Brown GC, Brown MM, Hiller T, Fischer D, Benson WE, Magargal LE. Cottonwool spots. *Retina* 1985;5:206–14.
7. Otradovec J, Stibor V, Suta M. Retinopathy in polymyositis. *Klin Monatsbl Augenheilkd* 1970;156:498–507.
8. Harrison SM, Frenkel M, Grossman BJ, Matalon R. Retinopathy in childhood dermatomyositis. *Am J Ophthalmol* 1973;76:786–90.
9. Fruman LS, Ragsdale CG, Sullivan DB, Petty RE. Retinopathy in juvenile dermatomyositis. *J Pediatr* 1976;88:267–9.
10. Cohen BH, Sedwick LA, Burde RM. Retinopathy of dermatomyositis. *J Clin Neuroophthalmol* 1985;5:177–9.
11. Chu-Lee A, Stoller G, Jaffe IA. Retinopathy in adult dermatomyositis. *J Rheumatol* 1995;22:2372–3.
12. Yeo LMW, Swaby DSA, Situnayake RD, Murray PI. Irreversible visual loss in dermatomyositis. *Br J Rheumatol* 1995;34:1179–81.
13. Enoki T, Nakagami T, Murakami A, Okisaka S, Nakabayashi I, Yoshizawa N. A case of dermatomyositis with severe retinopathy in a patient who died of acute interstitial pneumonia. *Nippon Ganka Gakkai Zasshi (J Jpn Ophthalmol Soc)* 1997;101:441–5.
14. Gum KB, Carter KD, Vine AK. Massive bilateral retinal vascular occlusion secondary to thrombotic thrombocytopenic purpura. *Retina* 1988;8:185–7.
15. Melton RC, Spaide RF. Visual problems as a presenting sign of thrombotic thrombocytopenic purpura. *Retina* 1996;16:78–80.
16. Power MH, Regillo CD, Custis PH. Thrombotic thrombocytopenic purpura associated with Purtscher retinopathy. *Arch Ophthalmol* 1997;115:128–9.
17. Percival SPB. Ocular findings in thrombotic thrombocytopenic purpura (Moschcowitz's disease). *Br J Ophthalmol* 1970;54:73–8.
18. Lambert SR, High KA, Cotlier E, Benz EJ Jr. Serous retinal detachments in thrombotic thrombocytopenic purpura. *Arch Ophthalmol* 1985;103:1172–4.