

A New Method for Quantification of Metamorphopsia in Patients with Epiretinal Membrane

Kei Shinoda,* Susumu Ishida,* Shinichi Kawashima,*
Tadayuki Matsuzaki,* Kyoko Yamada* and Hiroshi Katsura†

*Department of Ophthalmology, Keio University School of Medicine,
Tokyo, Japan; †Department of Ophthalmology, KKR, Tachikawa Hospital, Tokyo, Japan

Purpose: A new method for quantification of metamorphopsia was applied to study distorted vision in patients with epiretinal membrane.

Method: Sixty-three patients with unilateral epiretinal membrane in the macula were examined. A modified Amsler chart (a grid of black lines on a white background measuring 12 × 12 cm with grid squares of 2 × 2 cm) was prepared. If patients saw any of the grid lines as irregular or curved, they were asked to trace these on the chart. The length of all lines drawn by the patients was measured, except those on the outer border. The length of the grid is 1200 mm, but it should be drawn longer by patients with metamorphopsia. The severity of metamorphopsia was also scored subjectively and the relationship of grid length to the subjective score and the visual acuity was analyzed.

Results: The grid length ranged from 1200 to 1259 mm (mean = 1223.3 mm) and was correlated significantly with the subjective score ($P < .01$, $\rho = .387$).

Conclusion: This method might be applicable for evaluating the severity of metamorphopsia and the surgical outcome in patients with epiretinal membrane. **Jpn J Ophthalmol 2000; 44:424–427** © 2000 Japanese Ophthalmological Society

Key Words: Epiretinal membrane, metamorphopsia, quantification.

Introduction

Epiretinal membrane may cause metamorphopsia as well as decreased visual acuity.^{1–4} Patients who have undergone vitreous surgery for epiretinal membrane often continue to complain of metamorphopsia irrespective of whether there is improvement of their visual acuity.^{1,2} It is difficult to evaluate metamorphopsia clinically at present. Accordingly, we developed a new method for quantification of metamorphopsia and applied it to study distorted vision resulting from epiretinal membrane.

Materials and Methods

We examined 63 Japanese patients with unilateral idiopathic epiretinal membrane in the macula who gave informed consent to participation in this study. They were diagnosed by fundus examination with indirect ophthalmoscopy and slit-lamp biomicroscopy using a +90 diopter lens. Patients with any eye disease resulting in decrease of visual acuity, such as cataract, were excluded from this study.

A modified Amsler chart was prepared, which was a grid of black lines on a white background with external dimensions of 12 × 12 cm and comprised individual grid squares measuring 2 × 2 cm (Figure 1). Patients were asked to fixate on the center of the chart with each eye after correction of near vision, holding the chart 28–30 cm from the eyes. If patients saw any irregular or curved lines with the diseased

Received: June 11, 1999

Correspondence and reprint requests to: Kei SHINODA, MD, Department of Ophthalmology, Keio University School of Medicine, 35 Shinanomachi, Shinjuku-ku, Tokyo 160-8582, Japan

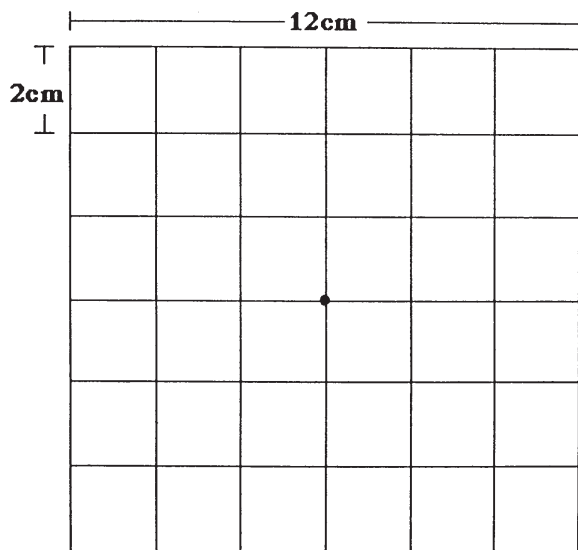


Figure 1. Modified Amsler chart.

eye, they were asked to trace them on the chart using the fellow eye. Patients were asked not to draw any line twice. The length of all lines drawn by the patients was measured, except for lines on the outer border of the grid. The total length of the chart is 1200 mm, and this would be extended by the longer lines drawn by patients with metamorphopsia. The average of five measurements obtained by one investigator using a map meter was determined and the length in millimeters was defined as the total value of metamorphopsia. In the same manner, the total length of the five vertical lines and the five horizontal lines in the grid was defined as the vertical and horizontal value of metamorphopsia, respectively. In addition, patients were asked to rate the severity of their metamorphopsia subjectively on the following scale: 1: none, 2: mild, 3: moderate, 4: severe, and 5: very severe. The number that the patient selected was defined as the patient's subjective metamorphopsia score. The relationships between various values of metamorphopsia and the patient's subjective metamorphopsia score or visual acuity were analyzed by Spearman's rank correction analysis. The comparison between vertical and horizontal metamorphopsia values was analyzed by the Mann-Whitney *U*-test.

In 8 patients, the examination was performed twice. The mean and standard deviation (SD) of the results were calculated, and the coefficients of variation (CV value), which were led by $\text{mean}/\text{SD} \cdot 100\%$, were determined in order to evaluate the reproducibility of the test. The 8 patients consisted of 2 men

and 6 women with ages of 49–81 (average = 67.0) and visual acuity range of 0.1–1.0.

Results

Charts showing scotoma or double lines (Figure 2) were obtained from 2 patients who were excluded from the study; therefore, the results in 61 patients were analyzed. An example is shown in Figure 3. The total metamorphopsia value ranged from 1200–1259, with an average of 1223.3 ± 13.4 , and it increased as the metamorphopsia score increased (Figure 4, Spearman's rank correlation analysis, $n = 61$, $P < .01$, $\rho = .387$). The vertical metamorphopsia value ranged from 600–632 (mean \pm SD, 609.4 ± 7.6), and was less than the horizontal value, which ranged from 600–631 (mean \pm SD, 613.8 ± 7.3) (Mann-Whitney *U*-test, $P < .01$). Both the vertical and horizontal values increased as the metamorphopsia score increased (Spearman's rank correction analysis, $P < .01$, $\rho = .429$, and $P < .01$, $\rho = .306$, respectively).

Visual acuity ranged from 0.09–1.5 and the average was 0.56. As shown in Figure 5, the patients with good visual acuity tended to have lower metamorphopsia scores (Spearman's rank correlation analysis, $n = 63$, $P < .01$, $\rho = -.363$). The patients with lower metamorphopsia values also had better visual acuity (Figure 6, Spearman's rank correlation analysis, $n = 61$, $P = .018$, $\rho = -.305$).

The CV values of the total, vertical, and horizontal values of metamorphopsia in 8 patients examined

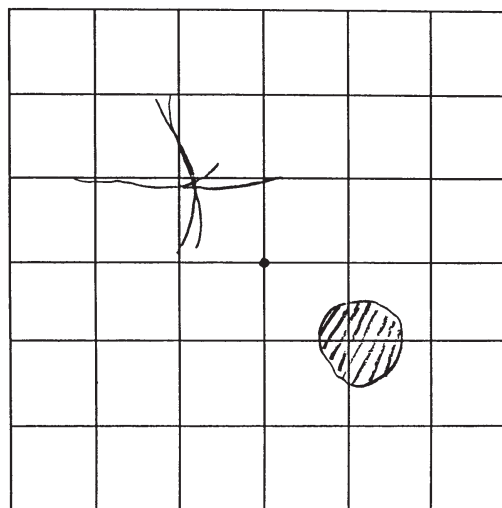


Figure 2. Example of drawing from which metamorphopsia value could not be calculated. Drawings that showed scotoma or double lines were excluded.

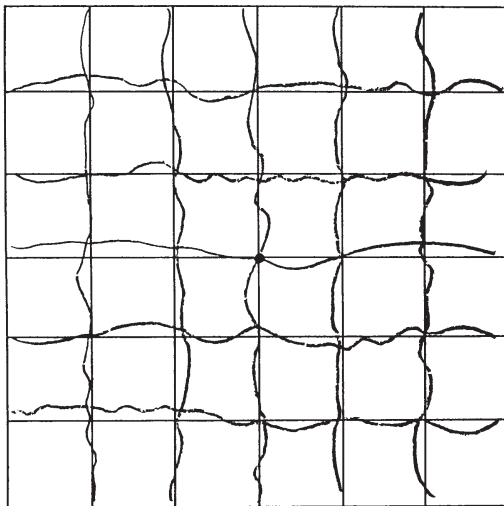
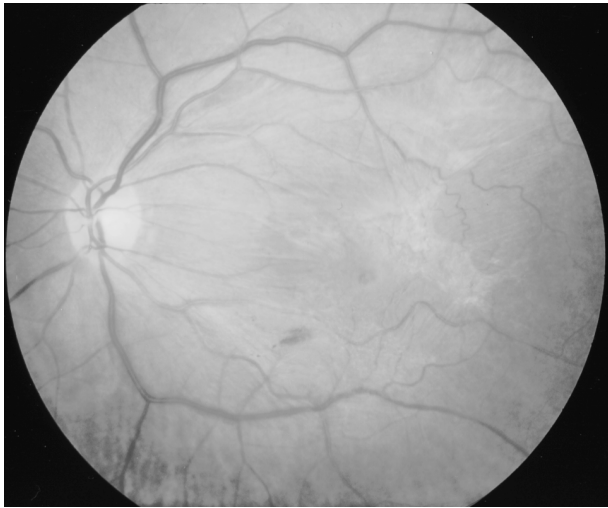


Figure 3. Calculation of metamorphopsia value in 60-year-old woman. Her visual acuity was 0.09 and the subjective metamorphopsia was 4. **(Top)** Fundus photograph showed retinal folds with epiretinal membrane in left eye. **(Bottom)** Chart drawn by patient. Total, vertical, and horizontal metamorphopsia values were 1247, 624, and 623, respectively.

twice were 0.29 (range 0.06-0.79), 0.60 (range 0.12-1.26), and 0.53 (range 0.23-1.02), respectively, showing good reproducibility of the test.

Discussion

Vitreoretinal disorders often cause metamorphopsia,^{1,2} but it is difficult to evaluate this condition correctly. Quantification of the metamorphopsia may make it possible to evaluate the severity of the diseases or the effect of treatment. Although some other investigators⁵⁻⁹ have already tried to quantify metamorphopsia, no method has become popular. In

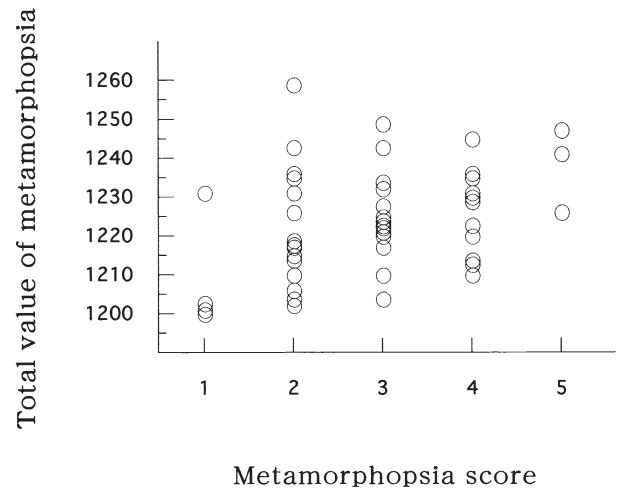


Figure 4. Relationship between total value of metamorphopsia and metamorphopsia score. Total value of metamorphopsia increased as metamorphopsia score increased (Spearman's rank correlation analysis, $n = 61$, $P < .01$, $\rho = .387$).

the present study, we evaluated metamorphopsia quantitatively by using a modified Amsler chart, which is commonly employed to detect metamorphopsia.

The standard Amsler chart is a perfectly regular 10-cm square grid of vertical and horizontal lines set at 5-mm intervals.¹ The linear measurements, 10 cm and 5 mm, appear as an angle of 20° and 1°, respectively, when the chart is held 28-30 cm from the eyes. In the modified chart, the entire grid, which is a 12-cm square, is 24° high and 24° wide with 12° on

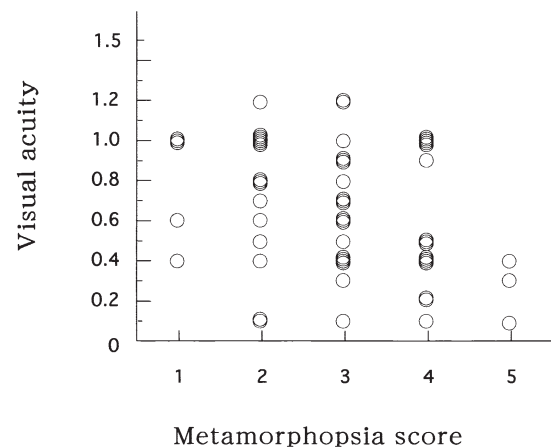


Figure 5. Relationship between metamorphopsia score and visual acuity. Patients with good visual acuity tended to have a lower metamorphopsia score (Spearman's rank correlation analysis, $n = 63$, $P < .01$, $\rho = -.363$).

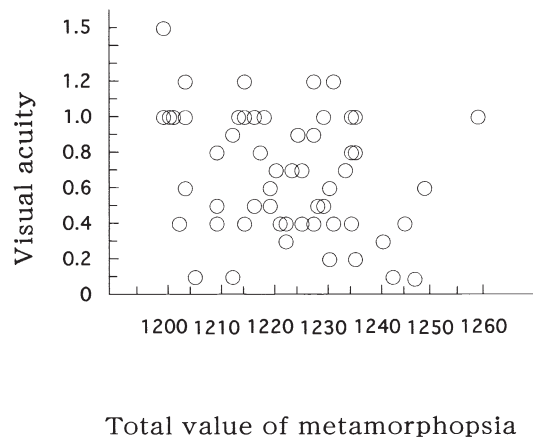


Figure 6. Relationship between total value of metamorphopsia and visual acuity. Patients whose metamorphopsia value was lower had better visual acuity (Spearman's rank correlation analysis, $n = 61$, $P = .018$, $\rho = -.305$).

each side of the center. Each small square of the grid (2×2 cm) subtends and angle of 4° and projects onto approximately 1.1 mm^2 of the fundus. Thus, the chart should serve as a test of the macular area and should detect lesions larger than 1 disc diameter.

This study showed that the length of the lines seen by the diseased eye increased, as subjective metamorphopsia became more intense. The vertical and horizontal values of metamorphopsia, which should indicate the severity of metamorphopsia in each direction, also correlated with the subjective metamorphopsia score. Our data suggest that metamorphopsia tends to be more severe in the horizontal direction than in the vertical direction.

In this study, we evaluated the subjective severity of metamorphopsia by asking patients to select a score. The total measured metamorphopsia values varied especially in the patients with a subjective score of 2–4, suggesting that these scores showed considerable variation. Curvilinear distortion of straight lines or patterns is defined as metamorphopsia.¹⁰ In metamorphopsia, subjective complaints include curved appearance of straight lines such as frames of a window, oval appearance of round objects, such as a full moon, macropsia, or micropsia. For these, excellent methods for quantification of macropsia and micropsia by use of a computer monitor have been reported.^{5,9} However, distortion of vision is difficult to detect accurately, because it is felt variously, depending on the area of distortion and

the distance from the fixating point, which are difficult to reflect in our methods of detection. Therefore, the present study might evaluate only certain aspects of metamorphopsia and further investigation is required to develop methods for detecting other aspects. In addition, although reproducibility of the test was good, it appeared to be difficult for some patients to draw lines accurately. Use of a computer monitor, which can help patients to trace on a chart exactly what they see by making it easy to rewrite the lines, may mitigate this problem.

In conclusion, this study showed that numerical values expressing the severity of metamorphopsia can be obtained with a modified Amsler chart. This method might be applied to patients with vitreoretinal disorders causing metamorphopsia for evaluating the severity of the disease and the effect of treatment including surgery.

The authors have no proprietary interests in any product mentioned in this article. This paper was published in *Nippon Ganka Gakkai Zasshi (J Jpn Ophthalmol Soc)* 1999;103:806–10. It appears here in a modified form after peer review and editing for the *Japanese Journal of Ophthalmology*.

References

1. Amsler M. Earliest symptoms of diseases of the macula. *Br J Ophthalmol* 1953;37:521–37.
2. Kusaka S, Kusunoki T, Danjo Y, Ikeda T, Tano Y. Vitreous surgery for epiretinal membranes. *Rinsho Ganka (Jpn J Clin Ophthalmol)* 1992;46:123–7.
3. Kawakubo H, Minato H, Shimada H, Sato Y, Matsui M. Prognostic factors in vitrectomy for idiopathic epiretinal membrane of the macula. *Nihon Ganka Kiyo (Folia Ophthalmol Jpn)* 1994;45:1270–5.
4. Kitagawa K, Ogino N. Central retinal sensitivity following surgical removal of idiopathic epiretinal membrane. *Rinsho Ganka (Jpn J Clin Ophthalmol)* 1993;47:177–82.
5. Matsumoto C, Tsuboi S, Okuyama S, Uyama K, Otori T. Quantitation of metamorphopsia. Method of evaluation. *Rinsho Ganka (Jpn J Clin Ophthalmol)* 1990;44:271–4.
6. Frisén L, Frisén M. Micropsia and visual acuity in macular edema. A study of the neuro-retinal basis of visual acuity. *Albrecht Graefes Arch Klin Exp Ophthalmol* 1979;210:69–77.
7. Lakshminarayanan V, Aziz S, Enoch JM. Quantification of metamorphopsia using hyperacuity techniques. *Optom Vision Sci* 1991;68:942–5.
8. Hollins M, Bunn KW. The relation between convergence micropsia and retinal eccentricity. *Vision Res* 1977;17:403–8.
9. Lindblom B. Measuring micropsia in retinal swelling: A monocular approach. *Chibret Int J Ophthalmol* 1987;5:48–54.
10. Glaser JS, Goodwin JA. Neuro-ophthalmologic examination: the visual sensory system. In: Tasman W, ed. *Duane's clinical ophthalmology*. Vol. 2. Philadelphia: J. B. Lippincott, 1994:1–26.