

Rhodopsin Gene Codon 106 Mutation (Gly-to-Arg) in a Japanese Family with Autosomal Dominant Retinitis Pigmentosa

Budu,* Masayuki Matsumoto,
Seiji Hayasaka, Tetsuya Yamada and Yoriko Hayasaka

*Department of Ophthalmology,
Toyama Medical and Pharmaceutical University, Toyama, Japan*

Purpose: To examine rhodopsin gene mutations in Japanese patients with retinitis pigmentosa.

Methods: We performed a mutational analysis of the rhodopsin gene in 42 patients from 40 families with retinitis pigmentosa. Genomic DNA was amplified by polymerase chain reaction (PCR) and the PCR products were sequenced. Restriction enzyme analysis was performed in family members of 1 patient with a rhodopsin gene mutation (Gly106Arg) and in 100 normal individuals.

Results: Among the patients with retinitis pigmentosa, 3 patients in one family had a heterozygous Gly106Arg mutation of the rhodopsin gene. They had night blindness and sectorial retinal dystrophy (predominantly at the inferior fundus) in both eyes. None of the 100 individuals with normal fundi had the Gly106Arg mutation of the rhodopsin gene.

Conclusion: The Gly106Arg mutation of the rhodopsin gene has been found in Japanese patients with sectorial retinitis pigmentosa. **Jpn J Ophthalmol 2000;44:610–614** © 2000 Japanese Ophthalmological Society.

Key Words: Codon 106, incidence in Japanese, rhodopsin gene, sectorial retinitis pigmentosa.

Introduction

Retinitis pigmentosa is a genetically heterogeneous disease. Several pathogenic genes have been previously reported to be implicated in retinitis pigmentosa: the mutations of the rhodopsin gene, the peripherin/RDS gene, and the phosphodiesterase beta subunit gene have been found in Caucasian patients.^{1–4} The Gly106Arg mutation of the rhodopsin gene has been previously reported in American, British, and Spanish families with autosomal dominant retinitis pigmentosa.^{5–8} We report here that the Gly106Arg mutation of the rhodopsin gene was found in three members of a Japanese family with autosomal dominant retinitis pigmentosa.

Materials and Methods

Patients

We analyzed the rhodopsin gene in 42 Japanese patients from 40 families with retinitis pigmentosa, including 7 cases from 5 independent families with an autosomal dominant trait, 6 patients with autosomal recessive inheritance, and 29 patients with sporadic type; and in 100 individuals with normal fundi.

DNA Sequencing

Informed consent was obtained from all subjects. Genomic DNAs were extracted from peripheral blood leukocytes of each subject and amplified by polymerase chain reaction (PCR) with a GeneAmp PCR system 2400 (Perkin Elmer, Foster City, CA, USA). Each amplification of the rhodopsin gene was performed using 100 ng of genomic DNA in 20 μ L of a mixture containing 10 mM Tris-HCl (pH 8.3), 50 mM KCl, 1.5 mM MgCl₂, 200 μ M of each dNTP, 1.25

*Dr. Budu is a postgraduate student from Indonesia.

Received: November 5, 1999

Correspondence and reprint requests to: BUDU, MD, Department of Ophthalmology, Toyama Medical and Pharmaceutical University, 2630 Sugitani, Toyama 930-0194, Japan

U of Ampli *Taq* DNA polymerase (Perkin Elmer, Branchburg, NJ, USA) and 10 pmol of each primer. The coding region of the rhodopsin gene was amplified by using six pairs of primers, as reported by Dryja et al,⁹ and incubation of the reaction mixture according to the following conditions: 2 minutes at 94°C followed by 30 cycles at 94°C for 30 seconds (denaturation), at 59°C for 30 seconds (annealing), and at 72°C for 1 minute (extension). All of the amplified PCR products were directly sequenced with an automated DNA sequencer (ABI 310, Perkin Elmer, NJ). The sense and antisense DNA sequences were confirmed in all subjects.

Restriction Enzyme Analysis

To test for the Gly106Arg mutation, restriction enzyme analysis was performed. A 320-bp fragment containing the 3' end of exon 1 was amplified using genomic DNA from three affected members in a family with retinitis pigmentosa associated with the Gly106Arg mutation and from 100 normal individuals. The PCR products were digested with *Apa* I (Takara, Shiga) and electrophoresed on 3% agarose gels. When the PCR products harbor the Gly106Arg mutation, the 320-bp band remains undigested due to the abolition of an *Apa* I recognition site.

Results

Of 42 Japanese patients with retinitis pigmentosa, 3 patients in one family had a heterozygous substitution of guanine to adenine at nucleotide position 610, as shown by DNA sequencing (Figure 1). This mutation changes amino acid at codon 106 from glycine to arginine. Restriction enzyme analysis showed

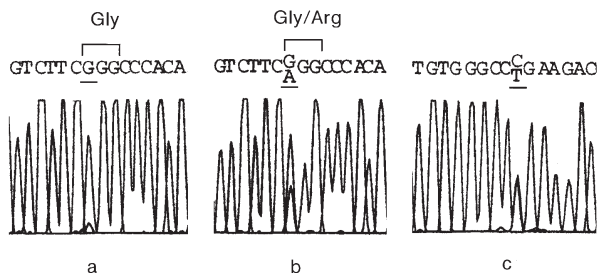


Figure 1. Nucleotide sequences around codon 106 of rhodopsin gene. (a) sense DNA sequence of normal control; (b) and (c), sense and antisense DNA sequences of patient II-2, respectively; substitution of guanine to adenine at nucleotide position 610 results in change of amino acid at codon 106 from glycine to arginine. Sequencing of DNA from patient II-2 indicated same heterozygous mutation at codon 106 of rhodopsin.

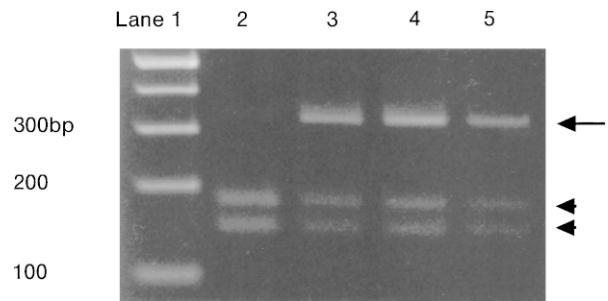


Figure 2. Gel electrophoresis patterns showing *Apa* I restriction enzyme analysis. Lane 1: DNA markers; Lane 2: normal control shows doublet bands (174 and 146 bp) (arrowheads); Lanes 3: (Patient II-2), 4: (Patient III-1), and 5: (Patient III-2) show 320-bp (arrow), 174-bp, and 146-bp fragments, which indicate heterozygous rhodopsin mutation.

that the abolition of the *Apa* I recognition site (GGGCCC) was heterozygous in the proband (Figure 2). Two daughters of the proband also had heterozygous Gly106Arg mutation (Figure 2). No loss of the *Apa* I recognition site was observed in the 100 individuals with normal fundi.

Case Reports

Family. The pedigree of the family with the Gly106Arg mutation of the rhodopsin gene is shown in Figure 3. No parental consanguinity was noted. Two daughters (patients III-1 and III-2) of the male proband (patient II-2) also complained of night blindness without loss of central visual acuity.

Patient II-2. The proband, a 66-year-old man, had complained of night blindness and a gradual loss of vision in both eyes during the previous 5 years. His past medical history was unremarkable. He had had

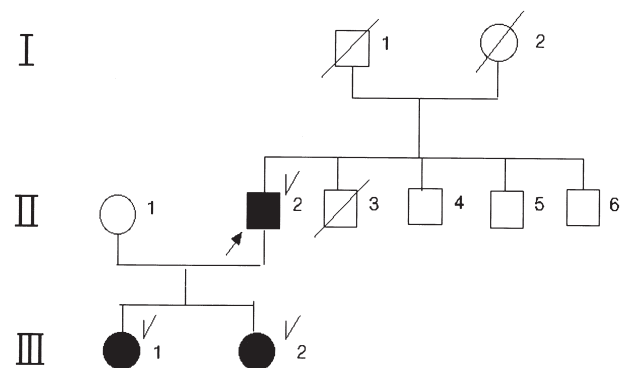


Figure 3. Family tree. □ Male with normal fundi, ○ female with normal fundi, ■: affected male, ● affected female, / deceased, √ examined in this study.

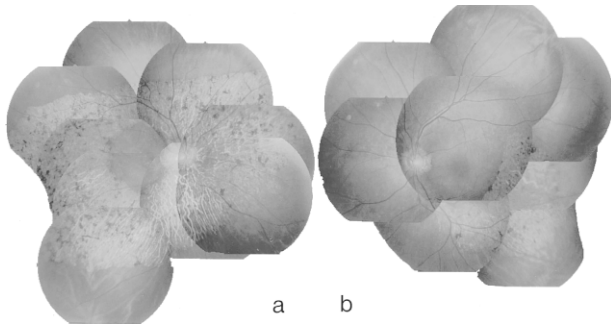


Figure 4. Patient II-2. Fundus photographs of proband show mottled retina, visible choroidal vessels, and pigment around macula in right eye (a), and retinal degeneration around inferior vascular arcade in left eye (b).

good visual acuity of 1.0 in both eyes until age 55. In July 1999, his visual acuity was 0.04 with hyperopic correction (+1.5 diopters) OD and 0.5 with correction (cyl -1.0 diopters, axis 75°) OS. His intraocular pressure was 16 mm Hg OU. The corneas and anterior chambers appeared clear. Cortical opacities were seen in both lenses. Liquefied vitreous bodies were visible bilaterally. Ophthalmoscopically, normal optic disc, discoloration of the fovea, mottled retina with pigmentation and visible choroidal vessels around the macula, and attenuated retinal vessels were seen in the right fundus (Figure 4a). Normal optic disc and mottled retina with pigmentation in the inferior midperiphery were observed in the left fundus (Figure 4b). Fluorescein angiography showed visible choroidal vessels at the lesion in both fundi, and cystoid macular edema in the right fundus (Figure 5). Goldmann visual field testing showed ring scotoma in the right eye and isolated superior defects in the left eye (Figure 6). Color vision, tested by Farnsworth-Munsell panel D-15, showed a tritan

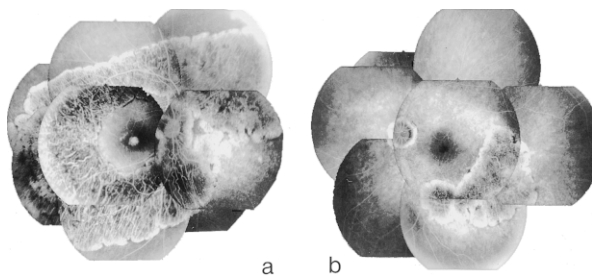


Figure 5. Patient II-2. Fluorescein angiograms show retinal pigment epithelial and choriocapillaris atrophy in right (a) and left (b) eyes. Hyperfluorescence is seen at fovea in right eye (a).

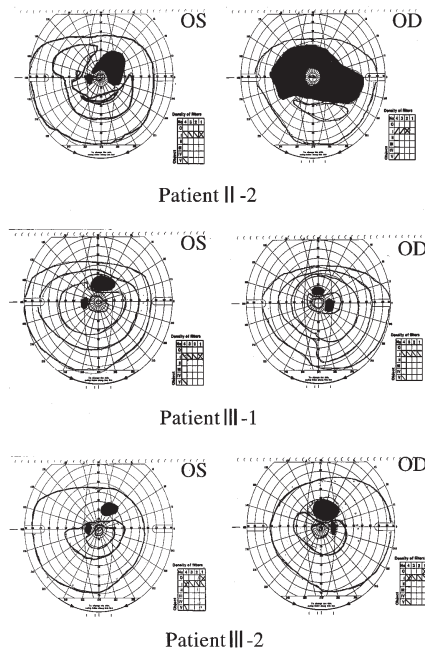


Figure 6. Goldmann visual fields of Patients II-2, III-1, and III-2.

defect in the right eye, and was normal in the left eye. Electroretinograms revealed subnormal rod responses in both eyes (Figure 7). Cone response was normal in the left eye but reduced in the right eye.

Patient III-1. The proband's 44-year-old daughter presented with mild night blindness. Her visual acuity was 1.2 OU. The corneas, anterior chambers, and lenses appeared clear bilaterally. Vitreous liquefaction was noted in both eyes. Subtle retinal lesions along the inferior vascular arcade were visible in both fundi (Figure 8). Goldmann visual field testing

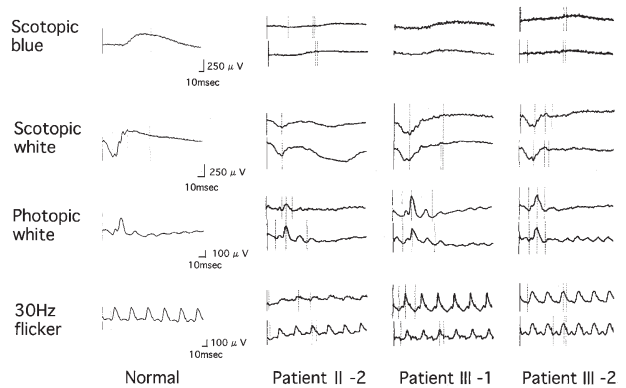


Figure 7. Electroretinograms of normal control, and Patients II-2, III-1, and III-2.

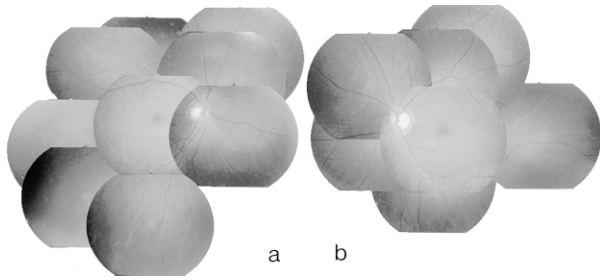


Figure 8. Patient III-1. Fundus photographs show mild retinal mottling along inferior vascular arcades in right (a) and left (b) eyes.

revealed isolated scotomas consistent with retinal lesions in both eyes (Figure 6). Results of a Farnsworth-Munsell panel D-15 test appeared normal bilaterally. Fluorescein angiography showed hyperfluorescence along the vascular arcade, predominantly in the inferior region of both eyes (Figure 9). Electroretinograms revealed moderately reduced rod responses and normal cone responses in both eyes (Figure 7).

Patient III-2. The proband's 40-year-old daughter complained of night blindness that had begun 10 years earlier. Her visual acuity was 1.2 OU. The corneas, anterior chambers, and lenses appeared clear bilaterally. Vitreous liquefaction was noted in both eyes. Retinal degeneration accompanying the pigmentation along the inferior vascular arcade was visible in both fundi (Figure 10). Goldmann visual field testing revealed isolated scotomas consistent with retinal lesions in both eyes (Figure 6). Results of a Farnsworth-Munsell panel D-15 test appeared normal bilaterally. Electroretinograms revealed moderately reduced rod responses and normal cone responses in both eyes (Figure 7).

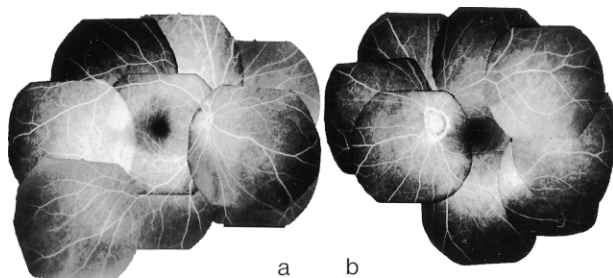


Figure 9. Patient III-1. Fluorescein angiograms show hyperfluorescence along inferior vascular arcades in right (a) and left (b) eyes.

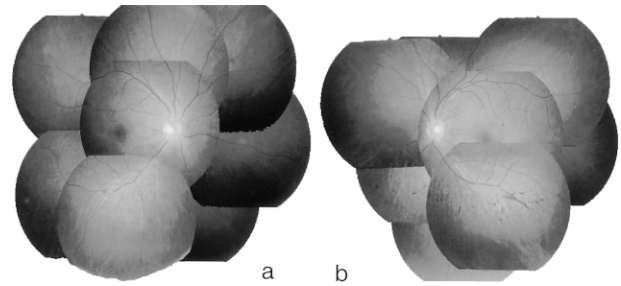


Figure 10. Patient III-2. Fundus photographs show mottled retina, visible choroidal vessels, and pigment around macula in right eye (a), and retinal degeneration along inferior vascular arcade in left eye (b).

Discussion

We performed a mutational analysis of the rhodopsin gene in 42 Japanese patients with retinitis pigmentosa, and found the Gly106Arg mutation in 3 patients from one family. The retinal lesions in this family were autosomal dominantly inherited. None of 100 Japanese individuals with normal fundi had the Gly106Arg mutation. This mutation has been reported in Caucasian families with autosomal dominant retinitis pigmentosa. It is possible that the Gly106Arg mutation may also cause retinitis pigmentosa in the Japanese population.

Patient II-2 with the Gly106Arg mutation had sectorial, asymmetric retinal visual field and electroretinographic findings in both fundi. The visual acuity in the right eye was reduced by cystoid macular edema. Patients III-1 and III-2 showed inferior degeneration of the retina in both eyes. Fishman et al⁶ and Ayuso et al⁸ have reported that the Gly106Arg mutation was associated with the sectorial phenotype of autosomal dominant retinitis pigmentosa, which exhibits a distinct predilection in Caucasian families for pigmentary change in the inferior retina that correlates with impairment of the superior visual field. The predominantly inferior involvement in our patients was similar to the findings described in previous reports.^{6,8}

Sung et al^{10,11} analyzed 34 mutant rhodopsins from patients with autosomal dominant retinitis pigmentosa by cell transfection assays and divided these mutations into two classes. Class I mutants (6/34, 15%), which encoded proteins that resemble the wild type, located at the extreme carboxyl terminus and in the first transmembrane segment. Class II mutants (28/34, 85%), which are clearly defective in protein folding and/or stability, are located in the transmembrane or extracellular domain. The Gly106Arg mu-

tation is thought to be one of the class II mutations, because the mutation is located in the intradiscal loop. Several Class II mutations have been reported, mainly in Caucasian patients with the sectorial phenotype of autosomal dominant retinitis pigmentosa.^{6,8} Our study indicated that the Gly106Arg mutation is also associated with the sectorial phenotype in the Japanese patients. Sectorial retinitis pigmentosa is also caused by other Class II mutations, including mutations in codons 15, 17, 23, 58, and 182.¹²⁻¹⁸ Most of the patients with sectorial retinitis pigmentosa retain good visual acuity.¹²⁻¹⁸ In our study, Patient II-2 had cystoid macular edema and a decrease of visual acuity in his right eye. Sullivan et al¹⁹ reported a 67-year-old woman with an Asn15Ser mutation and macular pigmentary changes whose visual acuity in the left eye was 20/200.

It seems likely that the genetic background of retinitis pigmentosa differs between Japanese and Caucasian populations. However, the Gly106Arg mutation of rhodopsin gene appears to cause sectorial retinitis pigmentosa in Japanese as well as in Caucasians.

References

1. Dryja TP, McGee TL, Reichel E, et al. A point mutation of the rhodopsin gene in one form of retinitis pigmentosa. *Nature* 1990;343:364-6.
2. Kajiwaru K, Hahn LB, Mukai S, Travis GH, Berson EL, Dryja TP. Mutations in the human retinal degeneration slow gene in autosomal dominant retinitis pigmentosa. *Nature* 1991;354:480-3.
3. McLaughlin ME, Sandberg MA, Berson EL, Dryja TP. Recessive mutations in the gene encoding the beta-subunit of rod phosphodiesterase in patients with retinitis pigmentosa. *Nat Genet* 1993;4:130-4.
4. Van Soest S, Westerveld A, de Jong PTV, Bleeker-Wagemakers EM, Bergen AAB. Retinitis pigmentosa : defined from a molecular point of view. *Surv Ophthalmol* 1999;43:321-34.
5. Inglehearn CF, Keen TJ, Bashir R, et al. A completed screen for mutations of the rhodopsin gene in a panel of patients with autosomal dominant retinitis pigmentosa. *Hum Mol Genetics* 1992;1:41-5.
6. Fishman GA, Stone EM, Gilbert LD, Sheffield VC. Ocular findings associated with a rhodopsin gene codon 106 mutation. Glycine - to - arginine change in autosomal dominant retinitis pigmentosa. *Arch Ophthalmol* 1992;110:646-53.
7. Macke JP, Davenport CM, Jacobson SG, et al. Identification of novel rhodopsin mutation responsible for retinitis pigmentosa: implications for the structure and function of rhodopsin. *Am J Hum Genet* 1993;53:80-9.
8. Ayuso C, Reig C, Garcia-Sandoval B, et al. G 106 R rhodopsin mutation is also present in Spanish ADRP patients. *Ophthalmic Genet* 1996;17:95-101.
9. Dryja TP, Hahn LB, Cowley GS, Mc Gee TL, Berson EL. Mutation spectrum of the rhodopsin gene among patients with autosomal dominant retinitis pigmentosa. *Proc Natl Acad Sci USA* 1991;88:9370-4.
10. Sung CH, Schneider BG, Agarwal N, Papermaster DS, Nathans J. Functional heterogeneity of mutant rhodopsin responsible for autosomal dominant retinitis pigmentosa. *Proc Natl Acad Sci USA* 1991;88:8840-4.
11. Sung CH, Davenport CM, Nathans J. Rhodopsin mutation responsible for autosomal dominant retinitis pigmentosa. Clustering of functional classes along the polypeptide chain. *J Biol Chem* 1993;268:26645-9.
12. Stone EM, Kimura AE, Nichols BE, Khadivi P, Fishman GA, Sheffield VC. Regional distribution of retinal degeneration in patients with the proline to histidine mutation in codon 23 of the rhodopsin gene. *Ophthalmology* 1991;98:1806-13.
13. Fujiki K, Hotta Y, Hayakawa M, et al. Point mutation of rhodopsin gene found in Japanese families with autosomal dominant retinitis pigmentosa (ADRP). *Jpn J Hum Genet* 1992;37:125-32.
14. Fishman GA, Stone EM, Sheffield VC, Gilbert LD, Kimura AE. Ocular findings associated with rhodopsin gene codon 17 and codon 182 transition mutations in dominant retinitis pigmentosa. *Arch Ophthalmol* 1992;110:54-62.
15. Hayakawa M, Hotta Y, Imai Y, et al. Clinical features of autosomal dominant retinitis pigmentosa with rhodopsin gene codon 17 mutation and retinal neovascularization in a Japanese patient. *Am J Ophthalmol* 1993;115:168-73.
16. Fishman GA, Stone EM, Gilbert LD, Kenna P, Sheffield VC. Ocular findings associated with a rhodopsin gene codon 58 transversion mutation in autosomal dominant retinitis pigmentosa. *Arch Ophthalmol* 1991;109:1387-93.
17. Fujiki K, Hotta Y, Murakami A, et al. Missense mutation of rhodopsin gene codon 15 found in Japanese autosomal dominant retinitis pigmentosa. *Jpn J Hum Genet* 1995;40:271-7.
18. Yoshii M, Murakami A, Akeo K, et al. Visual function in retinitis pigmentosa related to a codon 15 rhodopsin gene mutation. *Ophthalmic Res* 1998;30:1-10.
19. Sullivan LJ, Makris GS, Dickinson P, et al. A new codon 15 rhodopsin gene mutation in autosomal dominant retinitis pigmentosa is associated with sectorial disease. *Arch Ophthalmol* 1993;111:1512-7.