

# Surgical Excision Versus Laser Photocoagulation for Subfoveal Choroidal Neovascular Membrane with Age-related Macular Degeneration: Comparison of Visual Outcomes

Mitsuko Yuzawa,\* Takako Isomae,\*  
Ryuzaburo Mori,\* Hiroyuki Shimada\* and Izumi Utsunomiya<sup>†</sup>

\*Department of Ophthalmology, Nihon University, Surugadai Hospital,  
Tokyo, Japan; <sup>†</sup>Department of Ophthalmology, Kitazato University, Tokyo, Japan

**Purpose:** This study was designed to compare visual acuity after laser photocoagulation with visual acuity after surgical excision of the subfoveal choroidal neovascular membrane in patients with age-related macular degeneration (AMD).

**Methods:** We studied 54 patients (56 eyes) who underwent laser photocoagulation and 52 patients (52 eyes) who underwent surgical excision for new subfoveal choroidal neovascular membrane occurring with AMD. We compared mean log of minimal angle of resolution (MAR) visual acuity, and the percentages of eyes showing visual improvement and a visual acuity of 0.1 or better, between the two treatment groups at 12 months after treatment. The groups were also compared according to choroidal neovascular membrane size, ie, 1 disc diameter (DD) or smaller vs larger than 1 DD.

**Results:** Mean corrected visual acuity ( $P < .01$ ), percentage of eyes with improved vision ( $P < .01$ ), and percentage with a visual acuity of at least 0.1 ( $P < .01$ ) were higher in surgically treated eyes. The differences in mean log MAR visual acuity and the percentages were significant only for choroidal neovascular membrane of one DD or less in size.

**Conclusions:** Postoperative eyes, especially those with choroidal neovascular membranes 1 DD or less in size, had better visual outcomes. Patients who meet our eligibility criteria, especially with small choroidal neovascular membranes 1 DD or less in size, should undergo surgical excision. **Jpn J Ophthalmol 2001;45:192-198** © 2001 Japanese Ophthalmological Society

**Key Words:** Age-related macular degeneration, laser photocoagulation, subfoveal choroidal neovascular membrane, surgical excision, visual outcome.

## Introduction

The neovascular form of age-related macular degeneration (AMD) is the major cause of blindness in Western countries and its prevalence is rising in Japan. Patients who underwent laser photocoagulation for extrafoveal and juxtafoveal choroidal neovascular membranes with AMD were less likely to suffer severe visual loss than those with untreated eyes

in the Macular Photocoagulation Study (MPS) group.<sup>1,2</sup> The MPS group reported that eyes undergoing laser photocoagulation of subfoveal CNV initially suffered a greater loss in visual acuity than eyes without treatment. However, at 1 year after treatment, treated eyes had lost less visual acuity than untreated eyes and this benefit continued for at least three years.<sup>3</sup> They also reported that eyes with small lesions and moderate or poor visual acuity or those with medium lesions and poor visual acuity had the best visual outcome after treatment.<sup>4</sup> The surgical removal of subfoveal choroidal neovascular membranes using large-flap techniques was introduced by de Juan and Machemer.<sup>5</sup> Later, Thomas and Kaplan

Received: February 28, 2000

Correspondence and reprint requests to: Mitsuko YUZAWA, MD, Department of Ophthalmology, Surugadai Hospital, Nihon University 1-8-13 Surugadai, Kanda, Chiyoda-ku, Tokyo 101-8317, Japan

reported excellent results in two patients with presumed ocular histoplasmosis syndrome using a small retinotomy technique.<sup>6</sup> When this procedure was applied to subfoveal choroidal neovascular membranes with AMD, the results were disappointing.

Nevertheless, these two methods are now the most commonly performed treatment for subfoveal choroidal neovascular membrane.

We compared the visual outcome of laser photocoagulation vs surgical excision for subfoveal choroidal neovascular membranes at 12 months after treatment, as well as the visual outcome according to choroidal neovascular membrane size within the same treatment group. The results may be useful in selecting the optimal treatment method for subfoveal choroidal neovascular membranes with AMD.

### Materials and Methods

Eligibility criteria for subfoveal choroidal neovascular membranes prior to treatment were: (1) newly formed subfoveal choroidal neovascular membranes with well-defined, demarcated borders on fluorescein angiography, the largest diameter of the choroidal neovascular membrane being 3 disc diameters (DDs) or less as compared with the vertical diameter of the individual's optic disc, (2) visual acuity of 0.3 or less, and (3) a serous retinal detachment and/or subretinal bleeding extending over and around the choroidal neovascular membrane.

Laser photocoagulation was performed on 51 eyes of 49 patients who met the eligibility criteria between September 1991 and February 1995. Surgical excision was subsequently recommended at our hospital. However, if patients refused surgery, laser photocoagulation was performed. Fifty-two eyes of 52 patients underwent surgical excision between March 1995 and January 1998. Laser photocoagulation was performed during the same period on 11 eyes of 11 patients. Two patients who had undergone laser photocoagulation died before 12 months had elapsed and another 4 did not return for the 12-month follow-up examination. The 52 patients who had undergone excision came back at 12 months. Therefore, 56 post-photocoagulated eyes of 54 patients and 52 postoperative eyes of 52 patients were available for study.

Laser photocoagulation was based on a previously described approach.<sup>8</sup> Briefly, photocoagulation was performed using a yellow and/or red wavelength argon dye laser. Photocoagulation burns 100  $\mu\text{m}$  to 200  $\mu\text{m}$  in size were targeted on the area surrounding the choroidal neovascular membrane, which was cov-

ered by a whitish fusion of scars. The surgical technique followed the method reported by Thomas and Kaplan.<sup>6</sup> First, a pars plana vitrectomy was performed, followed by complete posterior hyaloid separation using a soft-tipped needle. A retinotomy was made and balanced salt solution was injected into the subretinal space via the retinotomy. A subretinal spatula was used to separate adhesions between the retinal pigment epithelium and the choroidal neovascular membrane. The membrane was then extracted, using subretinal forceps, through the retinotomy. Fluid-air exchange and air tamponade were performed. Two eyes had pseudophakia at operation. Lens extraction and artificial lens implantation were performed simultaneously in 43 eyes and performed subsequently in 3 eyes within 1 year after the surgical excision. After treatment, regular follow-up observations were made at 1 week, 1 month, 2 months, 3 months, 6 months, 9 months, and 12 months. When persistence or recurrence of choroidal neovascular membrane was suspected, both color photography and fluorescein angiography were performed. Additional laser photocoagulation or surgical excision was performed when leakage from the membrane was prominent in the late phase of fluorescein angiography and when the choroidal neovascular membrane was not consistent with the fixation point.

We compared mean best-corrected visual acuity, percentage of eyes with improved vision and percentage of eyes showing 0.1 or better visual activity, at 12 months, between the two treatment groups. The same comparison of visual outcome was performed on the two groups defined according to choroidal neovascular membrane size before treatment, ie, 1 DD or less vs more than 1 DD. The comparison of mean best-corrected visual acuity before and 12 months after treatment was performed within each treatment group. Changes in best-corrected visual acuity at the 12-month follow-up examination, as compared with that before treatment, were expressed as the log of the minimal angle of resolution (log MAR). A marked change was defined as a difference of 0.2 or more units. The unpaired *t*-test was used to compare pretreatment factors and the visual outcome between treatment groups. The paired *t*-test was used to compare visual change before and 12 months after treatment within the same group.

### Results

Preoperative factors did not differ significantly between the 54 patients receiving laser photocoagula-

**Table 1.** Pretreatment Factors in Both Groups

	Laser Photocoagulation	Surgical Excision	<i>P</i> Value
All eyes			
Mean age	66.9 ± 9.3	66.0 ± 8.0	.60
Mean CNM* size (DD)†	1.16 ± 0.6	1.02 ± 0.46	.16
Mean best-corrected visual acuity	1.17 ± 0.35	1.19 ± 0.40	.99
Eyes with CNMs > 1 DD			
Mean age	68.6 ± 10.1	68.0 ± 7.6	.80
Mean CNM size (DD)	1.54 ± 0.52	1.47 ± 0.40	.78
Mean best-corrected visual acuity	1.24 ± 0.32	1.42 ± 0.41	.09
Eyes with CNMs of ≤ 1 DD			
Mean age	64.7 ± 7.8	64.8 ± 8.2	.94
Mean CNM size (DD)	0.65 ± 0.16	0.73 ± 0.19	.11
Mean best-corrected visual acuity	1.07 ± 0.37	1.04 ± 0.32	.79

\*CNM: Choroidal neovascular membrane.

†DD: Disc diameter.

tion and the 52 who underwent surgical excision (age,  $P = .60$ ; choroidal neovascular membrane size,  $P = .16$ ; best-corrected visual acuity given by log MAR,  $P = .99$ ). The 56 eyes that had undergone laser photocoagulation, and 12-month follow-up examination comprised 32 eyes with choroidal neovascular membranes exceeding 1 DD and 24 eyes with choroidal neovascular membranes of 1 DD or less. The surgical excision group consisted of 52 eyes, 20 with choroidal neovascular membranes exceeding 1 DD and 32 with choroidal neovascular membranes of 1 DD or less. Pretreatment factors did not differ significantly based on choroidal neovascular membrane size (Table 1).

For the 32 eyes undergoing laser photocoagulation for choroidal neovascular membranes exceeding 1 DD in size, the mean best-corrected visual acuity was  $1.24 \pm 0.32$  and 25% (9 eyes) had a visual acuity of 0.1 or better. One of the 9 eyes maintained a visual acuity of 0.3 or higher. For the 24 eyes that underwent laser photocoagulation for subfoveal choroidal neovascular membranes of 1 DD or less, the mean best-corrected visual acuity was  $1.07 \pm 0.37$  and 54% (13 eyes) had a visual acuity of 0.1 or better. Two of the 13 eyes maintained an acuity of 0.3 or better. Among the 20 eyes that had undergone surgical excision of a subfoveal choroidal neovascular membrane exceeding 1 DD, the mean best-corrected visual acuity was  $1.42 \pm 0.41$  and 26% (5 eyes) had a visual acuity of 0.1 or better. There were none with an acuity of 0.3 or better. The mean best visual acuity was  $1.04 \pm 0.32$ , and 53% (16 eyes) had a visual acuity of 0.1 or better among the 32 eyes in which surgical excision of a subfoveal choroidal neovascular membrane, 1 DD or less in size, had been per-

formed. Three of the 16 eyes had a visual acuity of 0.3 or better. Pretreatment factors did not differ significantly between the two groups defined according to choroidal neovascular membrane size (Table 1).

### Visual Outcomes of Laser

#### Photocoagulated Eyes at 12-Month Follow-up

Persistence or recurrence was detected in 5 eyes and additional laser photocoagulation was performed in 4 of these 5 eyes during the 12-month follow-up period. The mean best-corrected visual acuity of the 56 laser photocoagulated eyes was  $1.11 \pm 0.33$ . The mean best-corrected visual acuity had not improved at 12 months as compared with the pretreatment visual acuity ( $P = .16$ ). Percentages of eyes with improved visual acuity, no change, and deterioration were 28% (16 eyes), 52% (29 eyes) and 20% (11 eyes), respectively. The percentage of eyes with a visual acuity of 0.1 or better was 39% (22 eyes). Of these 22 eyes, 5 had an acuity of 0.3 or better.

The mean best-corrected visual acuity of the 32 eyes with choroidal neovascular membranes exceeding 1 DD was  $1.16 \pm 0.33$ , not a statistically significant difference ( $P = .14$ ) as compared with that prior to photocoagulation. Percentages of eyes with improved visual acuity, no change and deterioration were 25% (8 eyes), 59% (19 eyes), and 16% (5 eyes), respectively. Ten (31%) eyes had a visual acuity of 0.1 or better. Of these 10 eyes, 3 had a visual acuity of 0.3 or better.

The mean best-corrected visual acuity of the 24 eyes with a choroidal neovascular membrane of one DD or less was  $1.03 \pm 0.31$ , not a statistically significant difference ( $P = .65$ ) as compared with that prior

**Table 2.** Comparison of Visual Outcomes

	Photocoagulation	Surgical Excision	P Value
Total eyes			
Mean best-corrected visual acuity	1.11 ± 0.33	0.87 ± 0.38	<.01
Improved visual acuity	16 (28%)	34 (65%)	<.01
Visual acuity of 0.1 or better	22 (39%)	33 (63%)	<.01
Eyes with CNM* > 1 DD <sup>†</sup>			
Mean best-corrected visual acuity	1.16 ± 0.33	1.09 ± 0.33	.40
Improved visual acuity	8 (25%)	12 (60%)	<.01
Visual acuity of 0.1 or better	10 (31%)	9 (45%)	.31
Eyes with CNM of ≤ 1 DD			
Mean best-corrected visual acuity	1.03 ± 0.31	0.73 ± 0.35	<.01
Improved visual acuity	8 (33%)	22 (69%)	.01
Visual acuity of 0.1 or better	12 (50%)	24 (75%)	.04

\*CNM: Choroidal neovascular membrane.

<sup>†</sup>DD: Disc diameter.

to photocoagulation. Percentages of eyes with improved visual acuity, no change and deterioration were 33% (8 eyes), 42% (10 eyes) and 25% (6 eyes), respectively. Twelve (50%) eyes had a visual acuity of 0.1 or better. Of these 12 eyes, 2 had a visual acuity of 0.3 or better (Table 2).

#### *Visual Outcomes of Surgically Treated Eyes at 12-Month Follow-up*

Two eyes underwent reoperation for complicated retinal detachment. Recurrences were demonstrated in 4 eyes and additional surgical excision was performed in 1 eye. The mean best-corrected visual acuity of the 52 surgically treated eyes was  $0.87 \pm 0.38$  and the improvement at 12 months was significant as compared to the visual acuity before treatment ( $P < .01$ ). Percentages of eyes with improved visual acuity, no change and deterioration were 65% (34 eyes), 16% (8 eyes), and 19% (10 eyes), respectively. Percentages of eyes with visual acuities of 0.1 or better and 0.3 or better were 63% (33 eyes) and 29% (15 eyes), respectively. The mean best-corrected visual acuity of the 20 eyes with choroidal neovascular membranes exceeding 1 DD was  $1.09 \pm 0.31$ , a statistically significant improvement as compared with the preoperative visual acuity ( $P < .01$ ). Percentages of eyes with improved visual acuity, no change, and deterioration were 60% (12 eyes), 20% (4 eyes), and 20% (4 eyes), respectively. Nine (45%) eyes had a visual acuity of 0.1 or better but none was 0.3 or better.

The mean best-corrected visual acuity of 32 eyes with a choroidal neovascular membrane of 1 DD or less was  $0.73 \pm 0.35$ , a statistically significant improvement as compared with the mean preoperative acuity ( $P < .01$ ). Percentages of eyes with improved

visual acuity, no change and deterioration were 69% (22 eyes), 12% (4 eyes), and 19% (6 eyes), respectively. Twenty-four (75%) eyes had a visual acuity of 0.1 or better. Of these 24 eyes, 15 had a visual acuity of 0.3 or better (Table 2).

#### *Comparison of Visual Outcomes in Laser Photocoagulated and Surgery-Treated Eyes at 12-Month Follow-up*

The mean best-corrected visual acuity of the 52 eyes that underwent surgical excision was better than that of the 56 laser photocoagulated eyes ( $P < .01$ ). Although a statistically significant difference was demonstrated for eyes with a choroidal neovascular membrane size of 1 DD or less ( $P < .01$ ), the difference did not reach statistical significance for choroidal neovascular membranes exceeding 1 DD in size ( $P = .40$ ).

The percentage of eyes with improved visual acuity at the the 12-month follow-up examination was higher when surgical excision was performed ( $P < .01$ ). A highly significant improvement was obtained for both choroidal neovascular membrane exceeding one DD and those 1 DD or less in size ( $P = .01$ ). The percentage with a visual acuity of at least 0.1 was higher among eyes that had undergone surgical excision ( $P < .01$ ). However, a statistically significant difference was obtained only when the choroidal neovascular membrane was 1 DD or less in size ( $P = 0.04$ ) (Table 2).

## **Discussion**

Although laser photocoagulation for subfoveal choroidal neovascular membrane with AMD was re-

ported to be useful in cases with a small lesion and moderate or poor visual acuity, and in cases with a medium lesion and poor visual acuity, the visual outcomes obtained were disappointing.<sup>4</sup> Therefore, several interventions have been attempted to obtain a better visual prognosis. Results of surgical removal of subfoveal choroidal neovascular membrane reported in the United States were also somewhat disappointing. However, a small number of carefully selected cases did obtain good visual acuity.<sup>7,12</sup> We began using laser photocoagulation for subfoveal choroidal neovascular membrane with AMD in 1991. As surgical intervention gained widespread popularity, it became our first choice from 1995, unless the patient stated a preference for laser photocoagulation.

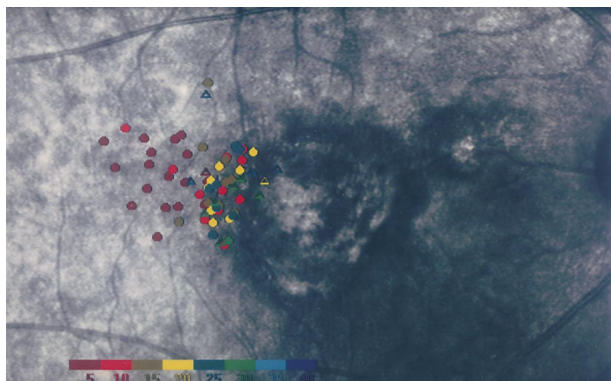
It might not be useful to compare the visual outcomes of eyes that underwent laser photocoagulation in our study with those reported by the MPS study because eligibility criteria and methods of visual acuity measurement were different. However, when we classified our cases according to visual acuity and choroidal neovascular membrane size following the MPS groupings to predict visual outcome (taking choroidal neovascular membrane size in our study to be equivalent to the lesion size measurement used in the MPS study), we found that 33 of the 56 eyes (59%) belonged to group A, which MPS groups classified as having the best visual prognosis, ie, small lesion and moderate or poor initial visual acuity. Only 1 eye (2%) belonged to group D. This group had the worst visual prognosis, ie, substantial loss of visual acuity after photocoagulation. In contrast, 28% and 17% of 372 eyes in the MPS Study belonged to groups A and D, respectively.<sup>4</sup> In addition, the median choroidal neovascular membrane size in 24 eyes with choroidal neovascular membrane of 1 DD or less, corresponding to one MPS disc area, was small, 0.69 DD. A short distance between the margin of the choroidal neovascular membrane and the fovea was one of the factors predicting good post-coagulation visual acuity.<sup>8</sup> This explains why visual outcomes were apparently better in our study than those reported by the MPS.

We compared visual outcomes at 12 months after laser photocoagulation or surgical excision of subfoveal choroidal neovascular membrane. Mean corrected visual acuity, as well as percentages with improved vision and with a visual acuity of at least 0.1 were better in eyes that had undergone surgical excision than in those that had undergone laser photocoagulation. The same tendency was recognized in eyes with choroidal neovascular membrane of 1 DD


or less. However, when the choroidal neovascular membranes exceeded 1 DD in size, neither mean corrected visual acuity nor the percentage of eyes with a visual acuity of at least 0.1 differed significantly. These results were thought to be attributable to differences in the severity and extent of damage produced by the treatment and also to degeneration involving the choroidal neovascular membrane in the process of choroidal neovascular membrane development. In our study, photocoagulation burns 100  $\mu\text{m}$  to 200  $\mu\text{m}$  in size were targeted in the area surrounding the choroidal neovascular membrane, which was covered by a whitish fusion of scars. After absorption of the exudation and/or hemorrhage produced by photocoagulation, extrafixation was performed adjacent to the absolute scotoma corresponding to the laser scar (Figure 1).<sup>8</sup>

On the other hand, choriocapillaris atrophy, possibly due to mechanical trauma to this vascular structure during surgical manipulation of the subfoveal choroidal neovascular membrane,<sup>13</sup> and severe damage to the choroid and retina in the pathway of the extracted choroidal neovascular membrane,<sup>14</sup> were reported. With surgical excision, retinal pigment epithelium defects are inevitable at the subretinal choroidal neovascular membrane ingrowth site.<sup>15</sup> However, fixation within the area of damaged retinal pigment epithelium corresponding to the choroidal neovascular membrane appears to be possible when the degree of damage is mild as shown in this case report. Rarely, a patients with AMD undergoing surgical excision can still fixate within the area from which the choroidal neovascular membrane was removed.<sup>16,17</sup>


Eyes that can achieve fixation from the area previously occupied by the choroidal neovascular membrane can obtain better visual acuity after surgical excision. Smaller, subsensory retinal choroidal neovascular membranes are likely to be consistent with this condition because the damaged area is small and the degree of damage is mild (Figure 2). Even when an absolute scotoma corresponding to the choroidal neovascular membrane area develops postoperatively, the distance between the newly formed fixation point adjacent to the absolute scotoma and the fovea is apparently shorter than that after photocoagulation. In normal eyes, visual acuity is 100% in the fovea. Moving away from the fovea, it decreases rapidly at first and then slowly. At 1° (300  $\mu\text{m}$ ) and at 5° (1500  $\mu\text{m}$ ) away from the fovea, visual acuity declined to 60% and 30%, respectively. Therefore, an extra 100  $\mu\text{m}$  to 200  $\mu\text{m}$  of photocoagulation scar of the retina surrounding the choroidal neovascular membrane has an effect on visual acuity.<sup>18</sup>



**Figure 1.** Microperimetry after laser photocoagulation shows fixation adjacent to temporal margin of laser scar including fovea in 61-year-old woman. Postoperative visual acuity achieved was 0.4.



**Figure 2.** Microperimetry after surgical excision shows fixation within diseased area from which choroidal neovascular membrane was removed in 55-year-old woman. Postoperative visual acuity achieved was 1.0.



**Figure 3.** Microperimetry after surgical excision shows fixation adjacent to large scar in 67-year-old woman. Postoperative visual acuity achieved was 0.1.

Damage to both photoreceptors and the retinal pigment epithelium surrounding the choroidal neovascular membrane were thought to be more severe and extensive as the choroidal neovascular membrane developed. In addition, removal of the retinal pigment epithelium including the ingrowth site of the choroidal neovascular membrane can involve an extensive area at the time of excision. In such cases, choriocapillaris atrophy will be severe after excision. Extra fixation, achieving better visual acuity within the choroidal neovascular membrane area after surgery, is more difficult than in eyes with small choroidal neovascular membrane. The absolute scotoma corresponding to the choroidal neovascular membrane will be larger and the newly formed fixation point from the fovea longer (Figure 3). Fixation will be impossible in some cases. In the area further away from the fovea, visual acuity decreases slowly to 10% near the optic disc. Therefore, the extra 100  $\mu\text{m}$  to 200  $\mu\text{m}$  of photocoagulation scar of retina surrounding the choroidal neovascular membrane has little effect on visual acuity. Neither the mean best-corrected visual acuity nor the percentage of eyes with a visual acuity of 0.1 or better differed significantly between surgical excision and photocoagulation when the choroidal neovascular membrane exceeded 1 DD in size.

Clinicopathologic studies have shown that surgically excised choroidal neovascular membrane contains retinal pigment epithelial and subsensory retinal components and that some photoreceptor cell layer loss occurs.<sup>18,19</sup> Although localization of a choroidal neovascular membrane, whether it is subretinal or subretinal pigment epithelium, is often difficult to determine it can sometimes be achieved by considering macular findings such as a subretinal pigmented halo or plaque occurring around the site of origin of the choroidal neovascular membrane's sharply defined borders,<sup>21,22</sup> and a plaque-like elevation known as a neovascular complex,<sup>21</sup> as well as patient age.<sup>21,22</sup> From our present results, we conclude that patients who meet our criteria, especially those with choroidal neovascular membrane no larger than 1 DD in maximum dimension, should undergo surgical excision rather than laser photocoagulation, as this will provide the best chance of maintaining improved visual acuity. A randomized, prospective clinical trial should be done on a larger scale to confirm our results.

This study was supported by grants from the Ministry of Health and Welfare of Japan, Health Sciences Research Grants (no. 10-Organ Transplantation-007), and Research on Eye and Ear Sciences, Immunology, Allergy and Organ Transplantation, and from

the Research Committee on Chorioretinal Degeneration of the Ministry of Health and Welfare.

## References

1. Macular Photocoagulation Study Group. Argon laser photocoagulation for neovascular maculopathy: three-year results from randomized clinical trials. *Arch Ophthalmol* 1986;104:694-701.
2. Macular Photocoagulation Study Group. Krypton laser photocoagulation for neovascular lesions of age-related macular degeneration. *Arch Ophthalmol* 1990;108:816-24.
3. Macular Photocoagulation Study Group. Laser photocoagulation of subfoveal neovascular lesions in age-related macular degeneration. *Arch Ophthalmol* 1991;109:1220-31.
4. Macular Photocoagulation Study Group. Visual outcome after laser photocoagulation for subfoveal choroidal neovascularization secondary to age-related macular degeneration. *Arch Ophthalmol* 1994;112:48-8.
5. de Juan E Jr, Machemer R. Vitreous surgery for hemorrhage and fibrous complications of age-related macular degeneration. *Am J Ophthalmol* 1998;105:25-9.
6. Thomas MA, Kaplan HJ. Surgical removal of subfoveal neovascularization in the presumed ocular histoplasmosis syndrome. *Am J Ophthalmol* 1991;111:1-7.
7. Thomas MA, Dickinson JD, Melberg NS, et al. Visual results after surgical removal of subfoveal choroidal neovascular membranes. *Ophthalmology* 1996;103:1384-94.
8. Yuzawa M, Tamakoshi A, Ueha M, et al. Factors influencing visual acuity for subfoveal choroidal neovascularization of exudative age-related macular degeneration. *Ophthalmology* 1996;103:2037-41.
9. Isomae T, Shimada H, Nakajima M, et al. Comparison between indocyanine green angiography and outcome of surgical removal of choroidal neovascular membrane age-related macular degeneration. *Nippon Ganka Gakkai Zasshi (J Jpn Ophthalmol Soc)* 1999;103:741-7.
10. Isomae T, Shimada H, Fujita K, et al. Results of surgical removal of choroidal neovascular membrane of different etiologies. *Rinsho Ganka (Jpn J Clin Ophthalmol)* 1999;53:1069-73.
11. Isomae T, Shimada H, Nakajima M, et al. The study of persistence and recurrence after surgical removal of choroidal neovascular membrane. *Nihon Ganka Kyo (Folia Ophthalmol Jpn)* 1998;49:773-6.
12. Ormerod LD, Puklin JE, Frank RN. Long-term outcomes after the surgical removal of advanced subfoveal neovascular membranes in age-related macular degeneration. *Ophthalmology* 1994;101:1201-10.
13. Desai VN, Priore LVD, Kaplan HJ, et al. Choriocapillaris atrophy after submacular surgery in presumed ocular histoplasmosis syndrome. *Arch Ophthalmol* 1995;113:409-10.
14. Tsujikawa M, Sawa M, Lewis JH, et al. Chorioretinal damage caused by the excision of choroidal neovascularization. *Am J Ophthalmol* 1998;126:348-57.
15. Melberg NS, Thomas MA, Burgess DB. The surgical removal of subfoveal choroidal neovascularization. Ingrowth site as a predictor of visual outcome. *Retina* 1995;16:190-5.
16. Tsujikawa M, Tsujikawa K, Lesis JM, et al. Change in retinal sensitivity due to excision of choroidal neovascularization and its influence on visual acuity outcome. *Retina* 1999;19:135-40.
17. Loewenstein A, Sunnes JS, Bressler NM, et al. Scanning laser ophthalmoscope fundus perimetry after surgery for choroidal neovascularization. *Am J Ophthalmol* 1998;125:657-65.
18. Westheimer G. Visual acuity. In: Hart WM, ed. *Adler's physiology of the eye*. 9th ed. St. Louis: CV Mosby; 1994:531-47.
19. Lee BL, Lim J, Grossniklaus HE. Clinicopathologic features of indocyanine green angiography images, surgically excised choroidal neovascular membranes. *Retina* 1996;16:64-9.
20. Hsu JK, Thomas M, Ibanez H, et al. Clinicopathologic studies of an eye after submacular membranectomy for choroidal neovascularization. *Retina* 1995;15:43-52.
21. Gass JDM. Biomicroscopic and histopathologic consideration regarding the feasibility of surgical excision of subfoveal neovascular membranes. *Am J Ophthalmol* 1994;118:285-98.
22. Grossniklaus HE, Gass DM. Clinicopathologic correlation of surgically excised type 1 and type 2 submacular choroidal neovascular membranes. *Am J Ophthalmol* 1998;126:59-63.