

## Ligneous Conjunctivitis: A Case Report

Mikiko Shimabukuro, Naoki Iwasaki, Yasunobu Nagae,  
Yayoi Nakagawa, Yasumasa Ohtori, Yoshitsugu Inoue and Yasuo Tano

*Department of Ophthalmology, Osaka University Medical School, Osaka, Japan*

**Background:** Ligneous conjunctivitis is a rare condition characterized by chronic, recurrent conjunctivitis associated with pseudomembrane, and it may involve other mucous membranes in the mouth, nasopharynx, trachea, and vagina. We examined and treated a case of presumed ligneous conjunctivitis.

**Case:** The patient was a 10-year-old boy. His chief complaints were visual impairment, discomfort, and discharge, but no itching in his eyes. His upper eyelids appeared thick without swelling. He had a past history of surgery for lid entropion. His two siblings had similar follicular conjunctivitis.

**Observations:** This case exhibited several characteristics of ligneous conjunctivitis, such as large follicles, recurrent pseudomembrane and normal level IgE in the serum. Indispensable characteristics of vernal keratoconjunctivitis, strong itching, and extensive papillary formation, were not found. In spite of the lack of woody hardness of the conjunctiva, other clinical findings led to the diagnosis of ligneous conjunctivitis. Definite histological diagnosis was not obtained, because of the lack of common histological characteristics among previously reported cases with ligneous conjunctivitis. The boy had developed corticosteroid glaucoma after instillation of dexamethasone 0.1% for 7 months at a previous time. We successfully treated this case with combined instillation of fluorometholon and cyclosporin after trabeculotomy.

**Conclusions:** Ligneous conjunctivitis must be considered as one type of differential diagnosis of vernal keratoconjunctivitis. Cyclosporin is an effective alternative for the treatment of ligneous conjunctivitis, especially in a case with a possible history of corticosteroid glaucoma. *Jpn J Ophthalmol* 2001;45:375-377 © 2001 Japanese Ophthalmological Society

**Key Words:** Corticosteroid glaucoma, ligneous conjunctivitis, pseudomembrane.

### Introduction

Ligneous conjunctivitis is a rare disorder characterized by chronic and recurrent conjunctival pseudomembranous and membranous lesions. In 1847, Bouisson described this type of conjunctivitis for the first time.<sup>1</sup> Aoki reported a case of ligneous conjunctivitis in Japan.<sup>2</sup> The disease classically presents with the appearance of thickened, "wood-like" membranes covering the tarsal conjunctiva. Other mucous membranes sometimes become involved, including mouth, nasopharynx, trachea, and vagina. The onset is usually in childhood, and it is more common in females, with

a sex ratio of 3:1. The pathogenesis remains unknown, but it has been suggested that previous surgery<sup>3,4</sup> and genetic background are related to this rare clinical entity. This time we examined and treated a case of clinically diagnosed ligneous conjunctivitis combined with corticosteroid glaucoma.

### Case Report

The patient, a 10-year-old boy, visited our hospital for the first time in December 1996. His chief complaints were visual impairment, discomfort, and discharge, but no itching in his eyes. In May 1996, he had been diagnosed at another clinic as having vernal keratoconjunctivitis and had been treated with topical dexamethasone 0.1%, anti-allergic drugs, and hyaluronic acid. In October 1996, his mother discovered he had difficulty with far vision.

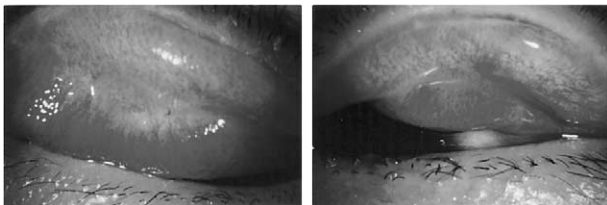
Received: December 27, 1999

Correspondence and reprint requests to: Mikiko SHIMABUKURO, MD, Department of Ophthalmology, Kansai Rousai Hospital, 3-1-69, Inabasou, Amagasaki-city, Hyogo 660-8511, Japan

He had undergone a buccal mucous membrane autograft for lid entropion on his upper and lower palpebral conjunctiva bilaterally at 6 years of age. He also had developed chronic otitis media from the same age. However, there was no pseudomembrane and no indication of allergy in his nasopharynx. He was the second child of five siblings. Follicular conjunctivitis was also found in his younger sister and brother.

The boy's visual acuity in the right eye was 20/60, and in the left, 4/200. Intraocular pressure (IOP) was 48 mm Hg in both eyes. The bilateral chamber angles were open without peripheral anterior synechia and pigmentation. The upper eyelids appeared thick without swelling. A yellowish-white membrane-like structure adhering to the underlying tarsal conjunctiva was especially prominent on the site of the eyelid margin in both eyes (Figure 1). Hyperemia and follicles existed near the fornix. There were cracks at both eyelid margins along the dermato-conjunctival junction, and plaque was observed at the upper eyelid margin of the right eye. He also had superficial punctate keratopathy (SPK) and corneal epithelial edema bilaterally. It was difficult to examine the detail of the ocular fundi because of hazy cornea, but excavation of the optic nerve head was prominent ( $C/D > 0.8$ ). Goldmann perimetry revealed concentric visual field contraction within  $10^\circ$  in both eyes. Laboratory data showed no elevation of serum IgE.

As corticosteroid glaucoma was suspected at the first visit, we stopped dexamethasone 0.1% and started to treat him with full medication for glaucoma in both eyes. Also suspecting ligneous conjunctivitis, we started to apply topical cyclosporin 0.1%. However, the medication for glaucoma was ineffective and his ocular pressure remained over 40 mm Hg. On December 12, trabeculotomy was performed on both eyes. Following the operation, IOP was drastically reduced to 10 mm Hg or lower. After removal of bilateral pseudomembrane and plaque three times in the right eye, large follicles were visible on the tarsal conjunctiva; however, recurrent pseudomembrane covered these follicles repeatedly in 2-7 days. About 5




**Figure 1.** Conjunctiva with pseudomembrane in 10-year-old patient exhibiting characteristics of ligneous conjunctivitis.

weeks after trabeculotomy, the worsening of SPK was suppressed by changing the medication from diclofenac sodium to fluorometholon 0.1%. The visual field recovered partially, especially in the right eye. The instillation of fluorometholon 0.1% and cyclosporin 0.1% has been continued, and the pseudomembrane and SPK have been reduced gradually. Three years after trabeculotomy, visual acuity remained at 20/25 and IOP was 15 mm Hg in both eyes. Histopathological examinations showed that the pseudomembrane consisted of vacuolated stratified squamous epithelium and contained a few infiltrating inflammatory cells. It was stained partially positive by Alcian blue, indicating that it contained some acid mucopolysaccharides (Figure 2). Immunofluorescent staining tests demonstrated that all the IgG, IgE, fibrin, and fibrinogen were negative. Electron microscopy showed  $\beta$ -glycogen particles and vacuoles in a stratified squamous epithelium.

## Discussion

We examined a case of clinically diagnosed ligneous conjunctivitis. Our case had a past history of surgery for lid entropion. Two of his siblings had similar follicular conjunctivitis. Also, this case exhibits several characteristics of ligneous conjunctivitis, such as large follicles, recurrent pseudomembrane and normal level IgE in the serum. Indispensable characteristics of vernal keratoconjunctivitis, strong itching, and extensive papillar formation were not found in this case. In spite of the lack of woody hardness of the conjunctiva, other clinical findings led to the di-



**Figure 2.** Histopathological examinations showed that pseudomembrane consisted of vacuolated stratified squamous epithelium and contained a few infiltrating inflammatory cells. It was stained partially by Alcian blue, indicating that it contained some acid mucopolysaccharides.

agnosis of ligneous conjunctivitis. Histologically definite diagnosis of ligneous conjunctivitis is difficult because there were some discrepancies even in the histopathological findings of previously reported cases of ligneous conjunctivitis.<sup>5,6</sup> Corticosteroid glaucoma is strongly suspected because of this subject's past history of instillation of dexamethasone 0.1% for 7 months and his open chamber angle without peripheral anterior synechia and pigmentation. It has been reported that cyclosporin is an effective alternative for the treatment of ligneous conjunctivitis.<sup>5</sup> The instillation of fluorometholon 0.1% and cyclosporin 0.1% have been continued in our case, and pseudomembrane and SPK have been gradually reduced. The combination of corticosteroids and cyclosporin is considered to be more effective and safer than only corticosteroids for ligneous conjunctivitis. Because we could reduce the amount of corticosteroid being prescribed in this combination, the danger of inducing corticosteroid glaucoma was less-

ened. Great care must be taken in cases treated with corticosteroids, especially in young patients.<sup>7</sup>

## References

1. Bouisson M. Ophthalmie sur aigue avec formation de pseudomembranes a la surface de la conjunctive. *Ann Oculist* 1847;17:100-4.
2. Aoki K. A case with ligneous conjunctivitis. *Rinsho Ganka (Jpn J Clin Ophthalmol)* 1982;36:1444-5.
3. Schwartz GS, Holland EJ. Introduction of ligneous conjunctivitis by conjunctival surgery. *Am J Ophthalmol* 1995;120:253-4.
4. Bierly JR, Blandford DL, Weeks JA, Baker RS. Ligneous conjunctivitis as a complication following strabismus surgery. *J Pediatr Ophthalmol Strabismus* 1994;31:99-103.
5. Holland EJ, Chan C, Kuwabara T, Palestine AG, Rowsey JJ, Nussenblatt PB. Immunohistologic findings and results of treatment with cyclosporin in ligneous conjunctivitis. *Am J Ophthalmol* 1989;107:160-6.
6. Hidayat AA, Riddle PJ. Ligneous conjunctivitis. A clinicopathologic study of 17 cases. *Ophthalmology* 1987;94:949-59.
7. Ohji M, Kinoshita S, Ohmi E, Kuwayama Y. Marked intraocular pressure response to instillation of corticosteroids in children. *Am J Ophthalmol* 1991;112:450-4.