

# Rapid Injection of Indocyanine Green Dye for Evaluation of Choroidal Venous Circulation

Kiyoshi Kano, Takeya Kohno, Tokuhiko Miki and Kunihiro Shiraki

*Department of Ophthalmology,  
Osaka City University Graduate School of Medicine, Osaka, Japan*

**Purpose:** The purpose of this study was to investigate the effects of rapid intravenous administration of a small bolus of indocyanine green (ICG) dye on early phase findings of ICG angiography.

**Methods:** Rabbit eyes were used. Ten normal eyes, 5 eyes with occlusion of vortex veins, and 5 eyes with chorioretinal atrophy were examined by ICG angiography, and early-phase findings after a rapid injection of a small bolus of dye were compared with those obtained with an ordinary injection.

**Results:** In normal eyes, after the rapid injection it was possible to visualize *some* small bright fluorescent boluses in the choroidal veins from 6 to 12 seconds after injection, while with the ordinary injection they were unclear. In eyes with occlusion of vortex veins, the rapid injection resulted in visualization of the choroidal veins with delayed filling against the background, and the region of the choroidal veins with delayed filling could easily be determined. In eyes with chorioretinal atrophy, only the rapid injection clearly revealed the choroidal veins with delayed filling.

**Conclusions:** The rapid injection made it possible to detect the choroidal veins with delayed filling that were not clearly and easily visible using an ordinary injection. Rapid injection of ICG dye is useful for a detailed examination of choroidal circulation. **Jpn J Ophthalmol 2001;45:453–462** © 2001 Japanese Ophthalmological Society

**Key Words:** Choroidal circulation, indocyanine green angiography, rapid dye injection.

## Introduction

Indocyanine green (ICG) angiography has made possible detailed examination of various chorioretinal lesions.<sup>1–4</sup> However, it is often difficult to detect in detail changes in early phase findings because vascular images overlap one another due to the three-dimensional structure of the choroidal vessels, and because inflow of the dye into the choroid is very fast. Thus, additional analysis methods, such as the subtraction method, a computer-assisted method of image analysis, have been introduced.<sup>5–8</sup> However, they are technically elaborate and time-consuming.

Prunte and Flammer<sup>9</sup> reported that delayed filling of choroidal arteries and choriocapillaris and congestion of choroidal veins were delineated using intravenous administration of a small bolus of ICG dye, in patients with central serous chorioretinopathy.

In the present study, we examined the usefulness of rapid intravenous administration of a very small bolus of ICG dye for ICG angiography applied to experimentally induced choroidal lesions.<sup>10–13</sup>

## Materials and Methods

### Animals

Only 1 eye of each rabbit was used for experiment. In total, 20 eyes of 20 adult rabbits (15 pigmented, 5 albino) weighing 1.5 to 3.0 kg were used. These eyes showed no abnormalities on ophthalmoscopy. We adhered to the guidelines described in the ARVO

Received: May 27, 1999

Correspondence and reprint requests to: Kiyoshi KANO, MD, Department of Ophthalmology, Osaka City General Hospital, 2-12-32 Miyakojima-Hondori, Miyakojima-Ku, Osaka 534-0021, Japan

Statement for the Use of Animals in Ophthalmic and Vision Research.

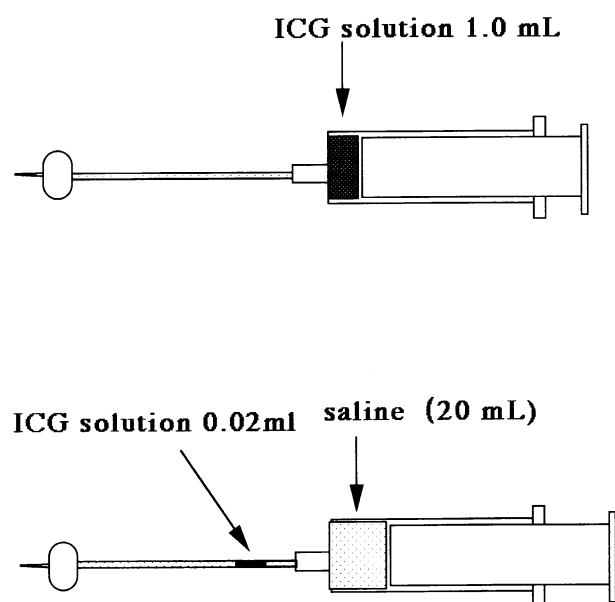
### *Preparation of Chorioretinal Lesions*

**Vortex vein occlusion.** The 5 albino rabbits were used. After general anesthesia was induced with 30 to 35 mg/kg of intravenously injected sodium pentobarbital (Nembutal®; Dainippon, Osaka), the vortex veins of the right eye were approached through a limbal conjunctival incision, and two veins in each eye were ligated in stages with 6-0 nylon thread. The left eye remained intact.

**Chorioretinal atrophy.** Five pigmented rabbits were used. Under general anesthesia as described above, the rabbits were intravenously injected with 20 mg/kg of 3% sodium iodate via an ear vein; 4 months after the injection of sodium iodate, chorioretinal atrophy was recognized by ophthalmoscopy and fluorescein angiography.

### *Fluorescein Angiography*

A 1.0-mL portion of 5% sodium fluorescein solution was injected into an ear vein for angiography using a TRC-50 IA fundus camera (Topcon, Tokyo).




**Figure 1.** Injection methods. Top: Ordinary injection method. Bottom: Rapid injection method.

### *ICG Angiography*

Normal eyes (the remaining 10 pigmented rabbits), eyes with occlusion of vortex veins (5 albino rabbits), and eyes with chorioretinal atrophy (the previous 5 pigmented rabbits) were examined. The rapid injection method was performed first, and the ordinary injection method was done thereafter in the same eye at least 5 minutes after the initial experiment using the rapid injection method. By 5 minutes, fluorescence due to the initial dye injection was no longer visible in the fundus. A Topcon TRC-50 IA fundus camera was used for ICG angiography, which was recorded on video (SVO-260®; Sony, Tokyo). The first 20 seconds of images were fed to a personal computer (Power Macintosh 8100/100 AV®, Apple) at a rate of five frames per second by a video framegrabber, and the images obtained by the rapid injection method were compared with those obtained by the ordinary injection method.

**Ordinary injection method.** One milliliter of ICG (Diagnogreen; Daiichi Pharmaceutical, Tokyo) solution (25 mg dissolved in 10 mL of manufacturer-supplied distilled water) was injected into an ear vein via a 23-gauge intracatheter.

**Rapid injection method.** Indocyanine green solution (0.02 mL; 25 mg dissolved in 2 mL of manufacturer-supplied distilled water) was injected into an



**Figure 2.** The field of measurement for mean gray value. Square measuring field with area of  $5 \times 5$  pixels within region of choroidal veins (square) was selected.

ear vein via a 23-gauge intracatheter, immediately followed by a 20-mL saline flush (Figure 1).

### *Dilution Curve Analysis*

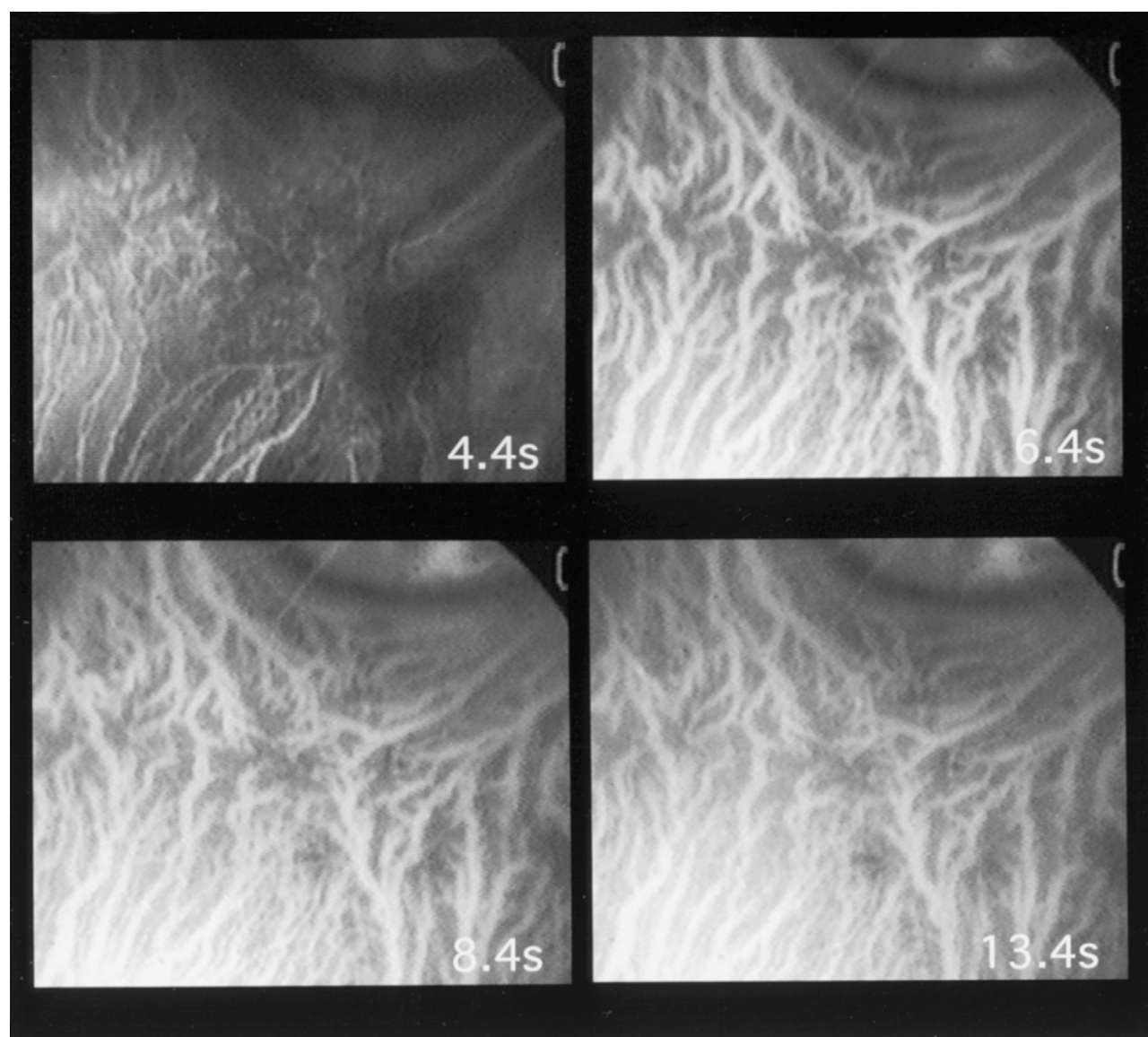
Five of the 10 normal eyes, 3 of the 5 eyes with occlusion of vortex veins, and 3 of the 5 eyes with chorioretinal atrophy were examined by dilution curve analysis. In a series of digital angiograms obtained during the first 20 seconds, a square measuring field with an area of  $5 \times 5$  pixels within the region of the

choroidal veins was selected, and the mean gray value of these points was calculated using NIH (version 1.59/1.60b7) software (Figure 2). Fluorescence intensity could range from 0 to 255 in the gray value.

## **Results**

### *Control Eyes*

**ICG angiography.** In all 10 normal eyes, the choroidal arteries were delineated 4 seconds after administration of ICG dye, and the choroidal veins began

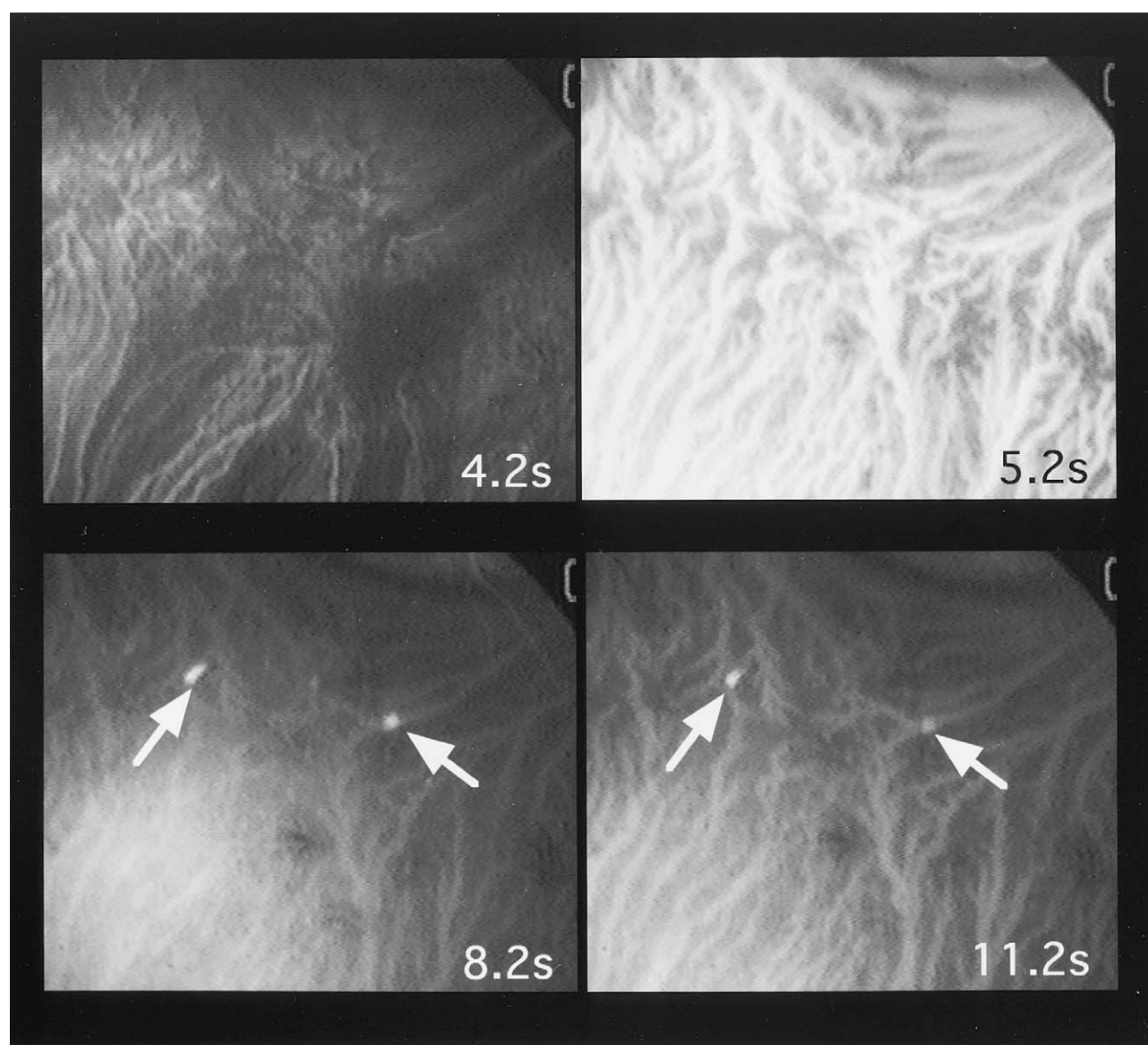


**Figure 3.** Indocyanine green angiography: Control eyes, ordinary injection method (4.4 seconds after injection). Choroidal veins began to be delineated (4.4 to 6.4 seconds after injection). Brightness of choroidal veins increased rapidly (6.4 to 13.4 seconds after injection). Brightness of choroidal veins remained constant and then decreased slowly.

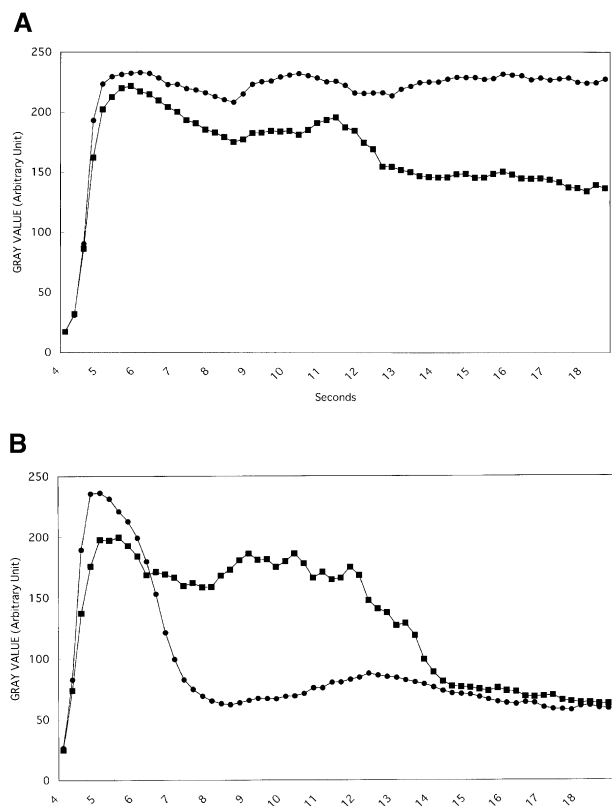
to be delineated soon afterward. With the ordinary injection method, the brightness of the choroidal veins increased rapidly within 4 to 6 seconds. Brightness remained constant for 10 seconds and then decreased slowly in all 10 eyes (Figure 3). With the rapid injection method, the choroidal veins were delineated 4 seconds after administration of ICG dye, and the brightness of the choroidal veins increased rapidly within 4 to 5 seconds. Subsequently, brightness decreased rapidly between 7 to 10 seconds after

dye administration and was constant again thereafter in 8 of the 10 eyes. In the other 2 eyes, the rapid injection method revealed the regions of delayed filling of choroidal veins as bright fluorescent boluses in the choroidal veins, which were hardly detectable with the ordinary injection method, within 6 to 14 seconds after administration of ICG dye (Figure 4).

**Dilution curves.** All eyes exhibited the following pattern. With the ordinary injection method, the mean



**Figure 4.** Indocyanine green angiography: Control eyes, rapid injection method (4.2 seconds after injection). Choroidal veins began to be delineated (4.2 to 5.2 seconds after injection). Brightness of choroidal veins increased rapidly (5.2 to 11.2 seconds after injection). Brightness of choroidal veins decreased rapidly and became constant thereafter, and bright fluorescent boluses in choroidal veins could be seen (arrows).



**Figure 5.** Dilution curves for control eyes. (A) Ordinary injection method. ●: normal filling, ■: delayed filling. Mean gray value increased rapidly from 4 to 6 seconds, and remained constant after reaching maximum value. Mean gray value for region of choroidal veins with delayed filling was always lower than that for region of choroidal veins with normal filling. (B) Rapid injection method. ●: normal filling, ■: delayed filling. Rapid descent of curve after reaching maximum gray value occurred from 5 to 7 seconds after injection. Curve for region of choroidal veins with delayed filling descended slowly after reaching maximum gray value.

gray value of the choroidal veins with normal filling increased rapidly within 4 to 6 seconds, and after reaching the maximum, the gray value remained almost constant. The mean gray value exhibited a similar pattern in the region of choroidal veins with delayed filling (Figure 5A). With the rapid injection method, as with the ordinary injection method, the mean gray value of the choroidal veins with normal filling increased rapidly within 4 to 6 seconds. However, after reaching the maximum gray value, the curve descended rapidly. In contrast, the curve for the region of the choroidal veins with delayed filling descended slowly after reaching the maximum gray value, and the mean gray value was much higher from 7 to 14 sec-

onds than in the choroidal veins with normal filling (Figure 5B).

### *Eyes with Occlusion of Vortex Veins*

**ICG angiography.** The choroidal arteries were delineated 4 seconds after administration of ICG dye, and the choroidal veins began to be delineated soon afterward. With the ordinary injection method, the choroidal veins with delayed filling were delineated as hypofluorescence from 4 to 7 seconds after administration of ICG dye in all 5 eyes, and the dye flowed in slowly 7 seconds after dye administration. With the rapid injection method, only the choroidal veins with delayed filling were delineated as positive images later than 7 seconds after administration of ICG dye, in all the 5 eyes (Figure 6).

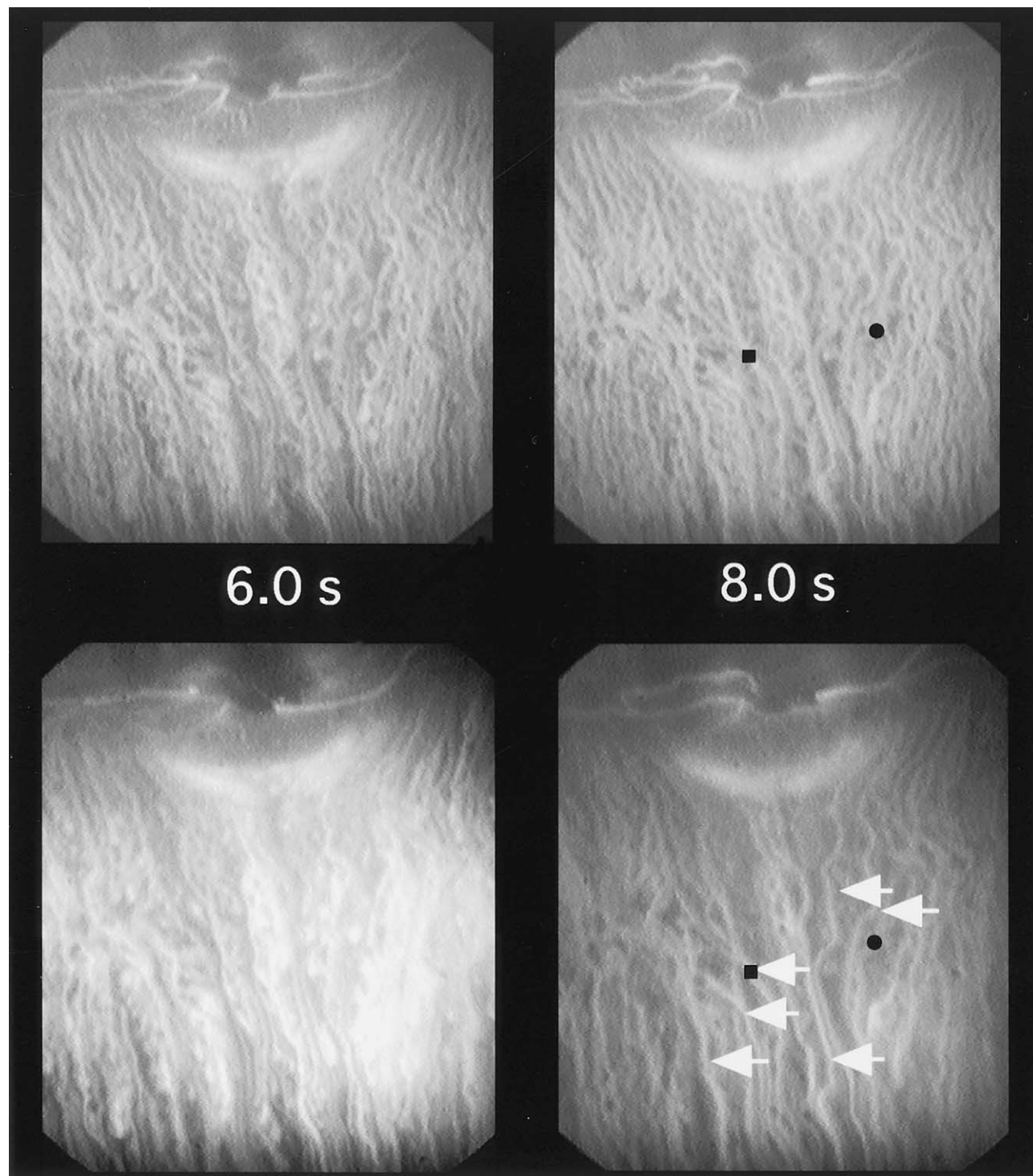
**Dilution curves.** All eyes exhibited the following pattern. With the ordinary injection method, the mean gray value of the choroidal veins with normal filling gradually increased up to 11 seconds. The mean gray value of the regions of choroidal veins with delayed filling was always lower than that of the choroidal veins with normal filling (Figure 7A). With the rapid injection method, after reaching the maximum gray value, the curve for the choroidal veins with normal filling descended rapidly, and the gray value for the choroidal veins with delayed filling became higher than that for the choroidal veins with normal filling (Figure 7B).

### *Eyes with Chorioretinal Atrophy*

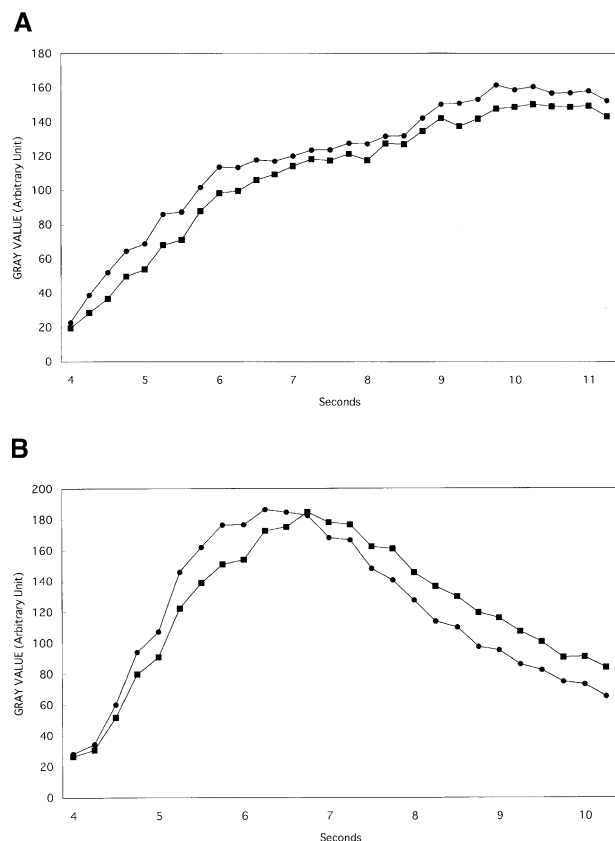
Ophthalmoscopy revealed spots around the optic disc in all 5 eyes as well as extensive chorioretinal atrophy in the vicinity of the disc. Fluorescein angiography revealed a pepper-and-salt pattern of hyperfluorescence coinciding with the regions of chorioretinal atrophy and normal fluorescence around the optic disc.

**ICG angiography.** The choroidal arteries were delineated 4 seconds after administration of ICG dye, and the choroidal veins began to be delineated soon afterward. Choroidal arteries with delayed filling were not detected in any of the 5 eyes. With the ordinary injection method, the regions of the choroidal veins with delayed filling were not clear in 4 of the 5 eyes. The rapid injection method delineated only the regions of the choroidal veins with delayed filling as brighter than the surrounding area in all the 5 eyes from 4 to 7 seconds after injection (Figure 8).

**Dilution curves.** All eyes exhibited the following pattern. With the ordinary injection method, the dilution curves were similar in pattern in the regions of



**Figure 6.** Indocyanine green angiography: Eyes with occlusion of vortex veins. Top: Ordinary injection method (6.0 seconds after injection). Choroidal veins with delayed filling, imaged as hypofluorescence, were delineated (8.0 seconds after injection). Brightness of choroidal veins with delayed filling was almost same as that of surrounding area. Bottom: Rapid injection method (6.0 seconds after injection). Choroidal veins with delayed filling were delineated as hypofluorescence (8.0 seconds after injection). Only choroidal veins with delayed filling were noted as positive finding (arrows). ●, ■: field of measurement for dilution curve.



**Figure 7.** Dilution curves for eyes with vortex vein occlusion. (A) Ordinary injection method. ●: normal filling, ■: delayed filling. Mean gray value of choroidal veins with normal filling is always higher than that of choroidal veins with delayed filling. (B) Rapid injection method. ●: normal filling, ■: delayed filling. After reaching maximum gray value, curve for choroidal veins with normal filling descended rapidly, and gray value of choroidal veins with delayed filling became higher than that of veins with normal filling.

the choroidal veins with delayed filling and in the surrounding choroidal veins (Figure 9A). With the rapid injection method, as for the ordinary injection method, the curve for the choroidal veins with delayed filling was less steep than that in the surrounding choroidal veins for the first 3 to 4 seconds after administration of ICG dye. However, after reaching the maximum gray value at about 4 seconds, the curve for the surrounding choroidal veins descended rapidly compared with that for the choroidal veins with delayed filling (Figure 9B).

## Discussion

The rapid injection method yielded ICG angiographic images of better quality than those yielded by the ordinary injection method. In 2 of the 10 con-

trol eyes, the rapid injection method clearly showed the choroidal veins with delayed filling, while it was necessary to examine the original images repeatedly with the ordinary injection method. The regions of the choroidal veins with delayed filling corresponded to the sites of choroidal venous-venous anastomoses and branching of choroidal veins. The presence of irregular filling in the choroidal veins was detectable with the rapid injection method even in control eyes.

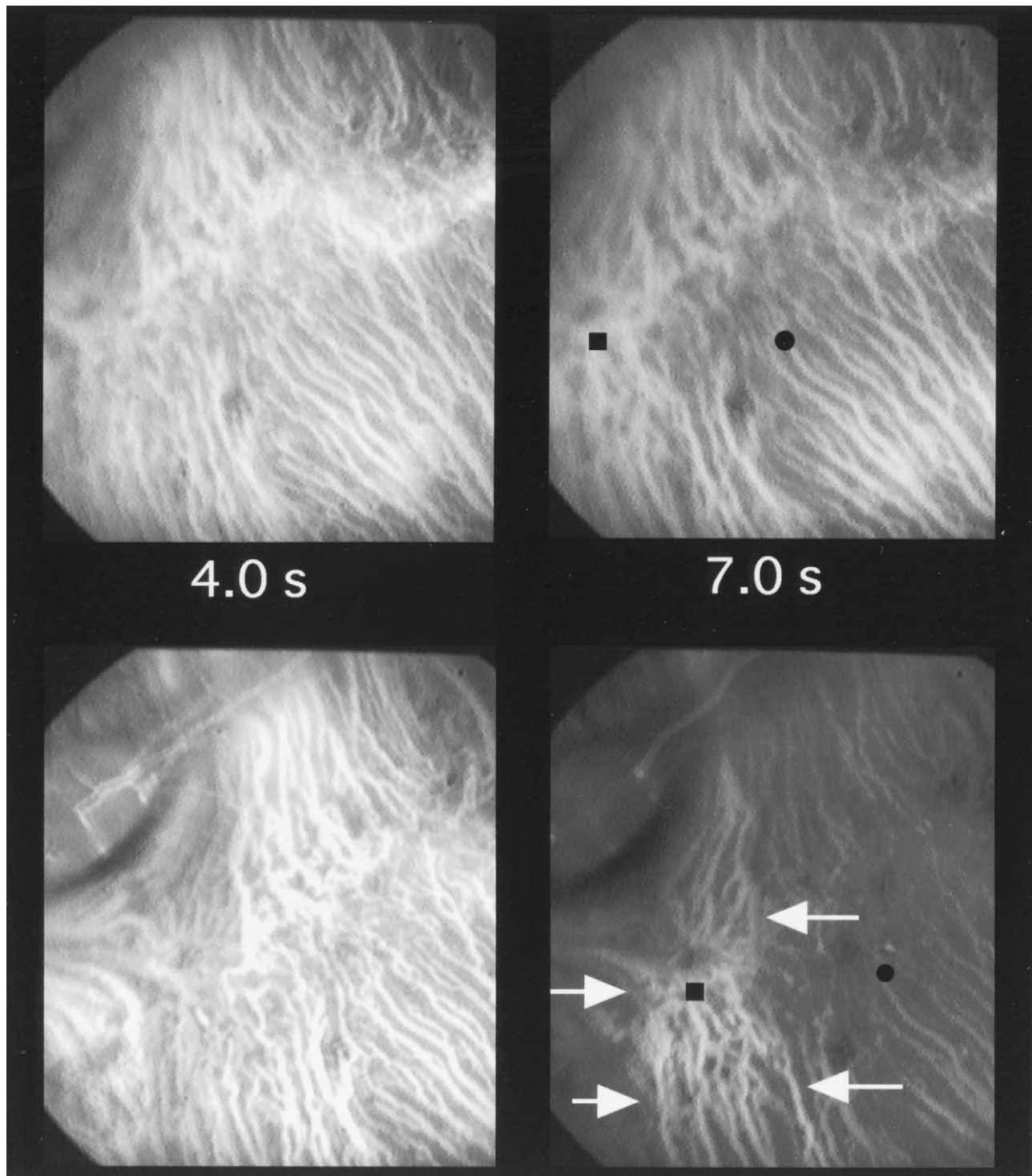
In the eyes with occlusion of vortex veins, the choroidal veins with delayed filling were detectable with the ordinary injection method, indicating irregular filling of dye. However, it was necessary to examine the original images repeatedly to determine the choroidal veins with delayed filling, making objective evaluation very difficult. In contrast, with the rapid injection method, only the choroidal veins with delayed filling were delineated selectively as positive findings.

In the eyes with chorioretinal atrophy, with the rapid injection method the choroidal veins with delayed filling were observed in the boundary between atrophic lesions and normal tissue in 4 of the 5 eyes, while it was necessary to examine the original images repeatedly with the ordinary injection method. This choroidal venous abnormality was difficult to detect using the ordinary method of ICG angiography, even with the use of a recently developed ICG angiography device which can obtain 32 frames/second continuously in the early phase of angiography.<sup>14</sup>

The dilution curve for the choroidal veins with normal filling exhibited rapid descent after reaching maximum brightness with the rapid injection method (Figures 5B, 7B, 9B), whereas constant brightness was obtained with the ordinary injection method (Figures 5A, 7A, 9A). On the other hand, with the rapid injection method, for the regions with delayed filling of choroidal veins, dilution curves showed that the brightness of the dye decreased gradually after reaching maximum gray value. As a result, dilution curves for the regions with the choroidal veins with delayed filling were higher than those for sites with normal filling after reaching maximum gray value (Figures 5B, 7B, 9B).

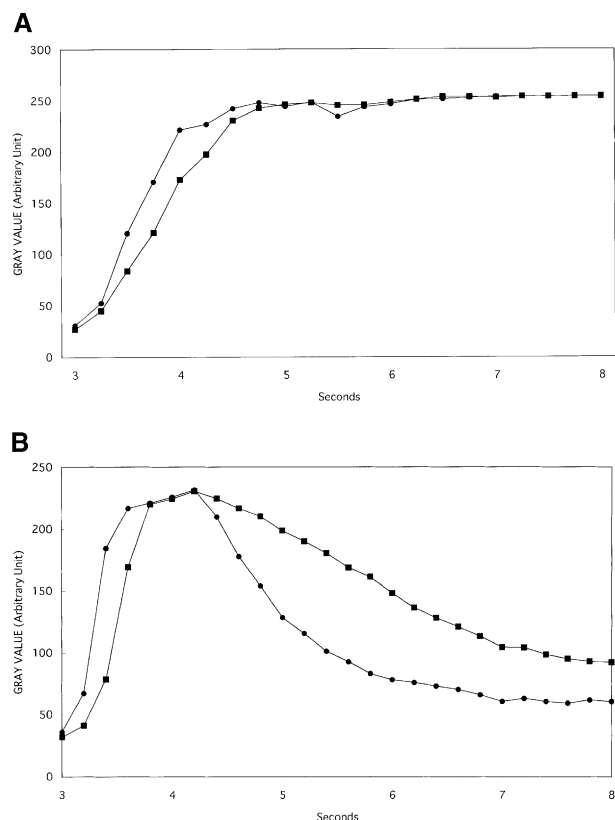
Riva and Ben-Sira<sup>15</sup> examined dilution curves for the human retinal artery under different conditions using a fluorophotometer, and found that the total amount of dye and volume of solution influenced maximum brightness, while injection time flattened the curves. In the present study, ICG solution (12.5 mg/mL, 0.02 mL) was injected in 0.02 seconds with the rapid injection method, while with the ordinary injection method 1.0 mL of a 2.5 mg/mL solution was





**Figure 8.** Indocyanine green angiography: Eyes with chorioretinal atrophy. Top: Ordinary injection method (4.0 to 7.0 seconds after injection). Region of choroidal veins with delayed filling was not clearly visible. Bottom: Rapid injection method (4.0 to 7.0 seconds after injection). Only region of choroidal veins with delayed filling was brighter than surrounding area (arrows). ●, ■: field of measurement for the dilution curve.





**Figure 9.** Dilution curves for eyes with chorioretinal atrophy. (A) Ordinary injection method. ●: normal filling, ■: delayed filling. After reaching maximum, gray value of choroidal veins with delayed filling was almost same as that of the choroidal veins with normal filling. (B) Rapid injection method. ●: normal filling, ■: delayed filling. After reaching maximum gray value, curve for choroidal veins with normal filling descended rapidly, and gray value of choroidal veins with delayed filling became higher than that of veins with normal filling.

injected in 1 second; the injection time in the rapid injection method was thus 1/50 of that in the ordinary injection method. The shorter injection time in the rapid injection method caused a rapid drop in brightness in the choroidal veins after maximum value had been reached, enabling us to detect the choroidal veins with delayed filling.

Prunte and Flammer<sup>9</sup> reported that delayed filling of the choroidal artery and choriocapillaris and congestion of the choroidal vein were clearly delineated using a scanning laser ophthalmoscopy system for ICG angiography in patients with central serous chorioretinopathy by injecting 8 mg/0.3 mL ICG solution followed by rapid injection of 5 mL of sterile water. The use of a small amount of ICG dye with a short injection time in our method probably facili-

tates analysis of choroidal venous filling. However, no distinct difference in the delineation of delayed filling of the choroidal artery or congestion of the choriocapillaris was observed between the rapid injection method and the ordinary injection method. The differing results appear to be due to the difference in choroidal vascular structure between rabbit and human eyes. They may also be due to the difference in pathology between the animal model we used and patients with central serous chorioretinopathy. Another possibility is that the scanning laser ophthalmoscope delineates the choriocapillaris more clearly than the conventional fundus camera.

In conclusion, use of a recently developed ICG angiographic apparatus has made it possible to examine choroidal lesions in greater detail, and has revealed that choroidal venous abnormalities are present in various choroidal diseases such as central serous chorioretinopathy,<sup>9</sup> age-related macular degeneration,<sup>2-5,16,17</sup> Harada's disease,<sup>7</sup> and concussion necrosis.<sup>8</sup> The present study demonstrated that the rapid injection method enables us to make an objective evaluation of chorioretinal disorders in rabbit eyes. Thus, although there are problems associated with clinical application of this method, such as in the conditions of administration and the imaging device to be used, we conclude that the rapid injection method may be useful for examination of choroidal circulation in chorioretinal diseases.

This study was supported by Grant-in-Aid for Scientific Research C2 No. 09671812 of the Ministry of Education, Science, Sports and Culture, Japan.

## References

1. Bischoff PM, Flower RW. Ten years experience with choroidal angiography using indocyanine green dye: a new routine examination or an epilogue? *Doc Ophthalmol* 1985;60:235-91.
2. Hayashi K, Hasegawa Y, Tazawa Y, de Laey JJ. Clinical application of indocyanine green angiography to choroidal neovascularization. *Jpn J Ophthalmol* 1989;33:57-65.
3. Destro M, Puliafito CA. Indocyanine green videoangiography of choroidal neovascularization. *Ophthalmology* 1989;96:846-53.
4. Yannuzzi LA, Slakter JS, Sorenson JA, Guyer DR, Orlock DA. Digital indocyanine green angiography and choroidal neovascularization. *Retina* 1992;12:191-223.
5. Kohno T, De Laey JJ, Miki T. Detection of choroidal neovascularization in age-related macular degeneration using subtraction methods in indocyanine green angiography. *Bull Soc Belge Ophthalmol* 1995;259:81-8.
6. Miki T, Shiraki K, Kohno T, Moriwaki M, Obana A. Computer assisted image analysis using the subtraction method in indocyanine green angiography. *Eur J Ophthalmol* 1996;16:30-8.
7. Kohno T, Miki T, Shiraki K, et al. Subtraction ICG angiography in Harada's disease. *Br J Ophthalmol* 1999;83:822-33.
8. Kohno T, Miki T, Hayashi K. Choroidopathy after blunt

- trauma to the eye: a fluorescein and indocyanine green angiographic study. *Am J Ophthalmol* 1998;126:248–60.
9. Prunte C, Flammer J. Choroidal capillary and venous congestion in central serous chorioretinopathy. *Am J Ophthalmol* 1996;121:26–34.
  10. Hayreh SS, Baines JA. Occlusion of the vortex veins. An experimental study. *Br J Ophthalmol* 1973;57:217–38.
  11. Noell WK. Experimentally induced toxic effects on structure and function of visual cells and pigment epithelium. *Am J Ophthalmol* 1953;36:103–16.
  12. Korte GE, Reppucci V, Henkind P. RPE destruction causes choriocapillary atrophy. *Invest Ophthalmol Vis Sci* 1984;25:1135–45.
  13. Kohno T, Miki T, Shiraki K, Moriwaki M. Indocyanine green angiography in choriocapillary atrophy induced by sodium iodate. *Graefes Arch Clin Exp Ophthalmol* 1995;233:642–8.
  14. Kano K. Analysis of early phase indocyanine green angiography by subtraction method using confocal scanning laser ophthalmoscopy. *Atarashii Ganka (J Eye)* 1997;14:1853–8.
  15. Riva CE, Ben-Sira I. Injection method for ocular hemodynamic studies in man. *Invest Ophthalmol Vis Sci* 1974;13:77–9.
  16. Shiraga F. Identification of feeder vessels in subfoveal choroidal neovascularization. *Rinsho Ganka (Jpn J Clin Ophthalmol)* 1995;49:63–71.
  17. Iida T, Hagimura N, Kishi S, Shimizu K. Indocyanine green angiographic features of idiopathic submacular choroidal neovascularization. *Am J Ophthalmol* 1998;126:70–6.