

Evaluation of Extraocular Muscle Enlargement in Dysthyroid Ophthalmopathy

Yoko Murakami^{*,†}, Takashi Kanamoto^{*,†},
Toshikazu Tuboi^{*,‡}, Toshine Maeda^{*} and Yoichi Inoue^{*}

**Olympia Eye Hospital, Tokyo, Japan; †Department of Ophthalmology, Hiroshima University School of Medicine, Hiroshima, Japan; ‡Department of Ophthalmology, Tokyo Medical and Dental University School of Medicine, Tokyo, Japan*

Purpose: To evaluate extraocular muscle enlargement (EME) in dysthyroid ophthalmopathy.

Methods: EME was assessed by orbital computed tomography (CT) in 573 patients with dysthyroid ophthalmopathy in order to investigate the frequency and exact location of EME and the clinical features of related ocular symptoms in patients with dysthyroid ophthalmopathy.

Results: Of the 573 patients examined, 187 patients (38%) showed evidence of EME on CT images. This disorder was more frequent in male patients than in female patients. EME was also more frequently seen in older patients than in younger patients. Enlargement of a single muscle was found in 55% of the 187 patients, with the most frequently affected muscle being the inferior rectus muscle. When multiple muscles were enlarged, the inferior rectus muscle was the most frequently affected, followed by the medial rectus muscle.

Conclusions: Of the clinical findings specific to dysthyroid ophthalmopathy examined in the present study, the incidence of exophthalmos, upper lid swelling, superior limbic keratoconjunctivitis, keratitis, diplopia, and dysthyroid optic neuropathy was significantly increased in patients with dysthyroid ophthalmopathy, indicating a close relationship between these findings and the underlying disease, but the incidence of upper lid retraction was not significantly increased. **Jpn J Ophthalmol 2001;45:622–627** © 2001 Japanese Ophthalmological Society

Key Words: Computed tomography, dysthyroid ophthalmopathy, extraocular muscle enlargement.

Introduction

Dysthyroid ophthalmopathy presents with different signs and symptoms of varying severity in different individuals, thus suggesting the complex involvement of multiple pathogenic factors in its clinical manifestations.¹ The disorder generally affects the eyelids, with the smooth muscle and the upper lids involved, and the orbits, with the extraocular muscles and orbital adipose tissues involved. Pathology related to the orbits, so-called orbitopathy, is caused by inflammation, fibrosis, or adhesion of soft tissues such as adipose tissues, the extraocular muscles, and

connective tissues. Among the clinically important symptoms of orbitopathy, extraocular muscle enlargement (EME) is often associated with relatively severe ocular complications, and the degree of enlargement needs to be determined by a reliable diagnostic procedure in order to determine the appropriate therapeutic approach in the treatment of dysthyroid ophthalmopathy. In 1972, Coleman et al succeeded in depicting inflammatory changes in the extraocular muscles and orbital adipose tissues by ultrasonography.² In 1976, Enzmann et al evaluated intraorbital changes, including EME, by computed tomography (CT) scanning.³ These advanced imaging technologies have also been applied to the diagnosis of dysthyroid ophthalmopathy^{4–7} and, in addition, magnetic resonance imaging has been employed to evaluate changes in the orbital soft tissues.⁸ However, the relation between EME and the mechanism of dysthyroid oph-

Received: July 24, 2000

Correspondence and reprint requests to: Yoichi INOUE, MD, Olympia Eye Hospital, 2-18-12 Jingumae, Shibuya-ku, Tokyo 150-0001, Japan

thalmopathy remains unclear, probably because of a bias due to the limited number of subjects analyzed in previous studies. Because dysthyroid ophthalmopathy has become better recognized among physicians and surgeons, we ophthalmologists have a chance to see a greater range of patients, and the male-female ratio of the dysthyroid ophthalmopathy group has proved to be similar to the ratio of the thyroid dysfunction group, which is 1:4. So, we consider that the group that we studied this time was more precisely analyzed than in previous reports. In the present study, orbital CT was used to identify the presence or absence of EME in patients with dysthyroid ophthalmopathy, and the clinical profile of dysthyroid ophthalmopathy was characterized in terms of the frequency and localization of EME and associated ocular symptoms.

Materials and Methods

The study group comprised 573 patients with hyperthyroidism who visited our hospital during the period from September 1996 to March 1997. The average age of the patients was 41 years (range, 9 to 80 years), and the group included 118 male and 455 female patients. A CT scanner (GE model 8600) was used to perform orbital and axial scans with a minimal slice thickness of 2.0 mm, a window width of approximately 300 Housefield units, and at a CT number of approximately +30 Housefield units. First of all, a single radiologist with extensive experience in CT scanning determined the EME by comparing the medial rectus muscle or lateral rectus muscle to the optic nerve. Any muscles that were clearly thicker than the optic nerve were determined to be enlarged by CT. The same radiologist also determined whether the apex was compressed by the enlargement of the extraocular muscles. The following seven clinical symptoms, which are commonly seen in dysthyroid ophthalmopathy, were graded according to the Inoue classification system⁹: eyelid symptom such as upper lid swelling or upper lid retraction, conjunctival change such as superior limbic keratoconjunctivitis (KC), corneal damage, exophthalmos, disturbance of ocular movement, and optic neuropathy. Proptosis was defined as the distance between the apex of the cornea and the line between the orbital rims depicted on the mid-orbital scans, which can be determined in the lens, optic nerve, and lateral and medial rectus muscles most clearly compared with other planes. Both eyes were used to assess the disturbance of ocular movement in each patient, and the right eye was examined to evaluate the other clinical symptoms. Sta-

tistical evaluation was performed using the chi-square test and the Mann-Whitney *U*-test.

Results

In this study, EME on CT is judged only in rectus muscles, not in oblique muscles.

CT imaging revealed EME in 219 (38%) of the 573 patients; 142 (25%) in both eyes and 77 (13%) in either the right or left eye (Figure 1A). EME was found in 65 of the 118 male patients and in 122 of the

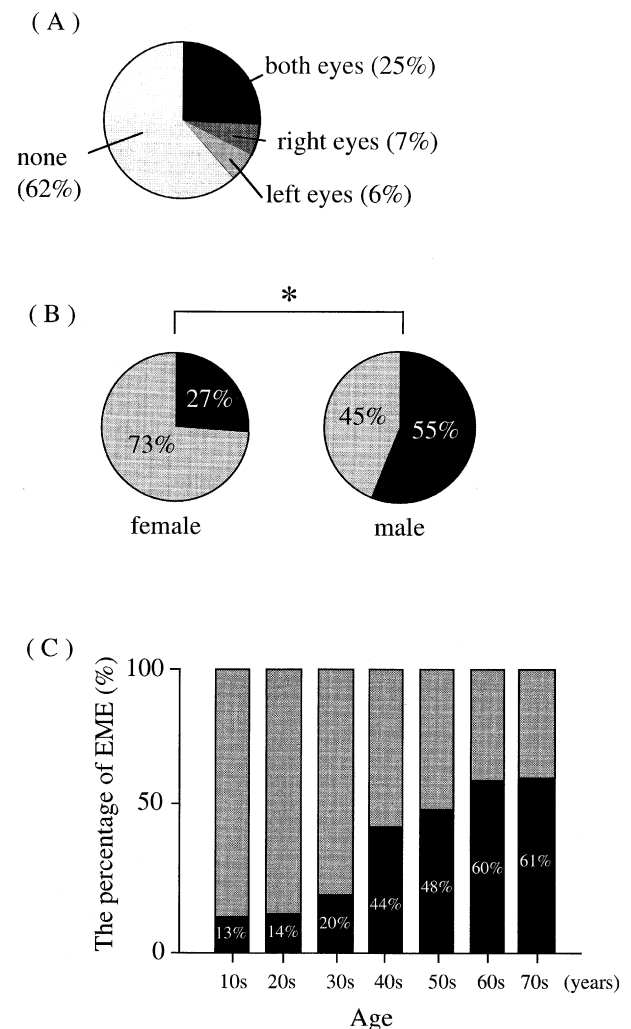


Figure 1. Summary of CT findings (1): Frequency and severity of extraocular muscle enlargement (EME) in 573 patients with dysthyroid ophthalmopathy. (A) Distribution of patients with unilateral and bilateral EME. (B) Sex ratios of patients with or without EME (black: patients with enlargement, shaded: patients without enlargement, **P* < .01, chi-square analysis). (C) Age distribution of patients with or without EME (black: patients with enlargement, shaded: patients without enlargement).

455 female patients, indicating a significant sex difference (55% vs 27%) ($P < .01$) (Figure 1B). The average age of patients with EME was 46 ± 13 years, and that of patients without EME was 36 ± 13 years, indicating, as anticipated, that older patients had more severe manifestations of the disorder than younger patients ($P < .01$). The frequency of EME was directly correlated with age in patients 40 years of age or older (Figure 1C).

When the four rectus muscles were examined in the 184 patients with EME, a single muscle was found to be enlarged in 102 (54%), two muscles were

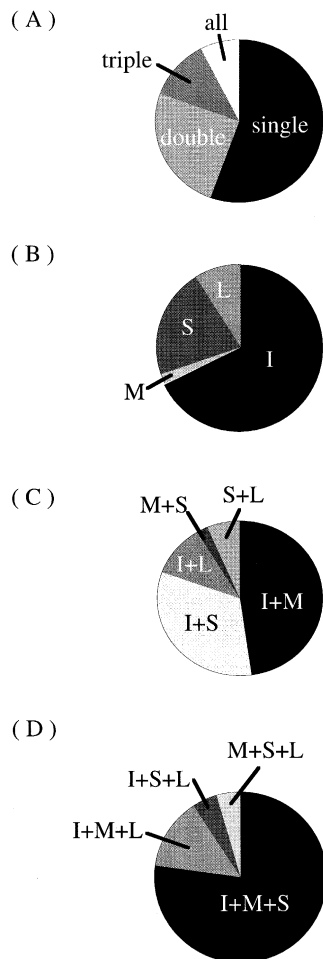


Figure 2. Summary of CT findings (2): Involvement of rectus muscles in extraocular muscle enlargement (EME). (A) Proportion of single and multiple rectus muscle involvement in 184 patients with EME. (B) Site of EME in 102 patients with involvement of a single rectus muscle. (C) Site of EME in 46 patients with involvement of two rectus muscles. (D) Site of EME in 22 patients with involvement of three rectus muscles. I: Inferior rectus muscle, M: medial rectus muscle, S: superior rectus muscle, L: lateral rectus muscle.

enlarged in 46 (25%), three muscles were enlarged in 22 (12%), and all four muscles were enlarged in the remaining 14 (9%). The most common finding was enlargement of a single muscle, and the frequency was inversely proportional to the number of muscles affected (Figure 2A). Single-muscle enlargement involved the inferior rectus muscle in 69 of the 102 patients (68%), the medial rectus muscle in 2 (2%), the superior rectus muscle in 22 (20%), and the lateral rectus muscle in 9 (9%). Thus, the inferior rectus muscle was the most frequently affected muscle in patients with single-muscle enlargement (Figure 2B). The medial rectus muscle was not so frequently enlarged in the group with single-muscle enlargement, but surprisingly, was affected mainly in patients with multiple-muscle enlargement (Figures 2C and D).

The grade of exophthalmos was found to be 19 ± 2.7 mm in patients with EME and 17 ± 2.4 mm in patients without EME, which was a statistically significant difference ($P < .01$) (Figure 3). Among the clinical symptoms associated with the underlying disease, disturbance of ocular movement, upper lid swelling, superior limbic KC, keratitis, and optic neuropathy were seen significantly more frequently with EME than in patients without EME (Table 1A). However, the frequency of upper lid retraction was comparable between the two patient groups, and the frequency of upper lid retraction was not positively correlated with the presence of EME (Table 1B). In

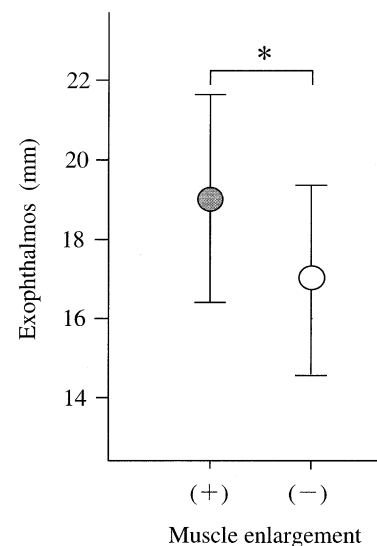


Figure 3. Correlation of grade of exophthalmos (mean \pm SD) and extraocular muscle involvement in 184 patients with extraocular muscle enlargement (EME) and 389 without EME. ($*P < .01$, Mann-Whitney *U*-test).

Table 1. Correlation Between Extraocular Muscle Enlargement (EME) and Ocular Symptoms in 573 Patients with Dysthyroid Ophthalmopathy*

A	EME		χ^2
	(+)	(-)	
Upper lid swelling	106/184 (58)	99/389 (18)	†
Upper lid retraction	122/184 (66)	237/389 (61)	NS‡
Superior limbic keratoconjunctivitis	18/184 (10)	14/389 (4)	†
Keratitis	82/184 (46)	89/389 (23)	†
Disturbance of ocular movement	124/219 (57)	19/354 (5)	†
Optic neuropathy	29/184 (16)	1/389 (<1)	†
	Superior rectus muscle enlargement		χ^2
B	(+)	(-)	
Upper lid retraction	53/74 (66)	306/499 (61)	NS‡

* Values in parentheses are percentages.

† $P < .01$.

‡ NS: not significant.

addition, upper lid swelling and keratitis were seen more frequently in patients with lacrimal gland enlargement ($P < .01$) (Table 2), and optic neuropathy was frequently seen in patients with compression of the apex ($P < .01$) (Table 3).

Discussion

The results of the present study, in which orbital CT scanning was performed to evaluate dysthyroid ophthalmopathy in 573 patients, showed that the frequency of EME was related to age, as has been reported in previous studies,¹⁰ and also that EME was more frequent in male patients than in female patients and in older patients than in younger patients. This suggests that the older male population is at

Table 2. Correlation Between Lacrimal Gland Enlargement and Ocular Symptoms in 573 Patients with Dysthyroid Ophthalmopathy*

	Lacrimal Gland Enlargement		$\chi^{2†}$
	(+)	(-)	
Upper lid swelling	38/48 (79)	167/525 (32)	‡
Upper lid retraction	31/48 (65)	328/525 (63)	NS
Superior limbic keratoconjunctivitis	1/48 (6)	29/525 (6)	NS
Keratitis	21/48 (44)	150/525 (29)	‡

* Values in parentheses are percentages.

† NS: not significant.

‡ $P < .01$.

Table 3. Correlation Between Comparison of Apex and Optic Neuropathy in 573 Patients with Dysthyroid Ophthalmopathy*

	Compression of Apex		χ^2
	(+)	(-)	
Optic neuropathy	16/34 (47)	14/539 (3)	†

* Values in parentheses are percentages.

† $P < .01$.

high risk of EME in dysthyroid ophthalmopathy. The frequency of EME among dysthyroid ophthalmopathy patients determined in the present study was essentially the same (38%) as reported by Baba et al,¹¹ but was not as high as that (54%) reported by Yoshikawa et al.¹² This difference is probably related to demographic variations in the sex ratio and age distribution of the patients studied, because the latter study included male and female patients with a sex ratio of 2 to 3 (vs 1 to 4 in this study) and with an average age of 48 years (vs 41 in this study).

The most frequent EME site was found to be the inferior rectus muscle in cases of both single- and multiple-muscle involvement. This result agrees with the findings in the literature¹²; however, it has not yet been determined why the inferior rectus muscle is preferentially involved. It may be postulated that the inferior rectus muscle, which is anatomically located adjacent to Lockwood's ligament and the inferior oblique muscle, unlike other rectus muscles, and is therefore surrounded by connective tissues, may be more readily affected by the fibrosis, which is induced by fibroblasts activated by abnormal lymphocytes.^{13,14} To our surprise, medial muscle enlargement, which was rarely observed in patients with single-muscle enlargement, was encountered with greater frequency in patients with enlargement of two muscles in this study. Further studies involving larger numbers of patients are necessary to clarify the reason for this phenomenon.

Exophthalmos is generally known to be closely related to EME. EME might contribute to the elevation of intraorbital pressure, which leads to the development of exophthalmos. However, there were also cases of exophthalmos without CT evidence of EME. In these cases, the increase in intraorbital pressure may have been due to factors other than EME, with an increase in orbital fat the most probable contributory factor.^{15,16}

It has been hypothesized that overaction of Müller's muscle is due to increased sympathetic activity or inflammation, fibrosis, or adhesion of the superior levator palpebral muscle and that Müller's

muscle induces upper lid retraction.¹⁷ In support of this hypothesis, the present study did not demonstrate a positive correlation between the frequency of upper lid retraction and that of EME, which is an orbitopathic change. In view of a report that the pathogenesis of upper lid retraction may involve enlargement of the levator palpebral and the superior rectus muscles,¹⁸ the frequency of upper lid retraction was compared with that of superior rectus muscle enlargement, but a negative correlation was seen. CT images did not clearly discriminate between the levator palpebral muscle and other superior rectus muscles in this study. Therefore, the authors are currently developing a clinical protocol to study extraocular muscles using magnetic resonance or other imaging techniques.

Disturbance of ocular movement also showed a positive correlation with EME in the following paired comparisons (data not shown): inferior rectus muscle enlargement and limitation of upward gaze, medial rectus muscle enlargement and limitation of lateral gaze, superior rectus muscle enlargement and limitation of downward gaze. These findings suggest that disturbance of ocular movement occurs as a consequence of ocular functional disturbance due to inflammatory and fibrotic lesion of extraocular muscles and limitation of ocular movement due to adhesion to surrounding connective tissue involving the muscles.¹⁹

Optic neuropathy is generally known to be related to EME. This was also demonstrated in the present CT scan study: the frequency of compression at the apex was closely correlated with that of EME, supporting several hypotheses: that direct compression of the optic nerve by thickened rectus muscles can lead to optic neuropathy or that indirect disturbance of the optic nerve is induced by circulatory disturbance.²⁰ However, this ocular condition is also found in eyes without compression of the apex or muscle enlargement. It is very likely that other etiologic factors are involved in the development of optic neuropathy.^{21,22} The authors therefore plan to analyze additional CT data.

We also tried to analyze the relationship of the thyroid hormone and EME, but we considered that CT data in this study might not reflect the hormonal state. The period varied between when the patients first realized their thyroid dysfunction to when they consulted an ophthalmologist.

Conclusions

Finally, we could not reach a significant conclusion this time, and so we need to use CT to observe

the movement of the thyroid hormonal level in our next study.

The results of the present study indicate that orbital CT is a useful diagnostic tool for evaluating patients with dysthyroid ophthalmopathy, and in particular, the associated EME. It is hoped that this diagnostic modality will contribute to the treatment of patients with this progressive condition.

The authors wish to thank Dr. Hayao Shiga, Department of Radiology, Keio-gijuku University, who helped in the determination of EME by CT.

This paper was published in part in Japanese in the *Nippon Ganka Gakkai Zasshi (Jpn J Ophthalmol Soc)* 2000;104:34-38. It appears here in a modified form after peer review and editing for the *Japanese Journal of Ophthalmology*.

References

1. Feldon SE, Weiner JM. Clinical significance of extraocular muscle volumes in Graves' ophthalmopathy: a quantitative computed tomography study. *Arch Ophthalmol* 1982;100:1266-9.
2. Coleman DJ, Jack RL, Franzen LA, Werner SC. High resolution B-scan ultrasonography of the orbit. *Arch Ophthalmol* 1972;88:465-71.
3. Enzmann D, Marshall WH, Rosenthal AR, Kriss JP. Computed tomography in Graves' ophthalmopathy. *Radiology* 1976;118:615-20.
4. Trokel SL, Jackobiec FA. Correlation of CT scanning and pathologic features of ophthalmic Graves' disease. *Ophthalmology* 1981;88:553-64.
5. Hallin ES, Feldon SE. Graves' ophthalmopathy: I. Simple CT estimates of extraocular muscle volume. *Br J Ophthalmol* 1988;72:674-7.
6. Hallin ES, Feldon SE. Graves' ophthalmopathy; II. Correlation of clinical signs with measures derived from computed tomography. *Br J Ophthalmol* 1988;72:678-82.
7. Inoue Y, Inoue T. Study on dysthyroid ophthalmopathy. Third International Symposium on Orbit Disorders, Amsterdam. *Proceedings* 1977;349-55.
8. Nishida Y, Aoki Y, Hayashi, Y, Murata T, Nishida E, Kani K. Volume measurement of horizontal extraocular muscles with magnetic resonance imaging. *Jpn J Ophthalmol* 1996;40:439-46.
9. Inoue Y, Inoue T. Clinical study on dysthyroid ophthalmopathy; II. Classification of dysthyroid ophthalmopathy. *Nippon Ganka Gakkai Zasshi (Acta Soc Ophthalmol Jpn)* 1971; 75:2057-62.
10. Char DH. Thyroid eye disease. *Br J Ophthalmol* 1996;80:922-6.
11. Baba Y, Yoshikawa K, Mizuno M, Inoue T, Inoue Y. Study on dysthyroid ophthalmopathy therapy; II. Diagnosis and treatment of extraocular muscle enlargement. *Nippon Ganka Gakkai Zasshi (Acta Soc Ophthalmol Jpn)* 1989;93:785-9.
12. Yoshikawa K, Higashide T, Nakase Y, Inoue T, Inoue Y, Shiga, H. Role of rectus muscle enlargement in clinical profile of dysthyroid ophthalmopathy. *Jpn J Ophthalmol* 1991;35:175-81.
13. Heufelder AE, Bahn RS. Modulation of Graves' orbital fibroblast proliferation by cytokines and glucocorticoid receptor agonists. *Invest Ophthalmol Visual Sci* 1994;35:120-7.
14. Hufnagel TJ, Hickey WF, Cobbs WH, Jakobiec FA, Iwamoto T, Eagle RC. Immunohistochemical and ultrastructural stud-

- ies on the exenterated orbital tissues of a patient with Graves' disease. *Ophthalmology* 1984;91:1411-9.
15. Trokel S, Kazim M, Moore S. Orbital fat removal: decompression for Graves orbitopathy. *Ophthalmology* 1993;100:674-82.
 16. Hudson HL, Levin L, Feldon SE. Graves exophthalmos unrelated to extraocular muscle enlargement: superior rectus muscle inflammation may induce venous obstruction. *Ophthalmology* 1991;98:1495-9.
 17. Grove AS. Upper eyelid retraction and Graves' disease. *Ophthalmology* 1981;88:499-506.
 18. Ohnishi T, Noguchi S, Murakami N, et al. Levator palpebrae superioris muscle: MR evaluation of enlargement as a cause of upper eyelid retraction in Graves disease. *Head Neck Radiol* 1993;188:115-8.
 19. Inoue Y, Inoue T, Ichikizaki K, Shiga I, Yanashita A. Role of extraocular rectus muscle enlargement in etiology of dysthyroid ophthalmopathy. *Rinsho Ganka (Jpn J Clin Ophthalmol)* 1978;32:901-5.
 20. Kennerdell JS, Rosenbaum AE, El-Hoshy MH. Apical optic nerve compression of dysthyroid optic neuropathy on computed tomography. *Arch Ophthalmol* 1981;99:807-9.
 21. Flaharty PM, Sergott RC, Lieb W, Bosley TM, Savino PJ. Optic nerve sheath decompression may improve blood flow in anterior ischemic optic neuropathy. *Ophthalmology* 1993;100:297-302.
 22. Nakase Y, Osanai T, Yoshikawa K, Inoue Y. Color Doppler imaging of orbital venous flow in dysthyroid optic neuropathy. *Jpn J Ophthalmol* 1994;38:80-6.