

Optic Nerve Involvement in Neuro-Behçet's Disease

Toru Nakamura, Kyoichi Takahashi and Shoji Kishi

Department of Ophthalmology, Gunma University School of Medicine, Maebashi, Japan

Background: To report the ocular manifestations of neuro-Behçet's disease.

Cases: A 34-year-old woman had recurrent meningitis. She developed diplopia, headache, and ataxia, and was diagnosed as having neuro-Behçet's disease.

Observations: Imaging revealed two infarct foci in the transitional midbrain and pons. After treatment with prednisolone and colchicine, the diplopia resolved. Two years later, a scotoma developed in the right eye, in which the best-corrected visual acuity was 4/200. Papillitis and a prepapillary vitreous opacity were seen in the right fundus. These findings disappeared 11 days after subconjunctival steroid injections and increased colchicine. Her vision gradually improved to 20/20 two months later.

Conclusion: Neuro-Behçet's disease may manifest with transient optic neuritis and prepapillary vitreous opacity. **Jpn J Ophthalmol 2002;46:100–102** © 2002 Japanese Ophthalmological Society

Key Words: Neuro-Behçet's disease, prepapillary vitreous opacity.

Introduction

Behçet's disease is characterized by hypopyon iritis, stomatitis, and genital ulcerations. The ocular manifestations include panuveitis and retinal and choroidal vasculitis. Neuro-Behçet's disease may cause palsy of cranial nerves VI and VII,¹ papillitis, and papilledema.^{2,3} Although the central nervous system is affected in 24% of patients, the ocular manifestations of neuro-Behçet's disease are not well known. We describe a patient with neuro-Behçet's disease whose ocular signs were diplopia and papillitis with a prepapillary vitreous opacity.

Case Report

A 34-year-old woman had recurrent aphthous stomatitis, skin pustules, cutaneous hypersensitivity, and genital ulcers beginning in October 1995. Meningitis occurred four times during a 3-year period

from September 1996. Sudden onset of uncrossed diplopia, anisocoria, nystagmus, headache, and ataxia were associated with the meningitis episode in August 1997. She showed a positive sign on the swinging flash-light test. Magnetic resonance imaging (MRI) demonstrated two high-intensity foci on T₂-weighted images (Figure 1) in the transitional midbrain and pons, consistent with cerebral infarction. Examination of cerebrospinal fluid indicated pleocytosis and increased proteins. The patient was diagnosed as having neuro-Behçet's disease and was treated with oral prednisolone, 30 mg/day, and colchicine, 1.5 mg/day. Three months later the diplopia and nystagmus resolved.

In January 1999, she complained of blurred vision and a central scotoma in her right eye. She was taking a maintenance dose of 25 mg of oral prednisolone and 1.0 mg of colchicine daily. Visual acuity was 4/200. Papillitis with a peripapillary hemorrhage was observed in the right fundus. The retina was slightly edematous in the papillomacular area (Figure 2, left). Because of the prepapillary vitreous opacity, the optic disc was obscured. Fluorescein angiography demonstrated intense hyperfluorescence of the peripapillary

Received: December 12, 2000

Correspondence and reprint requests to: Toru NAKAMURA, MD, Department of Ophthalmology, Gunma University School of Medicine, 3 Showamachi, Maebashi 371-8511, Japan

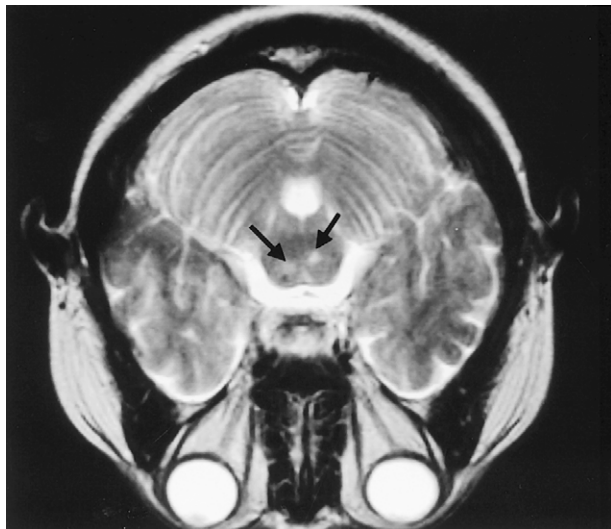


Figure 1. Magnetic resonance image from August 1997. T₂-weighted image at plane of transition between midbrain and pons in patient diagnosed as having neuro-Behçet's disease. Two high-intensity foci (arrows) are seen, indicating cerebral infarction.

lesion without vascular leakage. The fellow eye was normal (visual acuity, 20/20). MRI showed no abnormality in the right optic nerve. We injected 0.3 mL of dexamethasone into the subconjunctival space of her right eye for 2 days, and increased the dose of colchicine from 1.0 to 1.5 mg/day. Three days later, her vision improved. Eleven days later, the prepapillary vitreous opacity and the papillitis resolved (Figure 2, right). Although the optic disc became slightly pale, her vision recovered to 20/20 two months later.

Discussion

The pathologic features of neuro-Behçet's disease are not well known. An autopsy study reported many micro-spongioid necrotic foci in the gray and white matter of the cerebrum, basal ganglia, thalamus, midbrain, and pons.⁴ These necrotic brain foci also may be caused by vaso-occlusive angitis, which is frequently seen in the retina. In this case, the 3rd nerve palsy due to midbrain and pons infarctions caused diplopia and anisocoria.

Yamaguchi et al⁵ reported two cases of Behçet's disease with papilledema. These patients had no abnormality in ocular motility. Although MRI data was not presented, there was no evidence of neuro-Behçet's disease. Our case demonstrated infarction of the central nerve system by MRI and papillitis with prepapillary vitreous opacity.

In an acute attack of Behçet's disease, polymorphic leukocytes infiltrate the ocular tissue. The inflammation is usually transient and self-limited. In our case, the papillitis quickly resolved with absorption of prepapillary vitreous opacity and no significant tissue damage. The sudden decreased vision with central scotoma and the papillitis resolved. This reversibility suggests that the papillitis resulted from polymorphic leukocytic infiltration. The prepapillary vitreous opacity appeared to reflect an accumulation of polymorphic leukocytes that migrated from the optic disc. The prepapillary vitreous has a potential space, ie, the enlarged end of Cloquet's canal,⁶ in which leukocytes may settle. To treat the papillitis, we prescribed subconjunctival steroid for only 2 days and increased the colchicine dose. It was hard to de-

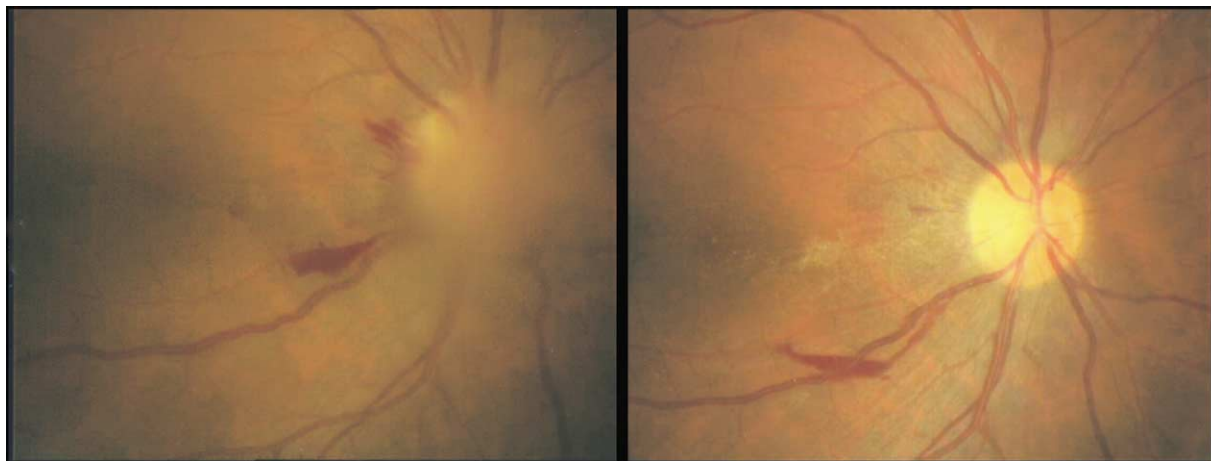

Figure 2. Left: Papillitis with peripapillary hemorrhage and prepapillary vitreous opacity are observed in right fundus. Retina is edematous in papillomacular area. Right: Right fundus 3 weeks later than shown at left. Prepapillary vitreous opacity has disappeared and papillitis has resolved.

termine whether the papillitis resolved with treatment or resolved spontaneously.

References

1. Colvard DM, Robertson DM, O'Duffy JD. The ocular manifestations of Behçet disease. *Arch Ophthalmol* 1977;95:1813–7.
2. James DG, Spiteri MA. Behcet disease. *Ophthalmology* 1982;89:1279–84.
3. Kalbian VV, Chalis MT. Behcet's disease: report of twelve cases with three manifesting as papilledema. *Am J Med* 1970;49:823–9.
4. Yamamori C. Neuro-Behçet's disease with demyelination and gliosis of the frontal white matter. *Clin Neurol* 1994;13:208–15.
5. Yamaguchi T, Miyakawa S, Morishima N. Two cases of Behcet's disease with suspected optic nerve involvement. *Nihon Ganka Kyo (Folia Ophthalmol Jpn)* 1994;45:780–6.
6. Tolentino FI, Schepens CL, Freeman HM. Normal vitreous body under biomicroscope. In: Tolentino FI, Schepens CL, Freeman HM, eds. *Vitreoretinal disorders*. Philadelphia: WB Saunders, 1976:114–5.