

Neovascular Glaucoma Associated with Cilioretinal Artery Occlusion Combined with Perfused Central Retinal Vein Occlusion

Man-Seong Seo,* Jae-Moon Woo* and Jeong-Jin Seo[†]

**Department of Ophthalmology, Chonnam*

National University Medical School and Hospital, Chonnam

National University Research Institute for Medical Sciences, Kwangju, Korea;

[†]Radiology, Chonnam National University Medical School and Hospital, Kwangju, Korea

Background: Cilioretinal artery occlusion rarely results in neovascular glaucoma, especially in cases of extensive cilioretinal infarction and combined retinal vascular occlusion.

Case: A 62-year-old man with diabetes mellitus and essential hypertension showed a visual acuity of counting fingers, retinal whitening temporal to the optic disc with mild dilation and tortuosity of the retinal veins, and retinal hemorrhages in four quadrants of his right eye. Fluorescein angiography demonstrated a delayed filling of the central retinal vein and cilioretinal artery.

Observations: Two months later, neovascular glaucoma developed and retinal ablation was performed using an argon laser. Trabeculectomy was also performed due to the intractability of the glaucoma, and central artery occlusion was found. On magnetic resonance angiography, the right distal common carotid artery was irregularly narrowed and the right ophthalmic artery was almost entirely occluded.

Conclusions: In cases of cilioretinal artery occlusion and perfused central retinal vein occlusion with multiple risk factors, close follow-up is advised. **Jpn J Ophthalmol 2002;46:198–202** © 2002 Japanese Ophthalmological Society

Key Words: Central retinal vein occlusion, cilioretinal artery occlusion, magnetic resonance angiography, neovascular glaucoma.

Introduction

Cilioretinal arteries supply the retina, but are usually derived from the short posterior ciliary arteries and, rarely, directly from the choroidal vessels.¹ Fluorescein angiography has demonstrated that cilioretinal arteries are present in about 32% of eyes.² Ophthalmoscopy alone detects cilioretinal arteries in about 20% of eyes.³ Three clinical variants of cilioretinal artery occlusions (CLAO) may occur: (1) isolated CLAOs, (2) CLAOs with central retinal

vein occlusion (CRVO), and (3) CLAOs with ischemic optic neuropathy.⁴ In the case of CLAO with CRVO, it appears that CLAO occurs subsequent to and probably secondary to the CRVO. The mechanism of its occurrence has been explained as follows: the CRVO produces an elevation of intraluminal capillary pressure, because the central retinal artery continues to pump blood into the retina. However, the perfusion pressure of the central retinal artery is usually slightly higher than the perfusion pressure of the posterior ciliary artery circulation. Therefore, the cilioretinal artery, with its lower perfusion pressure, cannot perfuse into the retinal capillary bed or does so only sluggishly or only during systole. This relative hypoperfusion is caused primarily by an increased retinal venous pressure, and occurs especially during diastole when the arterial pressure in

Received: April 28, 2000

Correspondence and reprint requests to: Man-Seong SEO, MD, PhD, Department of Ophthalmology, Chonnam National University Medical School and Hospital, Chonnam National University Research Institute for Medical Sciences, 8 Hakdong Dongku, Kwangju 501-757, Korea

the posterior ciliary circulation is lower than the retinal venous pressure. Therefore, the cilioretinal artery becomes relatively occluded; this occlusion is not embolic, but reversible and partial.^{5,6} Accordingly, the prognosis for CLAO with CRVO is quite good, in general, because the CLAO is temporary and the CRVO is perfused. However, neovascular glaucoma may occur infrequently in conjunction with this condition.

Case Report

Complaining of a sudden visual loss and central scotoma of the right eye, which had occurred 3 days previously, a 62-year-old man visited the Department of Ophthalmology at Chonnam University Hospital on May 10, 1999. He had diabetes mellitus that had been detected 2 years previously and was well controlled with hypoglycemics, and borderline essential hypertension not being treated with any medication. He was a heavy smoker and heavy drinker. Visual acuity was counting fingers in the right eye and 20/20 in the left. Intraocular pressure (IOP) was 19 mm Hg in both eyes; there was no distinct afferent pupillary defect or abnormal finding by simple slit-lamp microscope examination. Ophthalmoscopy showed normal findings in the left eye but, in the right eye, mildly dilated and tortuous retinal veins, scattered retinal hemorrhages in four quadrants and macula, and an elongated, geographic area of retinal whitening temporal to the optic disc with-

out optic disc edema or cotton-wool spots (Figure 1). Fluorescein angiography demonstrated a temporal cilioretinal artery that did not fill until more than 20 seconds after branch retinal artery filling was complete. The retinal arteriovenous transit time was prolonged to more than 30 seconds (Figure 2). We consulted with the cardiovascular and endocrinology departments for the evaluation of systemic diseases. Ophthalmological follow-up for IOP, gonioscopy, and changes in retinal findings was performed at intervals of 1–2 weeks. Seven weeks later, IOP was 18 mm Hg in the right eye. Retinal whitening had almost disappeared, dilation and tortuosity of the retinal veins decreased, and the retinal hemorrhage increased slightly (Figure 3). On July 12, the patient visited urgently, complaining of decreased vision. Visual acuity was hand motion in the right eye, and hazy cornea and neovascularization of iris and angle was found, with IOP of 42 mm Hg and the anterior chamber angle of D40r of Shaffer's classification. The retina could not be observed in detail due to corneal edema. Argon laser panretinal photocoagulation was performed repeatedly, and anti-glaucomatous medications such as β -blocker, carbonic anhydrase inhibitor, and latanoprost were prescribed. Two weeks later, after the first laser photocoagulation, the IOP was 34 mm Hg, and laser photocoagulation was performed again for the retinal ablation. During the follow-up period, IOP remained between 35 mm Hg and 28 mm Hg in spite of the retinal ablation. Because the IOP increased to 48 mm Hg, tra-

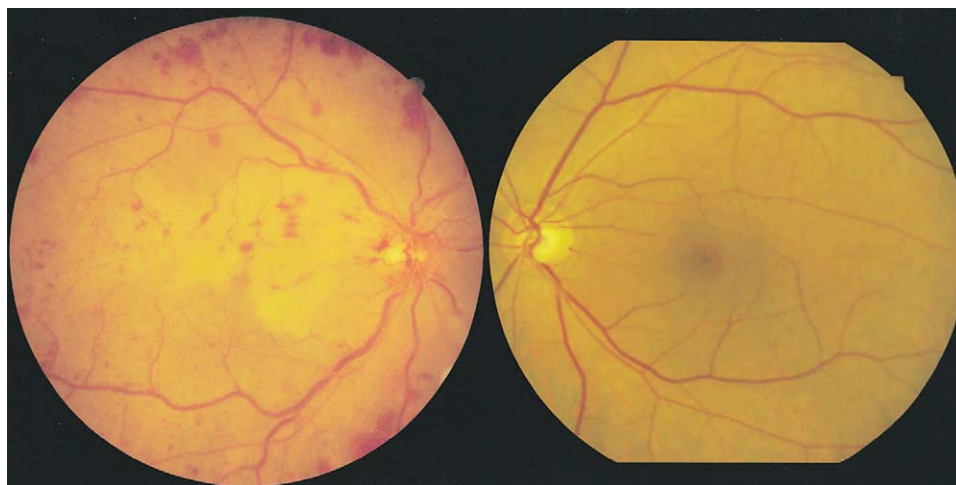


Figure 1. On May 10, 1999, the right eye of a 62-year-old patient, with diabetes mellitus and essential hypertension, showed mildly dilated and tortuous retinal veins, scattered retinal hemorrhages in four quadrants and macula, and an elongated, geographic area of retinal ischemic whitening temporal to the optic disc. There were no significant abnormal findings in the left eye.

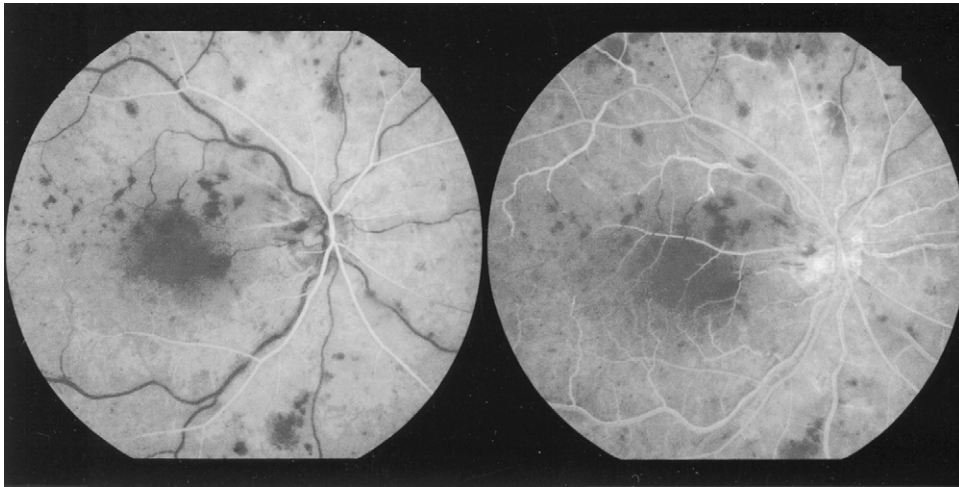


Figure 2. Fluorescein angiography of the right eye demonstrated delayed filling of the central retinal vein and cilioretinal artery (right side: 41.3 seconds; left side: 2 minutes, 36.5 seconds).

beculectomy was undertaken on December 7, and the IOP was reduced to 10 mm Hg. One week later, a whitish central retinal artery could be seen through the clear cornea, with visual acuity of hand motion in the right eye (Figure 4). On cardiac echography, there was no atherosclerosis in either carotid artery and no evidence of embolic source in the heart. However, on magnetic resonance angiography (MRA), the right

distal common carotid artery was irregularly narrowed around the bifurcation and the right ophthalmic artery was almost entirely occluded (Figure 5). On June 20, 2001, visual acuity was light perception in the right eye and 20/20 in the left eye, and IOP was 15 mm Hg in the right eye and 19 mm Hg in the left eye. There was no neovascularization of the retina or iris, or retinal hemorrhage in the right eye (Figure 6), and normal vasculature in the left eye.

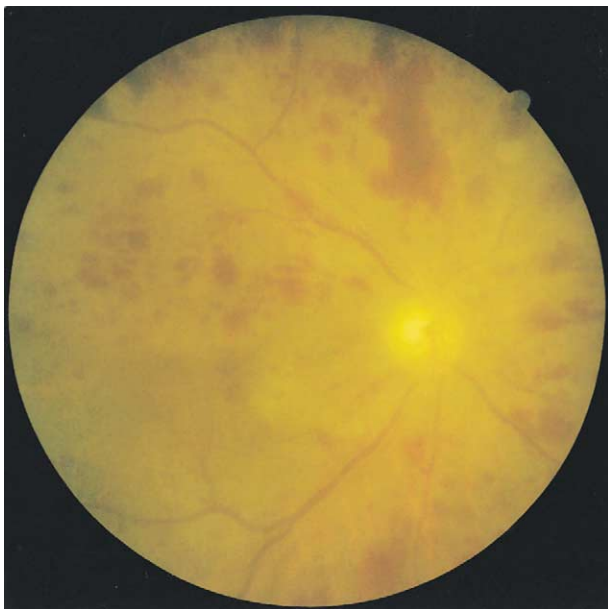


Figure 3. In the right eye on June 28, 1999, retinal whitening had almost disappeared, dilation and tortuosity of the retinal veins decreased, and the retinal hemorrhage increased slightly.

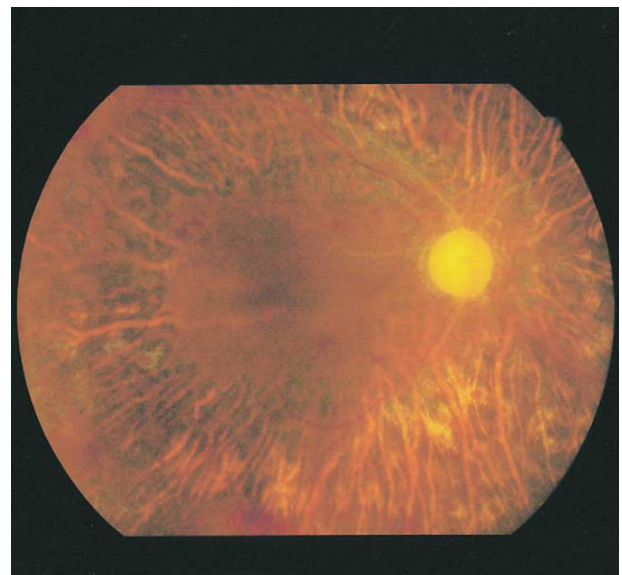


Figure 4. Shown are whitish lines indicating occluded central retinal and cilioretinal artery, and extensive changes of retinal pigment epithelium induced by panretinal photocoagulation in the right eye on December 15, 1999.

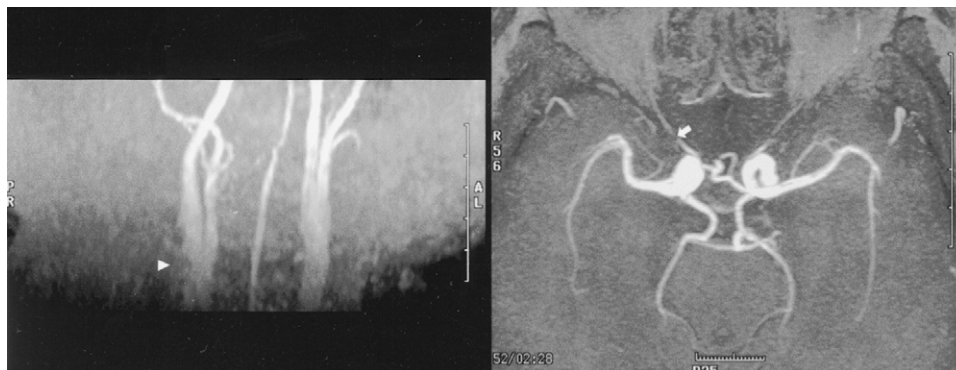

Figure 5. On magnetic resonance angiography, the right distal common carotid artery was found to be irregularly narrowed around the bifurcation (arrowhead), and the right ophthalmic artery was almost occluded (arrow).

Discussion

The prognosis of CRVO is related directly to the type of perfusion. Approximately 30% of all eyes with CRVO are nonperfused; neovascular glaucoma has been reported to develop in from 40% to 60% of these eyes. The risk factors for iris or angle neovascularization are: the amount of nonperfused retina, prophylactic laser treatment, visual acuity less than 20/200, duration of CRVO less than 1 month, moderate or severe venous tortuosity, and severe retinal hemorrhage.⁷ Even when eyes are the perfused type, a portion progresses to the nonperfused type; predictors of the progression are duration of CRVO of less than 1 month, visual acuity of less than 20/200, and the presence of five to nine disc areas of nonperfusion based on fluorescein angiography.⁸ Also, 1% of a well perfused type with a nonperfused area of less than 5 disc areas can progress to the nonperfused type. Accordingly, CRVO with CLAO can rarely re-

sult in neovascular glaucoma even though its prognosis is usually good. Schatz et al⁵ reported that 8 of 9 eyes that underwent follow-up examination had a final visual acuity of 20/30 or better, and Keyser et al⁹ reported the final visual acuity was 20/40 or better in 3 of 4 patients. However, in 2 of 11 patients in another report, rubeotic glaucoma developed within 3 months of presentation, but no detailed explanation was provided.⁶

In our case, neovascular glaucoma occurred early and severely 2 months after the initial decrease in vision, and could not be controlled by laser panretinal photocoagulation. We believe subsequent obstruction of the retinal vessels was implicated in carotid artery stenosis induced by several risk factors such as diabetes mellitus, hypertension, and heavy smoking and drinking. MRA is useful to evaluate the patency of the carotid and ophthalmic artery, because it is simple and noninvasive. Therefore, when ocular is-

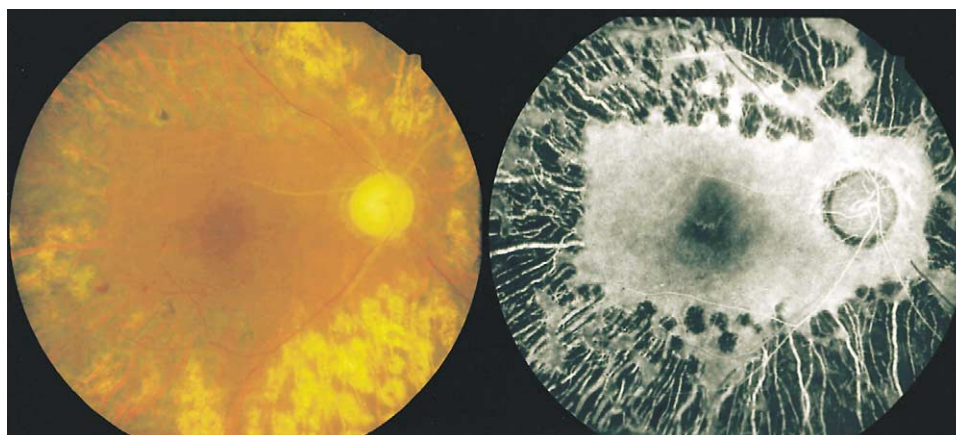


Figure 6. On June 20, 2001, there was no retinal neovascularization or hemorrhage in the right eye (56.5 seconds).

chemic syndrome is suspected, it may be necessary to recommend MRA.

In conclusion, CLAO with CRVO can result in intractable neovascular glaucoma, and should be followed up closely in patients with multiple risk factors such as advanced age, poor visual acuity, systemic disease, heavy smoking and drinking habits, short duration of CRVO, and extensive cilioretinal infarction.

References

1. Hayreh SS. The cilioretinal arteries. *Br J Ophthalmol* 1963; 47:71–6.
2. Justice J, Lehmann RP. Cilioretinal arteries: a study based on review of stereo fundus photographs and fluorescein angiographic findings. *Arch Ophthalmol* 1976;94:1355–8.
3. Jackson E. Cilioretinal and other anomalous retinal vessels. *Ophthalmol Rev* 1911;30:264.
4. Brown GC, Moffat K, Cruess A, Mamargal LE, Goldberg RE. Cilioretinal artery obstruction. *Retina* 1983;3:182–7.
5. Schatz H, Fong ACO, McDonald R, Johnson RN, Yannuzzi LA, Wendel RT. Cilioretinal artery occlusion in young adults with central retinal vein occlusion. *Ophthalmology* 1991;98: 594–601.
6. McLeod D, Ring CP. Cilioretinal infarction after retinal vein occlusion. *Br J Ophthalmol* 1976;60:419–27.
7. The Central Vein Occlusion Study Group. A randomized clinical trial of early panretinal photocoagulation for ischemic central vein occlusion. *Ophthalmology* 1995;102:1434–44.
8. The Central Vein Occlusion Study Group. Baseline and early natural history report. *Arch Ophthalmol* 1993;111:1087–95.
9. Keyser BJ, Duker JS, Brown GC, Sergott RC, Bosley TM. Combined central retinal vein occlusion and cilioretinal artery occlusion associated with prolonged retinal arterial filling. *Am J Ophthalmol* 1994;117:308–13.