

Supraciliochoroidal Fluid at an Early Stage After Trabeculectomy

Kota Sugimoto, Kunio Ito, Koji Esaki,
Masataka Miyamura, Mikio Sasoh and Yukitaka Uji

*Department of Ophthalmology, Mie
University, School of Medicine, Tsu, Mie, Japan*

Purpose: To detect the presence of supraciliochoroidal fluid (SCF) by ultrasound biomicroscopy (UBM) at an early stage after trabeculectomy.

Methods: Trabeculectomy with mitomycin C was performed on 14 patients (15 eyes) with medically uncontrolled glaucoma. The ciliary bodies were observed using UBM testing, which was conducted preoperatively and within 2 weeks after the procedure.

Results: SCF was detected postoperatively in 6 eyes. One eye also had choroidal detachment (CD), as seen with an indirect ophthalmoscope; and 5 eyes (33%) had SCF without intraocular inflammatory clinical signs, postoperative changes of the anterior chamber depth, or obvious CD. The SCF in 4 eyes disappeared within 4 weeks after the trabeculectomy. The intraocular pressure (IOP) was 6.4 ± 3.4 mm Hg (mean \pm SD) when SCF was detected and it rose to 13.2 ± 7.2 mm Hg when the SCF disappeared. The IOP was 11.4 ± 4.0 mm Hg in the eyes without SCF, which was significantly higher than that seen in the eyes with SCF.

Conclusions: At an early stage after trabeculectomy, SCF without subclinical CD was detected in some cases by UBM. Compared with the reported frequency of SCF after 3 or 6 months, our study revealed that SCF was present more frequently at an early stage after trabeculectomy. Our results may indicate that the presence of SCF is related to the early low IOP after trabeculectomy and that the disappearance of SCF induces the elevation of IOP. **Jpn J Ophthalmol 2002;46:548–552** © 2002 Japanese Ophthalmological Society

Key Words: Choroidal detachment, glaucoma, supraciliochoroidal fluid, trabeculectomy, ultrasound biomicroscopy.

Introduction

Trabeculectomy with the use of antimetabolites, such as 5-fluorouracil and mitomycin C, is currently the preferred surgical option for glaucoma. However, this procedure can cause various postoperative complications, including shallow anterior chamber, excessive filtration, choroidal detachment (CD), and malignant glaucoma.^{1–3} Trabeculectomy employing a tightly sutured scleral flap and the use of postoperative laser suture lysis has been reported to decrease postoperative complications.^{4–9}

Recently, Pavlin et al reported that ultrasound biomicroscopy (UBM) facilitates the detection of su-

praciliary and suprachoroidal fluid.¹⁰ Martinez-Bello et al reported that 12.5% of the eyes that underwent trabeculectomy were found to have supraciliochoroidal fluid (SCF) at 3 or 6 months after surgery.¹¹ In this study we investigated the presence of early stage SCF through examination of surgical patients within 2 weeks of a trabeculectomy procedure. We also present hypotheses concerning the mechanisms seen in trabeculectomies at early stages.

Materials and Methods

Patients

We studied 14 patients (15 eyes) who presented with medically uncontrolled glaucoma and who underwent a trabeculectomy in our hospital. There were 8 men and 6 women, with a mean age of 60.7 ± 12.8 years (mean \pm SD). Patients were excluded from this

Received: September 21, 2001

Correspondence and reprint requests to: Kunio ITO, MD, Department of Ophthalmology, Mie University, School of Medicine, 2-174 Edobashi, Tsu, Mie Prefecture 514-8507, Japan

study if they had postoperative complications before the first UBM testing point after trabeculectomy, due to such factors as leakage from the conjunctival wound, severe corneal damage, and excessive shallowing of the anterior chamber caused by overfiltration. Patients who underwent trabeculectomy combined with cataract surgery were also excluded. The following diagnoses for the glaucomas were made. Primary open angle glaucoma (POAG): 6 eyes, primary angle closure glaucoma: 2 eyes, exfoliation syndrome: 4 eyes, secondary glaucoma: 1 eye, neovascular glaucoma: 2 eyes. Complete eye examinations, including slit-lamp microscopy, applanation tonometry (using Goldmann tonometry), and fundus examinations (using a binocular indirect ophthalmoscope) were performed before and after the surgery.

Trabeculectomy

After creation of the limbal-based conjunctival incision, a scleral flap of about one-half thickness was created. Mitomycin C (0.04%) was administered as a single application with a sponge to both the bed of the dissected scleral region and over the area of the full sclera thickness beneath the conjunctival flap for 3 to 5 minutes. After a washout of the mitomycin C, the deep block was excised. The superficial scleral flap was sutured using an interrupted 10-0 nylon suture. Finally, the conjunctival flap was closed with a running 10-0 nylon suture. When necessary, suture lysis was performed postoperatively with an argon laser.

Observation of SCF

The Humphrey UBM 840 system (Humphrey Instruments, San Leandro, CA, USA) was used to observe the ciliary body and angle region. The UBM observation was done preoperatively (2–3 days before the operation) and within 2 weeks after the trabeculectomy. For cases where SCF was detected at the first UBM testing point after trabeculectomy, we followed the SCF continuously. To reduce complications from the testing procedure, such as conjunctival wound damage or corneal epithelial injury, the same person who was skilled in the testing technique conducted all tests. The UBM image for SCF was defined as the hypoechogenic area between the sclera and ciliary body.

Statistical Methods

The comparisons of intraocular pressure (IOP) intra-group and between groups were performed using

the Wilcoxon signed-rank test and the Mann-Whitney *U*-test, respectively. $P < .05$ was considered statistically significant.

Results

SCF was not detected preoperatively in any of the 15 eyes followed in this study. Postoperatively, 6 eyes were found to have SCF. One of these eyes (case 5) was also found to have CD observable by ophthalmoscopy. All of the remaining 5 eyes (33%, Group 1: cases 1–4) had documented SCF despite the absence of intraocular inflammatory clinical signs, postoperative changes of the anterior chamber depth, or obvious CD (Table 1). Within this group, SCF was found in one quadrant in 1 eye, in two quadrants in one eye and in all four quadrants in 3 eyes. The SCF in 4 of the eyes disappeared within 4 weeks after trabeculectomy. In 1 eye, SCF was found to disappear after 3 months. Due to leakage from a postoperative conjunctival wound, UBM testing before this point was not possible, and thus earlier SCF disappearance could not be verified. The mean IOP was 6.4 ± 3.4 mm Hg in the 5 eyes found to have SCF (Group 1: cases 1–4) at the first postoperative UBM testing point. On the other hand, in the 9 eyes in which SCF was not found (Group 2), the mean IOP was 11.4 ± 4.0 mm Hg (cases 6–14). These values were significantly higher than those found in Group 1 ($P = .0329$). At the point where SCF disappeared in Group 1, the mean IOP rose to 13.2 ± 7.2 mm Hg ($P = .0679$). There was no significant difference ($P = .1425$) between the lowest postoperative IOPs that were measured prior to the first postoperative UBM testing point in Groups 1 (5.6 ± 3.8 mm Hg) and 2 (8.1 ± 3.9 mm Hg).

Case Reports

Case 1

We performed trabeculectomy with mitomycin C on the left eye of a 57-year-old man with POAG. Although the IOP decreased to 5 mm Hg and the filtering bleb, anterior segment and fundus had no observable problems on the 8th postoperative day, the UBM test detected SCF in two quadrants including the area where the trabeculectomy had been performed (Figure 1A). By the 14th postoperative day the SCF had disappeared, and the IOP rose to 11 mm Hg (Figure 1B). The filtering bleb, anterior segment, and fundus exhibited no obvious changes.

Table 1. First Postoperative Ultrasound Biomicroscopical Testing*

Case No.	Age (y)	Sex (M/F)	Side (R/L)	Diagnosis/ Surgical History	Lowest IOP Before First UBM Testing (mm Hg)	Extent of SCF (Quadrants)	IOP (mm Hg)	Course of SCF	IOP When SCF Disappeared (mm Hg)
Patients with SCF									
1	57	M	L	POAG (-)	5	2	5	Disappearance after 14 days	11
2	48	F	R	POAG LOT	5	4	7	Disappearance after 16 days	14
			L	POAG LOT	4	4	4	Detection of disappearance after 3 months	13
3	72	F	L	PACG PEA+IOL+GSL	12	4	12	Disappearance after 24 days	24
4	56	M	R	PE LOT, LOT, LEC	2	1	4	Disappearance after 20 days	4
Patient with CD and SCF									
5	74	M	L	PACG LI	8	4	12		
Patients without SCF									
6	67	M	R	POAG LTP	5	-	18	/	
7	33	F	R	POAG LOT	6	-	8	/	
8	59	M	L	NVG (-)	6	-	8	/	
9	51	F	R	NVG VIT+PEA	4	-	11	/	
10	60	F	L	SG VIT+PEA+IOL	11	-	11	/	
				LEC					
11	72	M	L	PE (-)	8	-	12	/	
12	49	M	R	POAG LEC	17	-	18	/	
13	76	M	L	PE (-)	8	-	9	/	
14	76	F	R	PE LEC+PEA+IOL	8	-	8	/	

*M: male, F: female, R: right, L: left, IOP: intraocular pressure, UBM: ultrasound biomicroscopy, SCF: supraciliochoroidal fluid, POAG: primary open-angle glaucoma, LOT: trabeculotomy, PACG: primary angle closure glaucoma, PEA: phacoemulsification, IOL: intraocular lens, GSL: goniosynechialysis, LEC: trabeculectomy, CD: choroidal detachment, LI: laser iridotomy, LTP: laser trabeculoplasty, NVG: neovascular glaucoma, SG: secondary glaucoma, VIT: vitrectomy, PE: pseudoexfoliation syndrome.

Case 2

We performed trabeculectomy with mitomycin C on the right eye of a 48-year-old woman with POAG who had had a trabeculotomy procedure done 5 years previously. Preoperative UBM testing did not detect SCF (Figure 2A). Although the IOP decreased to 7 mm Hg and the filtering bleb, anterior segment, and fundus exhibited no problems on the 8th day postoperatively, SCF was detected in all four quadrants by UBM (Figure 2B). On the 16th day postoperatively the IOP rose to 10 mm Hg and the SCF disappeared without any changes seen in the anterior segment and fundus (Figure 2C).

Discussion

Diagnosis of CD and the existence of suprachoroidal fluid is generally made by the use of indirect ophthalmoscopy. Recently the use of B-mode ultrasonography has been reported to make the diagnosis

easier.^{12–13} Popovic et al reported that postoperative CD after trabeculectomy was diagnosed in 59% of their patients. This high rate of CD may be partly explained by the use of ultrasonography as opposed to ophthalmoscopy. However, diagnosis of SCF without CD is difficult to make even with the use of ultrasonography. UBM, which uses a 50-MHz transducer, enabled us to distinctly view the microstructure of the anterior segment and anterior chamber angle. Detection of SCF after glaucoma surgery using UBM has recently been reported.^{11,14} SCF was detected in 51% of patients after deep sclerectomy and continued to exist in 24% of the eyes at 18 months after surgery.¹⁴ On the other hand, after trabeculectomy, SCF was reported to be detected in 12.5% at 3 or 6 months after surgery.¹¹ In our study, we found that within 2 weeks of the procedure, 33% of the post-trabeculectomy eyes were confirmed to have SCF despite the absence of CD. This frequency (33%) was thought to be higher than results reported for similar cases at

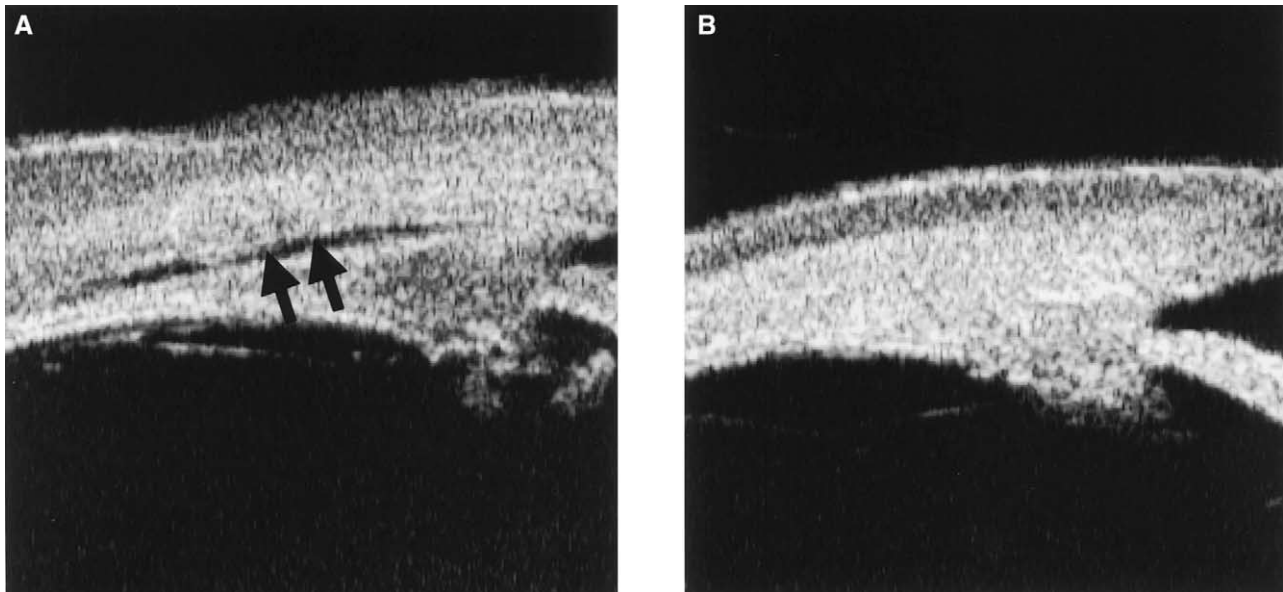


Figure 1. Ultrasound biomicroscopic image of ciliary body region in case 1. (A) The hypoechoic area between sclera and ciliary body (supraciliochoroidal fluid [SCF]) on the ultrasound biomicroscopic image was observed (arrows) on 8th postoperative day. (B) The SCF was not detected on 14th postoperative day.

3 or 6 months.¹¹ In addition, the eyes detected with SCF in this study did not have the intraocular inflammatory clinical signs, changes in anterior chamber depth or obvious CD. These findings indicate that SCF may be detected frequently at an early stage after trabeculectomy, despite the absence of obvious complications such as overfiltration, and that the observed SCF may disappear over a very short period of time.

It was generally thought that the flow of aqueous humor into the filtering bleb leads to IOP reduction in trabeculectomy.¹⁵ This study, in line with other past reports, supports the supposition that one of the mechanisms for lowering IOP during the immediate period after trabeculectomy is the production of SCF due to increased uveoscleral outflow.¹¹ This mechanism is also supported by our results indicating that the IOP in eyes found to have SCF was significantly lower than in eyes where SCF was not detected, and also by our data that showed a rise in IOP when the SCF disappeared as compared with when SCF was first detected.

SCF is considered to result from iatrogenic cyclo-dialysis due to the surgery.¹¹ Surgical procedures such as traction of the iris root during a peripheral iridectomy and the subsequent damage and low IOPs on excision of the deep block were considered to be the causes of SCF in trabeculectomy cases. The wider scleral excision area and the more extensive

surgical damage to the ciliary body that occurs during a deep sclerectomy could explain why SCF was more frequently detected in deep sclerectomy than in trabeculectomy. However, some reports have shown that ciliochoroidal detachment does not influence the production of aqueous humor, but instead, it is the increased uveoscleral outflow that causes the ocular hypotony seen in the experimental monkey model for ciliochoroidal detachment and cyclo-dialysis.¹⁶⁻¹⁸ Thus, it may be that the surgical damage caused by the trabeculectomy procedure leads to an increase in the flow of aqueous humor to the supraciliochoroidal space from the anterior chamber, due to the resulting decrease in flow resistance in the ciliary muscle bundle. Consequently, this leads to lower tension and an IOP that is lower than the venous pressure of the ciliary body, thus causing the SCF.

In our study, we examined subjects with various types of glaucomas, not only POAG, but also patients that have had a history of glaucoma laser therapy and intraocular surgery such as trabeculotomy and vitrectomy. The possibility that these elements might affect the mechanisms for SCF occurrence cannot be ruled out and must be considered in any analysis of the results of trabeculectomy. Of the 15 eyes in our study, 2 eyes in which SCF was not detected had been subjected to previous vitrectomy. It could be that eyes with a history of intraocular surgery do not exhibit an obviously higher frequency of

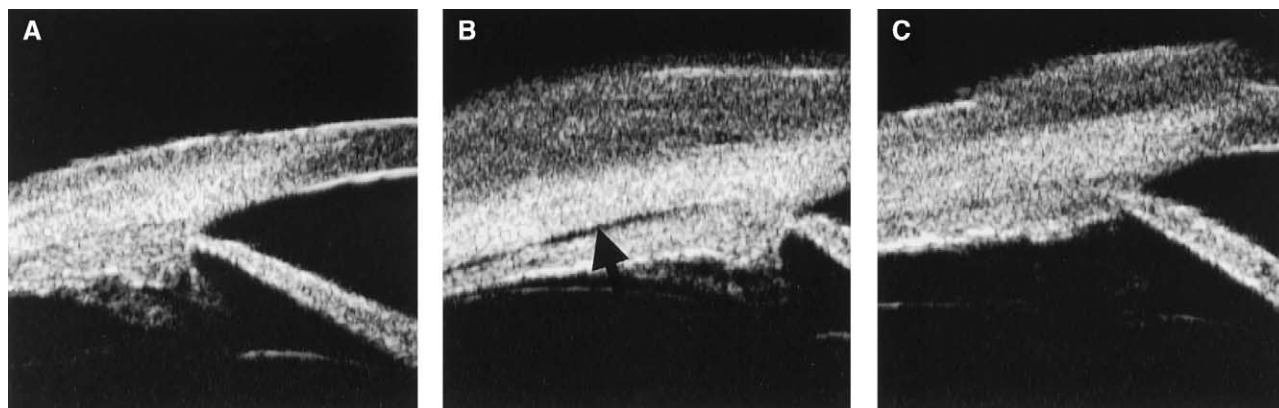


Figure 2. Ultrasound biomicroscopic image of ciliary body region in case 2. (A) Supraciliochoroidal fluid (SCF) was not observed preoperatively. (B) SCF was detected on 8th postoperative day (arrows). (C) The SCF had disappeared on 16th postoperative day.

detected SCF. In the future, we need to investigate the separate glaucoma types in conjunction with histories of intraocular surgery in order to elucidate the risk factors and mechanisms of SCF appearance.

This paper was published in Japanese in *Nippon Ganka Gakkai Zasshi (J Jpn Ophthalmol Soc)* 2001;105:766–770. It appears here in a modified form after peer review and editing for the *Japanese Journal of Ophthalmology*.

References

- Liebmann LM, Ritch R. Complications of glaucoma filtering surgery. In: Ritch R, Shields B, Krupin T, eds. *The glaucomas*. St. Louis: CV Mosby, 1996:1703–1736.
- Matsuda T, Tanihara M, Hangai M, Chihara E, Honda Y. Surgical results and complications of trabeculectomy with intraoperative application of mitomycin C. *Jpn J Ophthalmol* 1996;40:526–532.
- Shirato S, Kitazawa Y, Mishima S. A critical analysis of the trabeculectomy results by a prospective follow-up design. *Jpn J Ophthalmol* 1982;26:468–480.
- Savage JA, Condon GP, Lytle RA, Simmons RJ. Laser suture lysis after trabeculectomy. *Ophthalmology* 1988;95:1631–1638.
- Melamed S, Ashkenazi I, Glovinski J, Blumenthal M. Tight scleral flap trabeculectomy with postoperative laser suture lysis. *Am J Ophthalmol* 1990;109:303–309.
- Kiuchi Y, Mishima H, Takamatsu M. Laser suture lysis after tight scleral flap trabeculectomy. *Nihon Ganka Kyo (Folia Ophthalmol Jpn)* 1995;46:33–37.
- Hara T, Shirato S, Miyata N, Eguchi K, Takada M. Primary trabeculectomy for open-angle glaucoma with mitomycin C. *Nippon Ganka Gakkai Zasshi (J Jpn Ophthalmol Soc)* 1995;99:1283–1288.
- Yamamoto T, Ichien M, Suemori-Matsushita H, Kitazawa Y. Trabeculectomy for normal-tension glaucoma. *Nippon Ganka Gakkai Zasshi (J Jpn Ophthalmol Soc)* 1994;98:579–583.
- Suzuki M. Complications of glaucoma surgeries. *Atarashii Ganka (J Eye)* 1999;16:927–931.
- Pavlin CJ, Easterbrook M, Harasiewicz K, Foster FS. An ultrasound biomicroscopic analysis of angle-closure glaucoma secondary to ciliochoroidal effusion in IgA nephropathy. *Am J Ophthalmol* 1993;116:341–345.
- Martinez-Bello C, Capeans C, Sanchez-Salorio M. Ultrasound biomicroscopy in the diagnosis of supraciliochoroidal fluid after trabeculectomy. *Am J Ophthalmol* 1999;128:372–375.
- Dugel PU, Heuer DK, Thach AB, et al. Annular peripheral choroidal detachment simulating aqueous misdirection after glaucoma surgery. *Ophthalmology* 1997;104:439–444.
- Popovic V. Early choroidal detachment after trabeculectomy. *Acta Ophthalmol Scand* 1998;76:361–371.
- Chiou AG, Mermoud A, Underdahl JP, Schnyder CC. An ultrasound biomicroscopic study of eyes after deep sclerectomy with collagen implant. *Ophthalmology* 1998;105:746–750.
- Shields MB. Filtering surgery. In: Shields MB, ed. *Textbook of glaucoma*. 4th ed. Baltimore: Williams & Wilkins, 1998:504–537.
- Okisaka S. Outflow pathway. *Nippon Ganka Gakkai Zasshi (J Jpn Ophthalmol Soc)* 2000;104:517–530.
- Pederson JE, Gaasterland DE, McLellan HM. Experimental ciliochoroidal detachment. Effect on intraocular pressure and aqueous flow. *Arch Ophthalmol* 1979;97:536–541.
- Suguro K, Toris CB, Pederson JE. Uveoscleral outflow following cyclodialysis in the monkey eye using a fluorescent tracer. *Invest Ophthalmol Vis Sci* 1985;26:810–813.