

# Effect of High-dose Intravenous Steroid Pulse Therapy Followed by 3-Month Oral Steroid Therapy for Graves' Ophthalmopathy

Kenji Ohtsuka, Akihiko Sato,  
Satoshi Kawaguchi, Masato Hashimoto and Yasuo Suzuki

*Department of Ophthalmology, Sapporo Medical  
University, School of Medicine, Sapporo, Hokkaido, Japan*

---

**Purpose:** To evaluate the effect of high-dose intravenous steroid pulse therapy followed by 3-month oral steroid therapy for Graves' ophthalmopathy.

**Methods:** We selected 41 Japanese patients (age range, 21–76 years; mean = 49 years) who had active Graves' ophthalmopathy among 205 consecutive patients examined at Sapporo Medical University Hospital between 1997 and 1999. In a prospective study, we investigated the effect on the 41 patients of high-dose intravenous methylprednisolone pulse therapy (1 g/day × 3 days × 3 times) followed by 3-month oral prednisone therapy. Coronal computed tomography (CT) of the orbit, exophthalmometry and monocular fixation field measured by Goldmann perimetry were carried out before the steroid pulse therapy, and 1 and 6 months after the steroid pulse therapy. The maximum coronal section area of the rectus muscle in each eye was measured using an orbital CT image.

**Results:** Extraocular muscle hypertrophy was significantly reduced 1 and 6 months after the pulse therapy (paired *t*-test,  $P < .01$ ), and was not significantly different between 1 and 6 months after the pulse therapy. Proptosis was not significantly reduced by the pulse therapy. Monocular fixation fields were measured in 34 patients with diplopia, and limitation of eye movements was improved in 15 patients (44%) by the pulse therapy. In the other patients, improvement of the limitation was not detectable by the test of the monocular fixation field.

**Conclusions:** The treatment in this study is effective for extraocular muscle hypertrophy, and relapse was minimum within 6 months. However, this treatment has limited effect on limitation of eye movements and less effect on proptosis. **Jpn J Ophthalmol 2002;46:563–567** © 2002 Japanese Ophthalmological Society

**Key Words:** Extraocular muscle hypertrophy, Graves' disease, Graves' ophthalmopathy, proptosis, steroid pulse therapy.

---

## Introduction

Graves' ophthalmopathy is a chronic autoimmune process that affects the retrobulbar tissue and has strong etiological links with autoimmune thyroid disease. Symptoms include blurring of vision, proptosis, extraocular muscle dysfunction, eyelid swelling, chemosis, redness of the conjunctiva, pain, lid lag, and re-

traction. Steroid has been used for treatment of Graves' ophthalmopathy. Many previous studies have shown the therapeutic benefits of steroid therapy.<sup>1–4</sup> Recently the efficacy of high-dose intravenous steroid pulse therapy has been reported.<sup>5–9</sup> Patients treated with high-dose intravenous steroid had a better outcome than those treated with an oral dose of steroid.

In this study, we evaluated the efficacy of high-dose intravenous steroid pulse therapy followed by 3-month oral steroid therapy on extraocular muscle hypertrophy, limitation of eye movements, and proptosis in patients with Graves' ophthalmopathy. Be-

---

Received: October 24, 2001

Correspondence and reprint requests to: Kenji OHTSUKA, MD, PhD, Department of Ophthalmology, Sapporo Medical University, School of Medicine, S-1, W-16, Chuo-ku, Sapporo 060, Japan

fore the therapy, we evaluated the activity of ophthalmopathy using the classification system proposed by Mourits et al,<sup>10</sup> and performed the above therapy only in patients classified as having active ophthalmopathy.

## Materials and Methods

The diagnosis of Graves' disease was based on history, the presence of conventional symptoms of thyrotoxicosis associated with a diffusely enlarged goiter, elevated levels of serum T3, free T3, T4, and free T4, and increased thyroidal <sup>131</sup>I uptake; elevated titers of antithyroid stimulating antibody, antithyroglobulin antibody, and antithyroid peroxidase antibody, or the presence of ophthalmopathy, such as proptosis, extraocular muscle hypertrophy, orbital congestion, eyelid retraction, and orbital inflammation, provided supporting evidence for the diagnosis. A complete ophthalmic examination including applanation tonometry, exophthalmometry, funduscopy, and measurement of eye movements was performed by the same ophthalmologist at the first visit, before commencement of any systemic medical treatment, in all patients. The activity of ophthalmopathy was evaluated using the classification system proposed by Mourits et al.<sup>10</sup>

We selected 41 Japanese patients (33 women, 8 men; age range, 21-76 years; mean = 49 years) who had active ophthalmopathy, that is, a clinical activity score of  $\geq 4$  points based on the classification system, or impaired function during a period of time between 1 and 3 months (decrease in visual acuity or decrease of eye movements) among 205 consecutive patients examined at Sapporo Medical University Hospital between 1997 and 1999. Mourits et al<sup>10</sup> indicated that patients with 3 or more points improve on oral steroid treatment. In our clinic, patients with 3 points are treated by oral steroid, and patients with 4 or more points participated in this clinical trial of high-dose steroid pulse therapy followed by oral steroid. In a prospective study, we investigated the effect of high-dose intravenous methylprednisolone pulse therapy followed by 3-month oral prednisone therapy on these 41 patients.

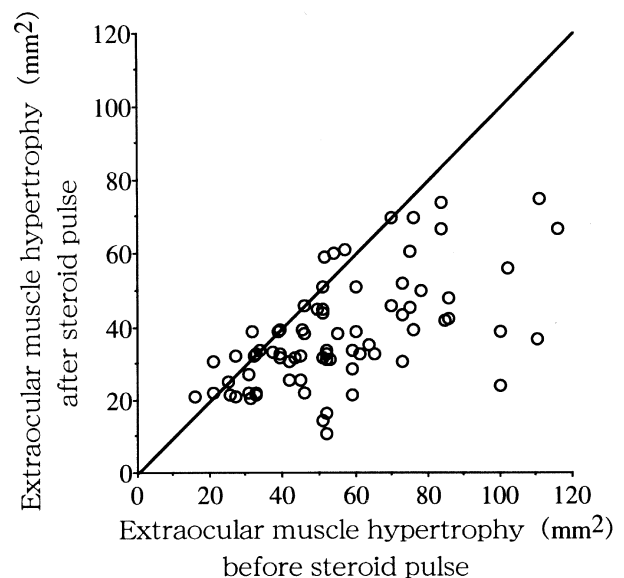
Methylprednisolone was administered intravenously at a daily dosage of 1 g for 3 successive days. This treatment was repeated three times for 3 weeks. A dose of 30 mg of oral prednisone was administered to each patient as interpulse therapy. Oral prednisone therapy following intravenous methylprednisolone pulse therapy was also performed (30

mg initial dose, tapered by 3 months after the steroid pulse therapy) in all patients.

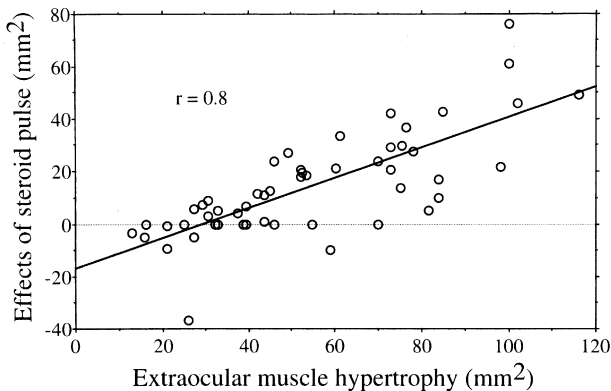
Serial scans of coronal computed tomography (CT) of the orbit, exophthalmometry, and monocular fixation field tested by Goldmann perimetry using the I-4 target were performed before the steroid pulse therapy, and 1 and 6 months after the steroid pulse therapy. Thickness of extraocular muscles (maximum coronal section area of the most hypertrophic rectus muscle in each eye) was measured based on orbital CT by a microcomputer using NIH Image before the steroid pulse therapy, and at 1 month and 6 months after the steroid pulse therapy. The signal density of extraocular muscles was easily detected by a microcomputer because of the high contrast of signal densities between orbital fat and muscles. Changes of monocular fixation field  $\geq 10^\circ$  were designated as the improvement of limitation of eye movements. Informed consent was obtained from all the patients after the nature of the study had been explained. All study protocols were approved by the Sapporo Medical University Clinical Study Committee.

## Results

Extraocular muscle hypertrophy was improved immediately after the steroid pulse therapy. Figure 1 shows relationships between extraocular muscle hy-

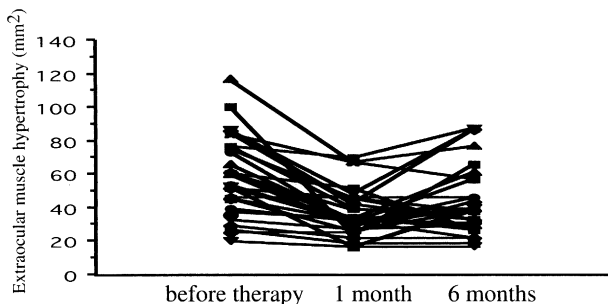


**Figure 1.** Relationships between extraocular muscle hypertrophy (the maximum coronal section area of the rectus muscle) before and 1 month after the steroid pulse therapy.



**Figure 2.** Relationships between extraocular muscle hypertrophy before the steroid pulse therapy and the effect of the steroid pulse therapy (the maximum coronal section area of the rectus muscle before the pulse therapy—the area 1 month after the pulse therapy).

hypertrophy (the maximum coronal section area of the rectus muscle of both eyes) before and 1 month after the pulse therapy. Figure 2 shows relationships between extraocular muscle hypertrophy before the pulse therapy and the effect of steroid pulse therapy (the maximum coronal section area of the rectus muscle before the pulse therapy minus the area at 1 month after the pulse therapy). The effect of the pulse therapy on muscle hypertrophy significantly correlated with the level of muscle hypertrophy before the treatment ( $r = 0.8, P < .01$ ). The mean values of the maximum coronal section area of the rectus muscle were  $54.5 \pm 22.2 \text{ mm}^2$  (mean  $\pm$  SD;  $n = 41$ ; range, 15.8–116) before the pulse therapy,  $38.4 \pm 15.1 \text{ mm}^2$  ( $n = 41$ ; range, 16.4–75.3) 1 month after pulse therapy, and  $43.0 \pm 19.6 \text{ mm}^2$  ( $n = 41$ ; range, 16.4–87.2) 6 months after the pulse therapy (Figure 3). Extraocular muscle hypertrophy was significantly reduced 1 and 6 months after the pulse therapy (paired  $t$ -test,  $P < .01$ ), and was not significantly dif-

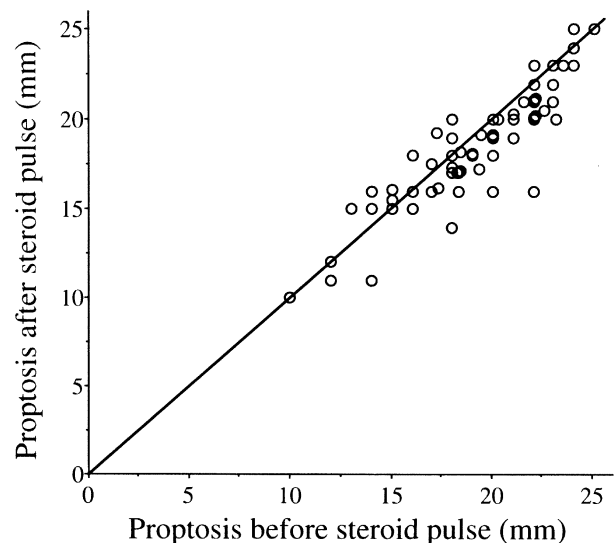


**Figure 3.** Changes in extraocular muscle hypertrophy before, and 1 and 6 months after the steroid pulse therapy.

ferent between 1 and 6 months after the pulse therapy. However, 6 months after the pulse therapy, extraocular muscle hypertrophy in 4 patients relapsed to the same or worse level as before the treatment.

Proptosis did not improve following the treatment in this study (Figure 4). The results of exophthalmometry measurements were  $18.6 \pm 2.8 \text{ mm}$  (mean  $\pm$  SD,  $n = 82$ ) before the pulse therapy,  $17.5 \pm 2.8 \text{ mm}$  ( $n = 82$ ) 1 month after the pulse therapy, and  $17.3 \pm 2.7 \text{ mm}$  ( $n = 82$ ) 6 months after the pulse therapy. Proptosis was not significantly reduced either 1 or 6 months after the pulse therapy.

In 34 of the 41 patients, diplopia was observed before the treatment, and monocular fixation fields were measured in these 34 patients. Limitation of eye movements was improved  $\geq 15^\circ$  in 15 patients (44%) by the pulse therapy. In 3 of the 15 patients, diplopia disappeared within 1 month after the pulse therapy. In 1 of the 15 patients, diplopia disappeared within 6 months after the pulse therapy. In 1 of the 15 patients, diplopia relapsed within 6 months after the pulse therapy. In 19 of the 34 patients (56%), improvement of the limitation of eye movements was not detectable in the test of the monocular fixation field. The diplopia in these patients was not improved by the treatment. The mean values of the maximum coronal section area of the rectus muscle 1 month after the pulse therapy in the 15 patients with improved limitation of eye movements and the 19 patients without the improvement was  $37.4 \pm 12.8 \text{ mm}^2$  and  $50.8 \pm 17.0 \text{ mm}^2$  (mean  $\pm$  SD), respec-



**Figure 4.** Relationships between proptosis before and after the steroid pulse therapy.

tively. These values were significantly different (Mann-Whitney *U*-test,  $P < .01$ ).

### Discussion

High-dose intravenous methylprednisolone pulse therapy followed by 3-month oral prednisone therapy was effective for extraocular muscle hypertrophy, and relapse was minimum within 6 months. However, this treatment had limited effect on the limitation of eye movements and less effect on proptosis.

Extraocular muscle hypertrophy was improved immediately after the steroid pulse therapy in this study, which is comparable with the results of previous studies.<sup>5–9</sup> The efficacy of the pulse therapy on muscle hypertrophy significantly correlated with the level of muscle hypertrophy. However, severe extraocular muscle hypertrophy did not return to the normal level following the steroid pulse therapy. The normal range of the coronal section area of the rectus muscle is from 15 to 34 mm<sup>2</sup> (mean = 26 mm<sup>2</sup>, n = 12, unpublished data). In the present study, the maximum coronal section area of the rectus muscle ranged from 16.4 to 75.3 mm<sup>2</sup> one month after the pulse therapy. Almost all muscles  $\geq 60$  mm<sup>2</sup> before the therapy were still hypertrophic ( $>40$  mm<sup>2</sup>) after the therapy (see Figure 1). This may be a reason why the therapy had a limited effect on limitation of eye movements. These findings suggest that, if the therapy were performed in patients with minimal or mild extraocular muscle hypertrophy, it would be more effective on the limitation of eye movements. Actually, extraocular muscle hypertrophy was more significantly reduced in patients with improved limitation of eye movements than in patients without the improvement in this study. In the extraocular muscles of patients with Graves' ophthalmopathy, a chronic inflammatory pattern, such as interstitial edema, an increase of interstitial tissue, excess mucopolysaccharides, and fibroblast proliferation, was noted.<sup>11</sup> Steroid can be effective for interstitial edema, but not for an increase of interstitial tissue, excess mucopolysaccharides, and fibroblast proliferation. Therefore, in order to prevent diplopia, the treatment should be performed before the occurrence of chronic inflammatory changes.

The steroid therapy in this study had less effect on proptosis. This result is comparable with those of previous studies using the intravenous methylprednisolone pulse therapy.<sup>5–9</sup> Histological examination of retrobulbar tissue samples reveals proliferation of fibroblasts accompanied by accumulation of glycosaminoglycans (GAGs).<sup>12–14</sup> GAGs are hydrophilic

molecules that directly increase orbital volume and absorb extracellular fluid, resulting in edematous changes of the orbital connective tissue.<sup>13,14</sup> Accumulation of GAGs in the orbit may play an important role in the development of proptosis in Graves' ophthalmopathy. It is probable that steroid is not effective in reducing GAGs accumulation in the orbit.

High-dose intravenous methylprednisolone pulse therapy followed by 3-month oral steroid therapy is thought to suppress the early inflammatory processes of Graves' ophthalmopathy with minimum relapse. However, this therapy has less effect on chronic inflammatory processes, such as accumulation of GAGs, and fibroblast proliferation. In this study, many patients already showed chronic inflammation, although we selected patients with active ophthalmopathy, that is, having a clinical activity score of  $\geq 4$  points. It is possible that this therapy will control inflammatory processes with minimum relapse, if it is performed on patients at an early stage of the disease. We should study the effect of preventive steroid therapy on patients with minimum ophthalmopathy at an early stage of the disease.

### References

1. Werner SC. Prednisone in emergency treatment of malignant exophthalmos. *Lancet* 1966;1:1004–1007.
2. Day RM, Carroll FD. Corticosteroid in the treatment of optic nerve involvement associated with thyroid dysfunction. *Arch Ophthalmol* 1968;79:279–282.
3. Prummel MF, Mourits MP, Berghout A, et al. Prednisone and cyclosporine in the treatment of severe Graves' ophthalmopathy. *N Engl J Med* 1989;321:1353–1359.
4. Jacobson DH, Gorman CA. Endocrine ophthalmopathy: current ideas concerning etiology, pathogenesis and treatment. *Endocrinol Rev* 1984;5:200–220.
5. Nagayama Y, Izumi M, Kiriya T, et al. Treatment of Graves' ophthalmopathy with high-dose intravenous methylprednisolone pulse therapy. *Acta Endocrinol* 1987;116:513–518.
6. Guy JR, Fageien S, Donovan JP, Rubin ML. Methylprednisolone pulse therapy in severe dysthyroid optic neuropathy. *Ophthalmology* 1989;96:1048–1052.
7. Hiromatsu Y, Tanaka K, Sato M, et al. Intravenous methylprednisolone pulse therapy for Graves' ophthalmopathy. *Endocr J* 1993;40:63–72.
8. Tagami T, Tanaka K, Sugawa H, et al. High-dose intravenous steroid pulse therapy in thyroid-associated ophthalmopathy. *Endocr J* 1996;43:689–699.
9. Matejka G, Verges B, Vaillant G, et al. Intravenous methylprednisolone pulse therapy in the treatment of Graves' ophthalmopathy. *Horm Metab Res* 1998;30:93–98.
10. Mourits MP, Koornneef L, Wiersinga WM, Prummel MF, Berghout A, Gaag R. Clinical criteria for the assessment of disease activity in Graves' ophthalmopathy: a novel approach. *Br J Ophthalmol* 1989;73:639–644.
11. Tallsted ML, Norberg R. Immunohistochemical staining of normal and Graves' extraocular muscle. *Invest Ophthalmol Vis Sci* 1988;29:175–184.

12. Campbell JC. Immunology of Graves' ophthalmopathy: retrobulbar histology and histochemistry. *Acta Endocrinol* 1989; 121(suppl 2):9-16.
13. Imai Y, Odajima R, Inoue Y, Shishiba Y. Effect of growth factors on hyaluronate and proteoglycan synthesis by retroocular tissue fibroblasts of Graves' ophthalmopathy in culture. *Acta Endocrinol* 1992;126:541-552.
14. Bahn RS, Heufelder AE. Retroocular fibroblasts: important effector cells in Graves' ophthalmopathy. *Thyroid* 1992;2: 89-94.