

# Cystoid Macular Edema Associated with Latanoprost Use in a Pseudophakic Eye with a History of Surgical Complications

Konomi Watanabe\*<sup>†</sup>, Seiji Hayasaka\*,  
Yoriko Hayasaka\*, Yasunori Nagaki\* and Kazuhiko Watanabe\*

*\*Department of Ophthalmology, Toyama Medical  
and Pharmaceutical University, Toyama, Japan;*

*<sup>†</sup>Division of Ophthalmology, Asahi General Hospital, Toyama, Japan*

---

**Purpose:** To report the development of cystoid macular edema following the use of topical latanoprost in an eye with glaucoma and pseudophakia.

**Case:** A 73-year-old woman with bilateral pseudophakia and glaucoma had been treated with topical carteolol hydrochloride and isopropyl unoprostone bilaterally. One month later the unoprostone was replaced by latanoprost bilaterally. After 1 month, the patient complained of decreased vision in the right eye, which had a history of surgical complications.

**Results:** Fluorescein angiography showed cystoid macular edema in the right fundus. The edema disappeared 2 weeks after the discontinuation of latanoprost. Cystoid macular edema did not develop in the left eye, which had no history of surgical complications.

**Conclusion:** These observations suggest that latanoprost may cause cystoid macular edema in an eye with a history of surgical complications. **Jpn J Ophthalmol 2003;47:110–112** © 2003 Japanese Ophthalmological Society

**Key Words:** Cystoid macular edema, latanoprost, surgical complications.

---

## Introduction

Latanoprost is a prostaglandin  $F_{2\alpha}$  analog that reduces intraocular pressure in patients with glaucoma. The development of cystoid macular edema has been reported after latanoprost use.<sup>1–5</sup> We recently examined a patient who developed cystoid macular edema in 1 eye following the use of topical latanoprost in both eyes. The cystoid macular edema developed in the right pseudophakic eye with a history of surgical complications. No edema was detected in the left pseudophakic eye with no history of surgical complications.

## Case Report

A 65-year-old woman with systemic hypertension had age-related cataracts in both eyes. Her past medical history was otherwise unremarkable, and no previous intraocular surgery had been performed. The patient underwent extracapsular cataract extraction with a posterior chamber intraocular lens implantation in the left eye in 1992. The intraoperative course was uneventful. The patient was scheduled to undergo the same type of cataract surgery with a posterior chamber intraocular lens implantation in the right eye in 1995. However, the posterior capsule tore, and vitreous herniation occurred during surgery. Anterior vitrectomy and sulcus fixation of the intraocular lens were performed. In 1996, her visual acuity was 1.0 OU with pupillary distortion from vitreous traction in the right eye and a round pupil in the left eye. The intraocular pressure was 17–20 mm Hg OU.

---

Received: February 20, 2002

Correspondence and reprint requests to: Konomi WATANABE, MD, Department of Ophthalmology, Toyama Medical and Pharmaceutical University, 2630 Sugitani, Toyama 930-0194, Japan

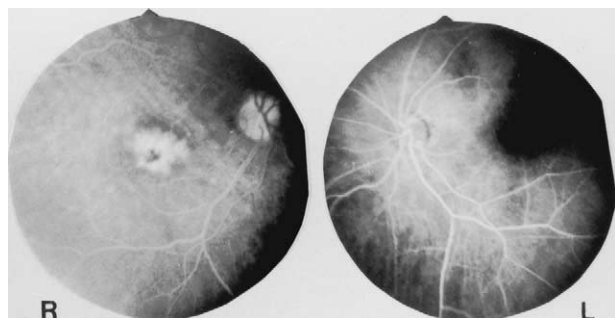In early 1997, the intraocular pressure increased to 20–25 mm Hg OU. Wide anterior chamber angles with small areas of synechia were found bilaterally. The optic discs showed large cuppings (cup/disc ratio, 0.6) bilaterally. Paracentral scotomas were found in both eyes by Humphrey field testing. The patient was treated with topical 1% carteolol hydrochloride, twice daily, and 0.12% isopropyl unoprostone (Rescula), twice daily, in both eyes, from February 1997. Her intraocular pressure was well controlled by these agents.

In mid-May 2000, intraocular pressure in both eyes gradually increased to 22–25 mm Hg. The topical isopropyl unoprostone used in both eyes was replaced by 0.005% latanoprost (Xalatan), once daily, on May 28, 2000. Topical carteolol was continued as previously in both eyes.

In June, her visual acuity was 0.7 OD and 1.0 OS, and intraocular pressure was 18–22 mm Hg OU. On July 4, her visual acuity had decreased to 0.4 OD but remained at 1.0 OS. Flare was visible in the right anterior chamber. No intracameral cells or ciliary injection were seen in either eye.

Cystoid macular edema was visible in her right fundus by funduscopy and fluorescein angiography (Figure 1). No cystoid macular edema was found in her left fundus. No posterior vitreous detachment was noted in either fundus.

Topical latanoprost was replaced by unoprostone in both eyes. Topical 0.5% dorzolamide, three times daily, was added to the other two drugs for both eyes. Topical 0.1% betamethasone disodium and 0.1% diclofenac sodium, three times daily, were prescribed for the right eye for 1 month. In mid-August, her visual acuity was 1.0 OU, and intraocular pressure was 14–18 mm Hg OU. The cystoid macular edema had



**Figure 1.** Fluorescein angiography shows hyperfluorescence in the macula in the right fundus and no leakage of dye in the left fundus of 73-year-old woman with bilateral pseudophakia and glaucoma after treatment bilaterally with topical latanoprost.

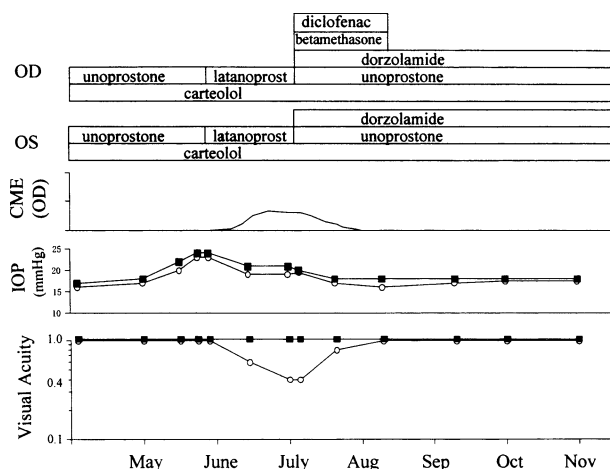
resolved in the right eye. After the resolution of cystoid macular edema, both eyes have been treated with topical carteolol, isopropyl unoprostone, and dorzolamide. Paracentral scotomas remain bilaterally, but good visual acuity (1.0) and well-controlled intraocular pressure (14–17 mm Hg) have been maintained in both eyes. The clinical course is shown in Figure 2.

## Discussion

Pupillary distortion causing vitreous traction was found in the right eye of our patient. Posterior capsule rupture can induce vitreous traction and make it possible for cytokines to move easily into the posterior vitreous. Furthermore, vitreous traction may induce irritation of the uvea, resulting in mild uveitis. Warwar et al<sup>2</sup> reported that 6 (6.4%) of 94 patients receiving latanoprost developed anterior uveitis. It is likely that latanoprost may exacerbate uveitis in eyes with vitreous herniation.

Miyake et al<sup>4</sup> emphasized that latanoprost therapy increased the incidence of angiographic cystoid macular edema formation in early postoperative pseudophakia. In our patient, latanoprost was used because 5 years had passed since the cataract surgery. It is of interest that latanoprost use induced cystoid macular edema in the late postoperative pseudophakia in the present case.

It is not clear whether or not cystoid macular edema existed before the topical instillation of latanoprost. In our patient, cystoid macular edema developed in the right pseudophakic eye, which had a history of surgical complications, 1 month after topical instillation of latanoprost, and disappeared 1 month after discontinuation of the agent. Before the cystoid macular edema disappeared, isopropyl unoprostone, betamethasone, and diclofenac had also been instilled.



**Figure 2.** Clinical course. □; right eye, ■; left eye.

It is probable that the latanoprost use might have caused cystoid macular edema. Rescula eyedrops contain isopropyl unoprostone and benzalkonium chloride. Xalatan eyedrops contain latanoprost and benzalkonium chloride. Therefore, it is unlikely that it was the benzalkonium chloride that caused the cystoid macular edema. Because cystoid macular edema did not develop in the left pseudophakic eye with no history of surgery complications, it is likely that such a history may represent a risk for the development of the edema.

To our knowledge, only a few cases of cystoid macular edema associated with isopropyl unoprostone have been reported.<sup>6</sup> Although both unoprostone and latanoprost are prostaglandin  $F_{2\alpha}$  analogs, latanoprost binds to the prostaglandin  $F_{2\alpha}$  receptor, but isopropyl unoprostone does not. It is not clear whether binding to the prostaglandin  $F_{2\alpha}$  receptor may be involved in the pathogenesis of latanoprost-associated cystoid macular edema.

## References

1. Ayyala RS, Cruz DA, Margo CE, et al. Cystoid macular edema associated with latanoprost in aphakic and pseudophakic eyes. *Am J Ophthalmol* 1998;126:602–604.
2. Warwar RE, Bullock JD, Ballal D. Cystoid macular edema and anterior uveitis associated with latanoprost use. Experience and incidence in a retrospective review of 94 patients. *Ophthalmology* 1998;105:263–268.
3. Moroi SE, Gottfredsdottir MS, Schteingart MT, et al. Cystoid macular edema associated with latanoprost therapy in a case series of patients with glaucoma and ocular hypertension. *Ophthalmology* 1999;106:1024–1029.
4. Miyake K, Ota I, Maekubo K, Ichihashi S, Miyake S. Latanoprost accelerates disruption of the blood-aqueous barrier and the incidence of angiographic cystoid macular edema in early postoperative pseudophakias. *Arch Ophthalmol* 1999;117:34–40.
5. Lima M, Paranhos A Jr, Salim S, et al. Visually significant cystoid macular edema in pseudophakic and aphakic patients with glaucoma receiving latanoprost. *J Glaucoma* 2000;9:317–321.
6. Wand M, Gaudio AR. Cystoid macular edema associated with ocular hypotensive lipoids. *Am J Ophthalmol* 2002;133:403–405.