

# Falsely Elevated Intraocular Pressure Due to an Abnormally Thick Cornea in a Patient with Nevus of Ota

Kiyotaka Kitagawa, Seiji Hayasaka and Yasunori Nagaki

*Department of Ophthalmology, Toyama Medical and Pharmaceutical University, Toyama, Japan*

**Background:** Several ocular complications, including glaucoma and ocular hypertension, have been reported in patients with nevus of Ota.

**Case:** A 12-year-old boy with nevus of Ota on the left side of his face was referred for further examination of elevated intraocular pressure in his left eye.

**Observations:** Intraocular pressure measured with Goldmann tonometry was 19 mm Hg OD and 25 mm Hg OS. No visual field defects were detected by Goldmann or Humphrey perimetry. With ultrasonic pachymetry, the mean  $\pm$  SD of central corneal thickness was  $560 \pm 4 \mu\text{m}$  in the right eye and  $652 \pm 9 \mu\text{m}$  in the left.

**Conclusion:** Ophthalmologists should be aware that the abnormally thick cornea of patients with nevus of Ota may produce falsely elevated intraocular pressure readings. **Jpn J Ophthalmol** 2003;47:142–144 © 2003 Japanese Ophthalmological Society

**Key Words:** Corneal thickness, intraocular pressure, nevus of Ota, pachymetry.

## Introduction

Nevus of Ota is a developmental disorder of the embryonic neural crest characterized by cutaneous pigmentation in the distribution of the fifth cranial nerve.<sup>1</sup> All the structures of the eye derived from the neural crest could be involved. Several ocular complications, including glaucoma and ocular hypertension, have been reported in patients with nevus of Ota.<sup>2–5</sup> Elevated intraocular pressure in patients with nevus of Ota is thought to be due to goniodysgenesis, or infiltration of melanocytic cells into the trabecular meshwork. We recently examined a patient with nevus of Ota who exhibited falsely elevated intraocular pressure, possibly due to his abnormally thick cornea.

## Case Report

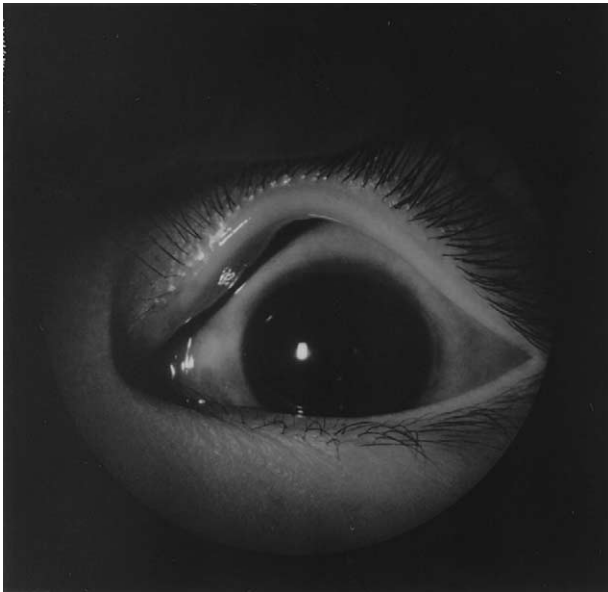A 12-year-old boy with nevus of Ota on the left side of his face was referred to our clinic for evaluation of elevated intraocular pressure on August 4,

2001. Visual fields tested with Goldmann and Humphrey perimetry several times during the previous 3 years had showed no defect in spite of the increased intraocular pressure in his left eye. He had had cutaneous bluish pigmentation involving the left side of his face in the distribution of the ophthalmic division of the fifth cranial nerve since birth. He had undergone laser therapy on the left side of his face 3 years previously to reduce this pigmentation.

In our examination, his corrected visual acuity was 1.2 OU. His intraocular pressure measured with Goldmann applanation tonometry was 19 mm Hg OD and 25 mm Hg OS. Episcleral melanosis was seen in the left eye (Figure 1). The left cornea appeared biomicroscopically thicker than the right (Figure 2). Central corneal thickness was measured by ultrasonic pachymetry (US-1800; Nidek, Tokyo) with the patient under local anesthesia. The speed of ultrasonic sound was 1640 m/s. The mean  $\pm$  SD of 10 measurements of central corneal thickness of the right eye was  $560 \pm 4 \mu\text{m}$ , and that of the left eye was  $652 \pm 9 \mu\text{m}$ . Corneal diameter was  $12 \times 11 \text{ mm}$  bilaterally, as measured with calipers. Specular microscopy showed no corneal endothelial abnormality bilaterally. The anterior chamber, lens, and vitreous

Received: April 22, 2002

Correspondence and reprint requests to: Kiyotaka KITAGAWA, MD, Department of Ophthalmology, Toyama Medical and Pharmaceutical University, 2630 Sugitani, Toyama 930-0194, Japan

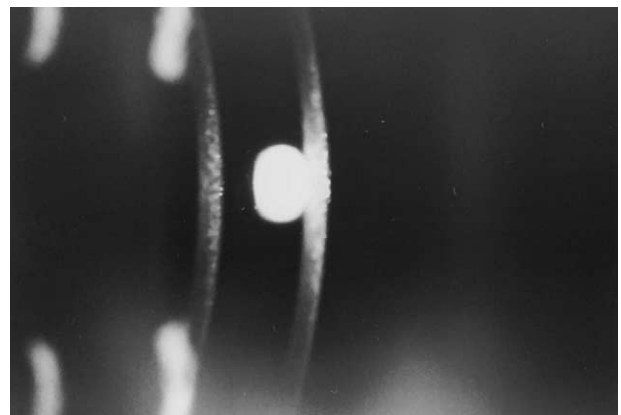



**Figure 1.** Episcleral melanosis is seen in the left eye of a 12-year-old boy with nevus of Ota.

appeared clear in both eyes. The vertical cup-to-disc ratio was 0.6 OD and 0.7 OS ophthalmoscopically. Goldmann perimetry revealed no abnormality bilaterally. Gonioscopy showed no abnormality in the right eye, but hyperpigmentation of the anterior chamber angle and undeveloped angle recess were noted in the left eye (Figure 3). Axial length was 22.15 mm OD and 21.95 mm OS, as observed by ultrasonography A mode. On December 28, 2001, the intraocular pressure was 18 mm Hg OD and 25 mm Hg OS. Goldmann and Humphrey visual field tests did not show any abnormality bilaterally. Changes in intraocular pressure levels are shown in Figure 4.

### Discussion

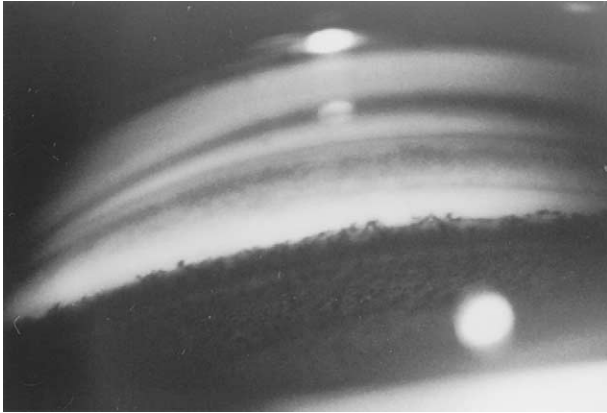
In our patient, the central corneal thickness of the left eye was  $652 \pm 9 \mu\text{m}$ . His intraocular pressure measured with Goldmann tonometry was 25 mm Hg OS. Ehlers et al<sup>6</sup> reported that the central corneal thickness influenced the reading of the intraocular pressure by Goldmann applanation tonometry. Recep et al<sup>7</sup> reported that the decrease in intraocular pressure after laser in situ keratomileusis was related to the decrease in corneal thickness. Foster et al<sup>8</sup> reported that a significant positive correlation was identified between intraocular pressure and corneal thickness in a Mongolian population. Wu et al<sup>9</sup> reported the formula of corrected intraocular pressure [corrected intraocular pressure = measured intraoc-



**Figure 2.** The left cornea (a) appears to be thicker than the right cornea (b).

ular pressure - 5/70 (measured central corneal thickness - 552)]. According to their formula, corrected intraocular pressure in our patient was 16 mm Hg OS. Doughty and Zaman<sup>10</sup> reported that a 50- $\mu\text{m}$  change in central corneal thickness corresponded to 2.5 mm Hg of intraocular pressure difference. In our patient, central corneal thickness of the left eye was approximately 100  $\mu\text{m}$  thicker than that of a normal cornea. According to the Doughty and Zaman findings, our patient's corrected intraocular pressure OS would be approximately 20 mm Hg. No visual field defect had been noted in our patient during the previous 3 years. The elevated intraocular pressure measured by Goldmann applanation tonometry may have been caused by the central corneal thickness.

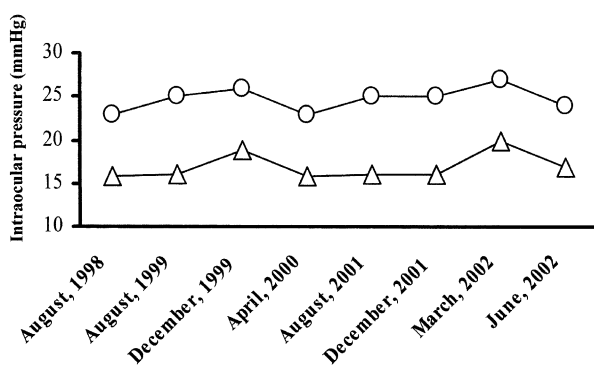
Further ophthalmic follow-up including visual field testing and determination of diurnal variation of intraocular pressure is needed. In our patient, hyperpigmentation of the anterior chamber angle in the involved eye was noted. Teekhasaenee et al<sup>5</sup> re-



**Figure 3.** Gonioscopy shows a heavily pigmented anterior chamber angle.

ported that melanocytic hyperpigmentation of the anterior chamber angle was extensive in all patients with nevus of Ota, and that there was no consistent correlation between the density of angle pigmentation and the development of elevated intraocular pressure. It is unlikely that the hyperpigmentation of the anterior chamber angle in our patient had produced the elevated intraocular pressure.

In our patient, a larger cup-to-disc ratio was present in the left eye ipsilateral to nevus of Ota. Teekhasaenee et al<sup>5</sup> also reported that of 194 patients with nevus of Ota, 20 with normal intraocular pressure showed cup-to-disc ratio asymmetry. It is unlikely that the cup-to-disc ratio asymmetry in our patient was associated with the elevated intraocular pressure.



**Figure 4.** Changes in the intraocular pressure levels. Open circle indicates intraocular pressure measured by Goldmann applanation tonometry. Open triangle indicates corrected intraocular pressure according to the formula reported by Wu et al.<sup>9</sup>

The central cornea of the left eye ipsilateral to the nevus of Ota in our patient was thicker than the cornea of the right eye. Corneal stroma, Descemet's membrane, and corneal endothelium are derived from the embryonic neural crest.<sup>11</sup> There may be a relationship between corneal thickness and nevus of Ota. Hori et al<sup>12</sup> reported that dermal melanocytes in lesions of nevus of Ota possessed an extracellular sheath composed of fine filaments that appeared to be derived from collagen. The abnormal thickness of the cornea ipsilateral to the nevus of Ota in our patient may have been due to an abnormality of corneal collagen caused by the nearby nevus.

Several patients with ocular hypertension associated with nevus of Ota have been described.<sup>5</sup> Of these, some may have exhibited falsely elevated intraocular pressure due to a thicker cornea. Ophthalmologists should be aware that an abnormally thick cornea in patients with nevus of Ota may result in falsely elevated intraocular pressure readings.

## References

- Henkind P, Friedman AH. External ocular pigmentation. *Int Ophthalmol Clin* 1971;11:87-111.
- Infante de German-Ribon R, Singh AD, Arevalo JF, Driebe W, Eskin T. Choroidal melanoma with oculodermal melanocytosis in Hispanic patients. *Am J Ophthalmol* 1999;128:251-253.
- Kono T, Kurome H, Shibuya Y, Hayasaka S. Ocular findings in Japanese women with nevus of Ota. *Graefes Arch Clin Ophthalmol* 1995;233:667-671.
- Gewirtzman GB, Ramussen JE. Nevus of Ota with ipsilateral congenital cataract. *Arch Dermatol* 1976;112:1284-1285.
- Teekhasaenee C, Ritch R, Rutnin U, Leelawongs N. Glaucoma in oculodermal melanocytosis. *Ophthalmology* 1990;97:562-570.
- Ehlers N, Bramsen T, Sperling S. Applanation tonometry and central corneal thickness. *Acta Ophthalmol* 1975;53:34-43.
- Recep OF, Cagil N, Hasiripi H. Correlation between intraocular pressure and corneal stromal thickness after laser in situ keratomileusis. *J Cataract Refract Surg* 2000;26:1480-1483.
- Foster PJ, Baasanhu J, Alsbirk PH, Munkhbayer D, Uranchimeg D, Johnson GJ. Central corneal thickness and intraocular pressure in a Mongolian population. *Ophthalmology* 1998;105:967-973.
- Wu LL, Suzuki Y, Ideta R, Araie M. Central corneal thickness of normal tension glaucoma patients in Japan. *Jpn J Ophthalmol* 2000;44:643-647.
- Doughty MJ, Zaman ML. Human corneal thickness and its impact on intraocular pressure measures: a review and meta-analysis approach. *Surv Ophthalmol* 2000;44:367-408.
- Newell FW. *Ophthalmology. Principle and concepts*. In: Newell FW, ed. *Anatomy and embryology*. 6th ed. St. Louis: CV Mosby, 1986:65-72.
- Hori Y, Ohara K, Niimura M, Kukita A. Electron microscopy. Ultrastructural observations of the extracellular sheath of dermal melanocytes in the nevus of Ota. *Am J Dermatopathol* 1982;4:245-251.