

## Morphological Study of Corneal Endothelium and Corneal Thickness in Pseudoexfoliation Syndrome

Kenji Inoue<sup>\*,†</sup>, Kazuko Okugawa<sup>\*,†</sup>, Tetsuro Oshika<sup>†</sup> and Shiro Amano<sup>†</sup>

<sup>\*</sup>Department of Ophthalmology, Nadogaya Hospital, Chiba;

<sup>†</sup>Department of Ophthalmology, University of Tokyo, School of Medicine, Tokyo, Japan

**Purpose:** To examine the endothelial morphology and the central thickness of the cornea in the eyes of patients with pseudoexfoliation syndrome (PXS).

**Methods:** The corneal endothelium was investigated in 21 patients (26 PXS eyes; 7 eyes of glaucoma patients, and 19 eyes of patients without glaucoma) and in 30 patients with senile cataract or refractive errors who served as the control group (30 non-PXS eyes). The corneal endothelial morphology and central corneal thickness (CCT) were compared between the two groups.

**Results:** The corneal endothelial cell density was significantly lower in the PXS eyes ( $2336 \pm 383$  cells/mm<sup>2</sup>) than in the non-PXS eyes ( $2632 \pm 327$  cells/mm<sup>2</sup>) ( $P = .003$ ). There was no significant difference in the coefficient of variation for the cell area and the percentage of hexagonal cells between these two groups. The central cornea was significantly thinner in the PXS eyes ( $529 \pm 31$   $\mu$ m) than in the non-PXS eyes ( $547 \pm 28$   $\mu$ m) ( $P = .03$ ). There were no significant differences in these factors between the PXS eyes in patients with and without glaucoma.

**Conclusions:** In PXS eyes, regardless of the presence of glaucoma in the patients, the corneal endothelial cell density is decreased and the central cornea is thin. **Jpn J Ophthalmol** 2003;47:235–239 © 2003 Japanese Ophthalmological Society

**Key Words:** Corneal endothelium, corneal thickness, glaucoma, pseudoexfoliation syndrome.

### Introduction

The pseudoexfoliation syndrome (PXS) consists of the formation or deposition of white, flake-like material throughout the anterior ocular segments. Pseudoexfoliative materials develop on the lens surface, iris, trabecular meshwork, zonula, and ciliary body.<sup>1,2</sup>

There are many studies of corneal endothelial changes in PXS eyes reporting lower endothelial cell density,<sup>3–9</sup> high coefficient of variation in cell area,<sup>3</sup> and a lower percentage of hexagonal cells.<sup>3,4</sup> There are, however, several studies reporting no significant changes in endothelial cell density,<sup>10</sup> the coefficient of variation in cell area,<sup>4,5</sup> or the percentage of hexagonal cells<sup>5</sup> in PXS eyes. The changes in corneal endothelial morphology in PXS eyes have been controversial.

The PXS syndrome is often found in patients with glaucoma. The central corneal thickness (CCT) of PXS eyes in glaucoma patients was reported to be thinner<sup>11</sup> than or similar<sup>12,13</sup> to normal eyes. The endothelial cell density of PXS eyes in glaucoma patients was reported lower than that of PXS eyes in patients without glaucoma<sup>6</sup> or in control eyes.<sup>7</sup>

The aim of this study is to compare the endothelial morphology and central thickness of the cornea between PXS eyes and non-PXS eyes, and PXS eyes in patients with and without glaucoma.

### Materials and Methods

We examined 21 patients with PXS (26 corneas; 11 corneas in 9 men and 15 corneas in 12 women) at the Nadogaya Hospital between August and November 2001 (the PXS group). Mean patient age was  $77.9 \pm 6.6$  years (mean  $\pm$  SD) (range, 64–90 years). Diagnosis of the syndrome was based on the typical slit-lamp appearance of

Received: May 24, 2002

Correspondence and reprint requests to: Kenji INOUE, MD, Inoue Eye Hospital, 4-3 Kanda-Surugadai, Chiyoda-ku, Tokyo 101-0062, Japan

pseudoexfoliative material at the anterior lens capsule and/or at the pupillary margin. Seven PXS patients (7 eyes) also had glaucoma. Mean patient age was  $77.9 \pm 4.7$  years (range, 70–83 years) in the PXS patients with glaucoma and  $77.9 \pm 7.3$  years (range, 64–90 years) in the PXS patients without glaucoma. Patients who had histories of previous intraocular surgery were excluded from this study.

As controls, 30 patients (14 men and 16 women; 30 corneas) were examined at the same hospital over the same time period (the control group). Mean patient age was  $77.5 \pm 5.4$  years (range, 67–90 years). Diagnosis in these control patients was senile cataract or refractive error. Data on the right eye of each patient were used in this study. These controls had no pseudoexfoliative material at the anterior lens capsule or pupillary margin, no previous intraocular surgery, and no abnormalities of the cornea. All patients in both groups gave their informed consent for participation in this study.

The endothelial morphology was quantitated by measuring parameters including cell density, coefficient of variation in the cell area, and the percentage of hexagonal cells. The central corneal endothelial cells were photographed by specular microscopy, using Noncon Robo Ca (Konan Medical, Kobe). Three central cornea microphotographs were taken and a minimum of 50 cells was counted in each photograph to calculate cell density, coefficient of variation in the cell area, and percentage of hexagonal cells. The average of the data from the three microphotographs was used to calculate the final cell density in each eye.

CCT was measured with an ultrasonic pachymeter (AL-2000; Tomey, Nagoya) under topical anesthesia. The speed of sound (1640 m/s) was used. The pachymeter tip was placed perpendicularly on the cornea and centered over the undilated pupil. An average of five consecutive readings was recorded.

The unpaired *t*-test was used to compare differences between the PXS and control groups, and between the PXS eyes in patients with and without glaucoma. We considered values of  $P < .05$  to be statistically significant.

## Results

The endothelial cell density was significantly lower in the PXS group ( $2336 \pm 383$  cells/mm<sup>2</sup>) than in the control group ( $2632 \pm 327$  cells/mm<sup>2</sup>) ( $P = .003$ ) (Figure 1). There was no significant difference between the coefficient of variation in the cell area in the PXS group ( $0.324 \pm 0.033$ ) and that in the control group ( $0.336 \pm 0.041$ ) ( $P = .21$ ). There was no significant difference between the percentage of hexagonal cells in the

PXS group ( $58.4 \pm 8.1\%$ ) and that in the control group ( $58.9 \pm 6.6\%$ ) ( $P = .80$ ). The central cornea was significantly thinner in the PXS group ( $529 \pm 31$  μm) than in the control group ( $547 \pm 28$  μm) ( $P = .03$ ).

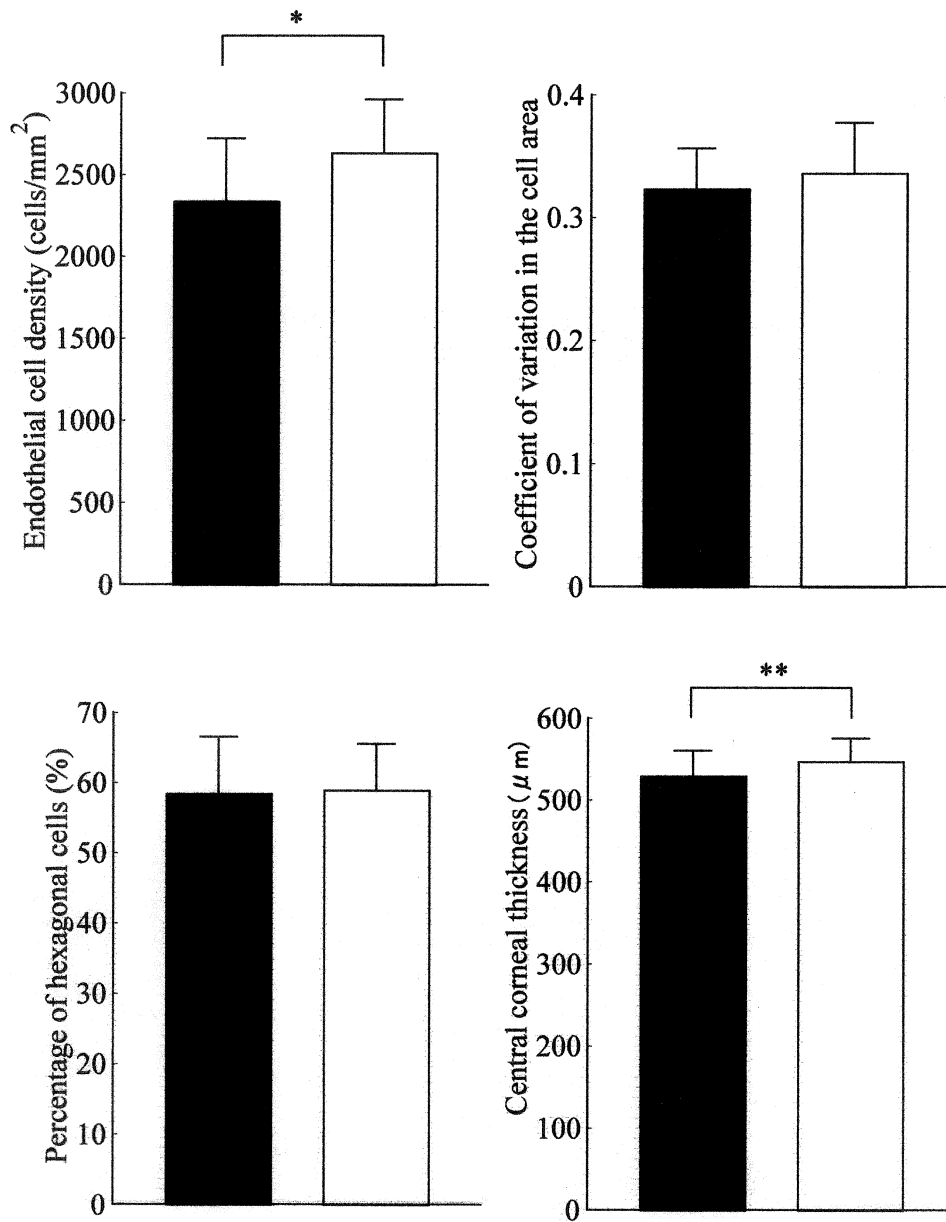
The endothelial cell density was  $2332 \pm 336$  cells/mm<sup>2</sup> in the PXS eyes in patients with glaucoma and  $2337 \pm 407$  cells/mm<sup>2</sup> in those without glaucoma ( $P = .98$ ) (Figure 2). The coefficient of variation in the cell area was  $0.341 \pm 0.038$  in the PXS eyes in patients with glaucoma and  $0.317 \pm 0.030$  in those without glaucoma ( $P = .09$ ). The percentage of hexagonal cells was  $56.8 \pm 10.2\%$  in the PXS eyes in patients with glaucoma and  $59.0 \pm 7.4\%$  in those without glaucoma ( $P = .55$ ). The CCT was  $534 \pm 37$  μm in the PXS eyes in patients with glaucoma and  $528 \pm 29$  μm in those without glaucoma ( $P = .68$ ).

## Discussion

Corneal endothelial changes in PXS eyes are induced by an altered composition and increased flare intensity of the aqueous humor caused by a breakdown of the blood-aqueous barrier.<sup>1,5</sup> By electron microscopy, large clumps of typical pseudoexfoliation material can be found adhering to the corneal endothelium, and masses of pseudoexfoliation material are incorporated into the posterior Descemet membrane.<sup>14</sup> These may lead to early corneal endothelial decompensation.<sup>1</sup>

In the current study, the composition of the corneal endothelium and its thickness in the PXS eyes were evaluated at the same time. We have found only one report<sup>10</sup> that evaluated the corneal endothelial composition and thickness in the PXS eyes at the same time. However, these authors compared these factors between the PXS and the fellow eyes and did not recruit normal eyes as controls. There are a few reports on the corneal endothelium in Japanese PXS patients, which were published in 1989 and 1990.<sup>3,4</sup> The corneal endothelium was measured using contact specular microscopy.<sup>3,4</sup> Recently, noncontact specular microscopy has often been used<sup>5,8,9</sup> and we evaluated the corneal endothelium using the noncontact method.

The mean corneal endothelial cell density per 1 mm<sup>2</sup> in PXS eyes has been reported as  $1812 \pm 297$  cells,<sup>7</sup>  $2052 \pm 264$  cells,<sup>6</sup> and  $2234 \pm 270$  cells<sup>4</sup> (the 7th decade);  $2387 \pm 266$  cells,<sup>8</sup>  $2387 \pm 319$  cells,<sup>5</sup>  $2446 \pm 344$  cells<sup>4</sup> (the 6th decade);  $2394 \pm 271$  cells,<sup>9</sup>  $2669 \pm 502$  cells,<sup>3</sup> and  $2779 \pm 540$  cells.<sup>10</sup> In the current study, the mean corneal endothelial cell density per 1 mm<sup>2</sup> was  $2336 \pm 383$  cells, which was similar to these previous reports.<sup>3–10</sup> The mean coefficient of variation in the cell area in PXS eyes has been reported as

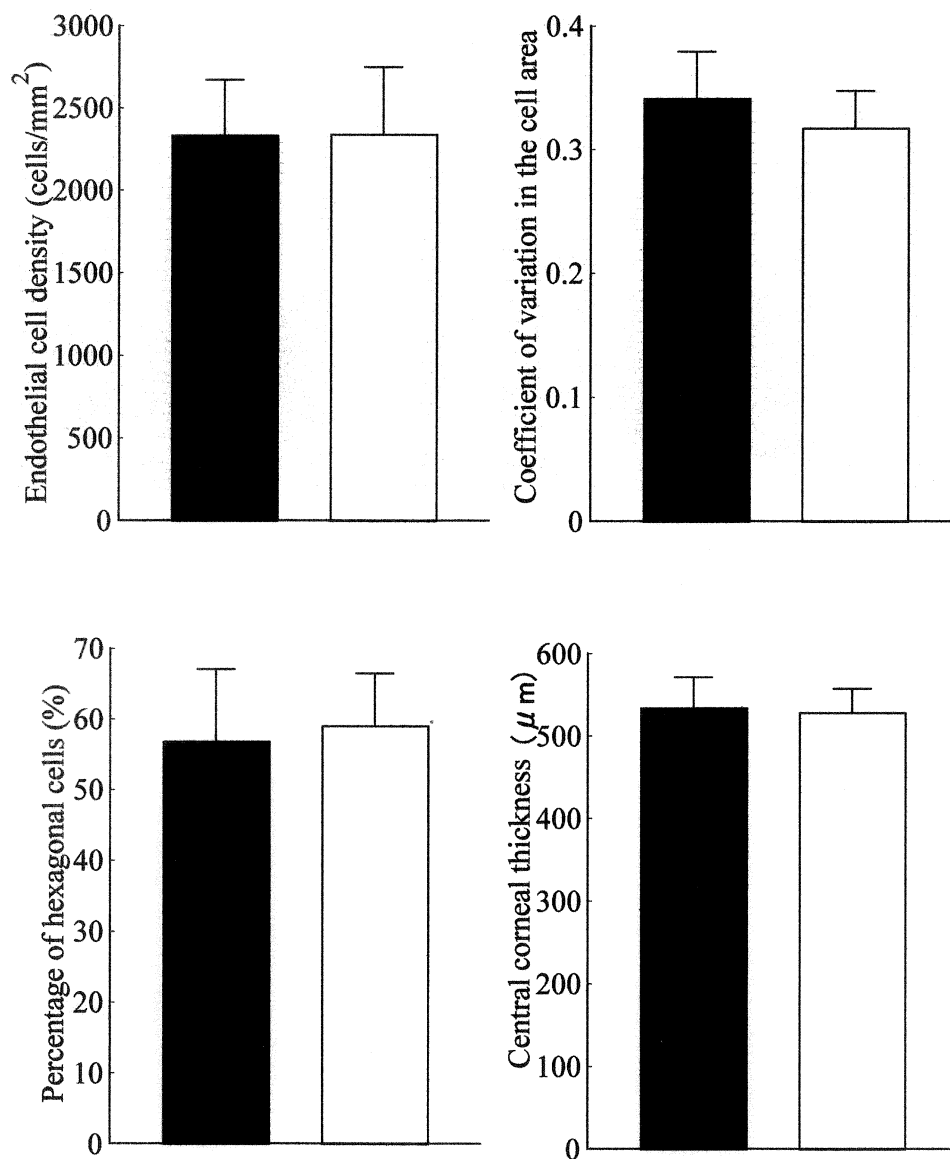


**Figure 1.** Corneal endothelial cell density, coefficient of variation in the cell area, percentage of hexagonal cells, and central corneal thickness in the pseudoexfoliation syndrome group (■) and the control group (□). (Unpaired *t*-test; \**P* < .005, \*\**P* < .05).

$0.282 \pm 0.037$  (the 6th decade),<sup>4</sup>  $0.323 \pm 0.066$  (the 7th decade),<sup>4</sup>  $0.33 \pm 0.04$ ,<sup>5</sup> and  $0.339 \pm 0.073$ .<sup>3</sup> The mean percentage of hexagonal cells in PXS eyes was reported as  $54.9 \pm 10.9\%$  (the 7th decade),<sup>4</sup>  $56.4 \pm 7.5\%$  (the 6th decade),<sup>4</sup>  $57.1 \pm 7.1\%$ ,<sup>3</sup> and  $59.5 \pm 6.7\%$ .<sup>5</sup> In the current study, the mean coefficient of variation in cell area ( $0.324 \pm 0.033$ ) and the mean percentage of hexagonal cells ( $58.4 \pm 8.1\%$ ) were similar to these previous reports.<sup>3-5</sup>

In the current study, in PXS eyes the corneal endothelial cell density was significantly lower, but the coefficient

of variation in the cell area and the percentage of hexagonal cells were similar to those in control eyes, which agreed with the Wang report<sup>5</sup> but did not agree with the Miyake et al<sup>3</sup> and Hattori<sup>4</sup> reports. The differences were influenced by the factors in our control patients. Patients who had no ocular disease<sup>4,5</sup> or who had no ocular or systemic diseases other than senile cataract<sup>3</sup> had been recruited as controls. As the data on corneal endothelial cell density ( $3101 \pm 304$  cells/mm<sup>2</sup>), the coefficient of variation in the cell area ( $0.289 \pm 0.044$ ), and the percentage of hexagonal cells ( $64.7 \pm 6.5\%$ ) in control eyes<sup>3</sup>



**Figure 2.** Corneal endothelial cell density, coefficient of variation in the cell area, percentage of hexagonal cells, and central corneal thickness in the pseudoexfoliation syndrome (PXS) eyes of patients with glaucoma (■) and in the PXS eyes of patients without glaucoma (□).

were better than expected for patients in the age group who had cataract, the differences between the PXS and control eyes were significant. We designated patients who had senile cataract or refractive error as controls. As the corneal endothelium in some control eyes might worsen due to cataract, the differences in the coefficient of variation in the cell area and the percentage of hexagonal cells between PXS and control eyes were not significant. The pseudoexfoliative materials gradually affect the corneal endothelium and more than three parameters must deteriorate as the result. Wang et al,<sup>5</sup> however, reported that

their findings (decrease in the endothelial cell density, similar to the coefficient of variation in the cell area, and the percentage of hexagonal cells) might be explained by the fact that mild intraocular disturbances developed slowly over a long period and resulted in a decrease in corneal endothelial cells and their enlargement without transformation of their hexagonal shape.

The presence of PXS increases the incidence of intraoperative and postoperative complications during cataract surgery. Insufficient mydriasis and weak zonula can complicate the intraoperative course. Many previous reports<sup>3-9</sup>

and the current study showed that corneal endothelial cell density in PXS eyes was decreased. Caution and careful techniques are required during cataract surgery in PXS eyes.

The mean CCT in PXS eyes in patients with glaucoma has been reported as  $493 \pm 33 \mu\text{m}$ ,<sup>11</sup>  $507 \pm 25 \mu\text{m}$ ,<sup>13</sup>  $528 \pm 30 \mu\text{m}$ ,<sup>10</sup> and  $530.7 \mu\text{m}$ .<sup>12</sup> In the current study, the mean CCT in the PXS eyes in patients with glaucoma was  $534 \pm 37 \mu\text{m}$ , which was slightly larger than those of previous reports.<sup>10–13</sup> The PXS eyes often involve elevated intraocular pressure due to particulate pigment deposition on the trabecular meshwork, resulting in glaucoma. CCT affects intraocular pressure readings. Wolfs et al<sup>15</sup> reported that average corrections per  $10 \mu\text{m}$  deviation in corneal thickness were  $0.19 \text{ mm Hg}$ . In the current study, the CCT in the PXS eyes was significantly smaller than that in the control. We should evaluate intraocular pressure in PXS eyes in consideration of CCT and carefully observe patients with glaucoma associated with PXS.

Hattori<sup>4</sup> reported that there were no significant differences in endothelial cell density, coefficient of variation in the cell area, and percentage of hexagonal cells between the PXS eyes in patients with normal intraocular pressure and those with high intraocular pressure. Seitz et al<sup>6</sup> reported that endothelial cell density of PXS eyes in patients with glaucoma ( $2014 \pm 254 \text{ cells/mm}^2$ ) was significantly lower than that of PXS eyes in patients without glaucoma ( $2214 \pm 251 \text{ cells/mm}^2$ ). Knorr et al<sup>7</sup> reported that endothelial cell density of PXS eyes in patients with glaucoma ( $1482 \pm 267 \text{ cells/mm}^2$ ) was significantly lower than that of control eyes ( $2302 \pm 394 \text{ cells/mm}^2$ ). In the current study, there were no significant differences in endothelial cell density between the PXS eyes in patients with and without glaucoma due to the high values of endothelial cell density in the PXS eyes in patients with glaucoma ( $2332 \pm 336 \text{ cells/mm}^2$ ).

In conclusion, the corneal endothelial cell density is decreased and the central cornea is thin in PXS eyes regardless of the presence of glaucoma. Therefore, we ophthalmologists must be careful in conducting cataract surgery and in evaluating intraocular pressure in eyes of patients with PXS.

## References

1. Naumann GOH, Schlötzer-Schrehardt U, Kütchle M. Pseudoexfoliation syndrome for the comprehensive ophthalmologist. Intraocular and systemic manifestations. *Ophthalmology* 1998;105:951–968.
2. Prince AM, Ritch R. Clinical signs of the pseudoexfoliation syndrome. *Ophthalmology* 1986;93:803–807.
3. Miyake K, Matsuda M, Inaba M. Corneal endothelial changes in pseudoexfoliation syndrome. *Am J Ophthalmol* 1989;108:49–52.
4. Hattori Y. Corneal endothelial examination of pseudoexfoliation syndrome. *Nippon Ganka Gakkai Zasshi (Acta Soc Ophthalmol Jpn)* 1990;94:957–963.
5. Wang L, Yamashita R, Hommura S. Corneal endothelial changes and aqueous flare intensity in pseudoexfoliation syndrome. *Ophthalmologica* 1999;213:387–391.
6. Seitz B, Müller EE, Langenbacher A, Kus MM, Naumann GO. Endothelial keratopathy in pseudoexfoliation syndrome: quantitative and qualitative morphometry using automated video image analysis. *Klin Monatsbl Augenheilkd* 1995;207:167–175.
7. Knorr HL, Jünemann A, Händel A, Naumann GOH. Morphometric and qualitative changes in corneal endothelium in pseudoexfoliation syndrome. *Fortschr Ophthalmol* 1991;88:786–789.
8. Wirbelauer C, Anders N, Pham DT, Wollensak J. Corneal endothelial cell changes in pseudoexfoliation syndrome after cataract surgery. *Arch Ophthalmol* 1998;116:145–149.
9. Wirbelauer C, Anders N, Pham DT, Holschbach A, Wollensak J. Early postoperative endothelial cell loss after corneoscleral tunnel incision and phacoemulsification in pseudoexfoliation syndrome. *Der Ophthalmologe* 1997;94:332–336.
10. Puska P, Vasara K, Harju M, Setälä K. Corneal thickness and corneal endothelium in normotensive subjects with unilateral exfoliation syndrome. *Graefes Arch Clin Exp Ophthalmol* 2000;238:659–663.
11. Bechmann M, Thiel MJ, Roesen B, Ullrich S, Ulbig MW, Ludwig K. Central corneal thickness determined with optical coherence tomography in various types of glaucoma. *Br J Ophthalmol* 2000;84:1233–1237.
12. Shah S, Chatterjee A, Mathai M, et al. Relationship between corneal thickness and measured intraocular pressure in a general ophthalmology clinic. *Ophthalmology* 1999;106:2154–2160.
13. Ventura ACS, Böhnke M, Mojon DS. Central corneal thickness measurements in patients with normal tension glaucoma, primary open angle glaucoma, pseudoexfoliation glaucoma, or ocular hypertension. *Br J Ophthalmol* 2001;85:792–795.
14. Schlötzer-Schrehardt UM, Dörfler S, Naumann GOH. Corneal endothelial involvement in pseudoexfoliation syndrome. *Arch Ophthalmol* 1993;111:666–674.
15. Wolfs RCW, Klaver CCW, Vingerling JR, Grobbee DE, Hofman A, de Jong PTVM. Distribution of central corneal thickness and its association with intraocular pressure: The Rotterdam Study. *Am J Ophthalmol* 1997;123:767–772.