

# A Muscle Transposition Procedure for Abducens Palsy, in Which the Halves of the Vertical Rectus Muscle Bellies Are Sutured Onto the Sclera

Yasuhiro Nishida, Akihiro Inatomi, Yoshiko Aoki,  
Osamu Hayashi, Tatsuya Iwami, Sanae Oda, Jiro Nakamura and Kazutaka Kani

*Department of Ophthalmology, Shiga University of Medical Science, Seta, Tsukinowa, Otsu, Japan*

**Purpose:** To review the results of a muscle transposition procedure in which the halves of the vertical rectus muscle bellies are sutured onto the sclera, without tenotomy of vertical recti as in Hummelsheim's procedure or surgical treatment of the lateral rectus (LR) as in Jensen's procedure.

**Methods:** Ten patients with abducens palsy received the procedure. We measured the ocular deviation and the field of single binocular vision, and observed the LR using magnetic resonance imaging (MRI).

**Results:** Preoperative or postoperative deviation was distributed from +27 to +58 prism diopters (PD) or orthophoria to +12 PD, respectively, in 7 patients with unilateral paresis, and +75 to +120 PD or +2 to +37 PD in 3 patients with bilateral paresis. The average correction was 42.4 PD per eye. Seven patients were able to regain the field of single binocular vision at least in the primary position. No postoperative complications were observed. MRI showed that the LR was atrophic and floppy, lacking muscle tension.

**Conclusions:** Our procedure enabled the patients to obtain satisfactory postoperative results without treatment of the LR or tenotomy of the transposed muscles. This procedure can reduce operative damage to the eye more than Hummelsheim's or Jensen's procedure. **Jpn J Ophthalmol 2003;47:281-286** © 2003 Japanese Ophthalmological Society

**Key Words:** Abducens palsy, anterior segment ischemia, Hummelsheim's procedure, Jensen's procedure, muscle transposition.

## Introduction

For large angle esotropia due to complete abducens palsy, various muscle transposition procedures have been developed.<sup>1-3</sup> Among these procedures, Hummelsheim's<sup>4</sup> and Jensen's procedures<sup>5</sup> are especially popular. In Jensen's procedure, the superior, inferior, and lateral recti (SR, IR, and LR) are longitudinally split. The lateral half of the SR or IR is respectively joined to the superior or inferior half of the LR. Unlike Hummelsheim's procedure, Jensen's does not require tenotomy in the transposed muscles, but does require muscle union. Therefore, Jensen's procedure is generally regarded as causing less

damage to the operative eye than Hummelsheim's because the anterior ciliary artery in the transposed muscles can be preserved. However, in Jensen's procedure it is necessary to split not only both SR and IR, but also the paretic LR into two halves and join them together. We had some doubts about whether splitting and transposing the paretic LR, as in Jensen's procedure, was necessary for correcting eye position because transposition of the paretic LR halves reduces abduction force. Moreover, medial rectus (MR) recession is often combined with Jensen's procedure in cases of complete abducens palsy. When they are combined, there is no intact rectus muscle in the operative eye whereas the LR remains intact in Hummelsheim's procedure.

For these reasons, we introduced a muscle transposition procedure for complete abducens palsy in which only the vertical muscle halves are fixed with anchoring sutures

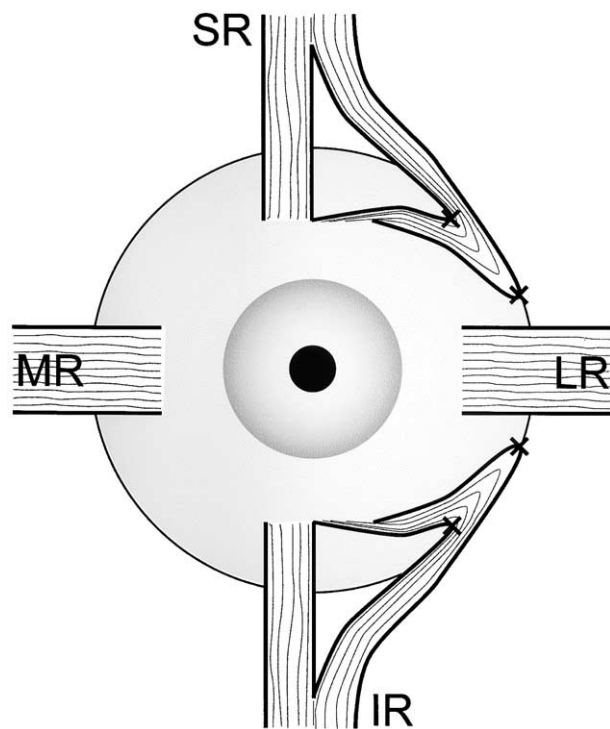
Received: August 26, 2002

Correspondence and reprint requests to: Yasuhiro NISHIDA, MD, PhD, Department of Ophthalmology, Shiga University of Medical Science, Seta, Tsukinowa, Otsu 520-2192, Japan

onto the sclera, instead of vertical muscle tenotomy as in Hummelsheim's procedure or LR splitting and transposition as in Jensen's procedure. In the present paper, we review the results of our procedure.

## Materials and Methods

Since 1984, we have performed the muscle transposition procedure for abducens palsy, as shown in Figure 1. Ten patients with complete abducens palsy were operated on using this procedure in our hospital. Before surgery, we obtained informed consent concerning the operative procedure from all patients. We reviewed the sex of each patient, cause of palsy, laterality of the paretic eye, age at surgery, duration from onset to surgery, laterality of the operative eye in muscle transposition and in the combined MR recession, and the follow-up period after the surgery. To evaluate the postoperative results, we measured the angle of squint in the primary eye position at distance and the area of single binocular vision before surgery, 1 month after surgery, and at the final examination. The angle of squint in the paretic eye was measured by using a prism cover test or Krimsky prism test. The



**Figure 1.** The muscle transposition procedure by Inatomi and Nishida. The operative eye in the figure is a left eye. MR: medial rectus, LR: lateral rectus, SR: superior rectus, IR: inferior rectus.

field of single binocular vision was measured on a Hess screen chart within 30° from the center at a distance of 1 meter under binocular vision. A head strap was used to prevent head rotation during the examination. Moreover, an orbital T1-weighted magnetic resonance imaging (MRI) examination was performed on 6 patients after surgery in order to observe the paretic LR.

For muscle transposition in the left eye, a radial conjunctival incision was made at halfway between 1 and 2 o'clock, and halfway between 4 and 5 o'clock. Peritomy was performed from the upper radial incision site to 12 o'clock and from the lower radial incision site to 6 o'clock. Then the vertical recti and the scleral surfaces were explored. Intermuscular septum and fascia along the lateral margin of the vertical recti were carefully dissected away. Each vertical muscle belly was longitudinally split from the center of the muscle insertion for about 15 mm with a short muscle hook. At the lateral margin of each vertical rectus 8 to 10 mm posterior to the insertion, two 6-0 nylon monofilaments were inserted, being careful not to strangulate the artery in the muscle. They were also inserted at the sclera beside the superior or inferior margin of the LR, 8 mm posterior to the LR insertion. Then the lateral halves of the vertical rectus muscle bellies were transposed to the scleral point beside the superior or inferior margin of the LR and were sutured onto the sclera so that the transposed muscle bellies could be fixed. One scleral suture was added on the inside edge of each muscle transposed to the sclera. The LR received no surgical treatment. In some patients, the recession of the MR was combined with the transposition procedure.

## Results

Profiles of the 10 patients are shown in Table 1. The patients consisted of 5 men and 5 women. The cause of abducens palsy was trauma in 8 patients, a brain tumor in 1, and was unknown in the other. Seven patients had abducens palsy in the unilateral eye (5 patients in the right eye, 2 patients in the left) and 3 patients in both eyes. Their ages at surgery ranged from 8 to 72 years (mean  $\pm$  SD, 36.8  $\pm$  21.9 years). The duration from onset to surgery ranged from 11 to 171 months (mean  $\pm$  SD, 63.5  $\pm$  65.8 months). Muscle transposition was performed in the unilateral eye of 8 patients and in both eyes of 2 patients. MR recession from 5 to 7 mm was combined with muscle transposition in 4 patients (recession in the right eye in 2 patients, recession in both eyes in 2).

Because abduction in the paretic eye was very poor in all patients, the eye could not move beyond the midline, and the eye position was obviously esotropic. Table 2

**Table 1.** Profiles of 10 Patients with abducens Palsy

Patient No.	Sex	Cause	Laterality	Age at Surgery (y)	Duration: Onset to Surgery (mo)	Mus Tr	MR Rec (mm)	LR Atrophy in MRI
1	M	Tumor	R	17	11	R	R, 5	NP
2	F	Trauma	B	48	24	B	B, 5	Yes
3	F	Trauma	R	20	141	R	NP	NP
4	M	Trauma	B	20	24	B	NP	NP
5	F	Trauma	R	22	18	R	NP	Yes
6	M	Trauma	L	47	25	L	NP	Yes
7	F	Trauma	R	61	162	R	NP	No
8	M	Trauma	L	8	30	L	NP	Yes
9	M	MS	B	72	171	L	B, 5	Yes
10	F	Trauma	R	53	29	R	R, 7	NP

y: years, mo: months, Mus Tr: muscle transposition, MR Rec: medial rectus recession, LR: lateral rectus, MRI: magnetic resonance image, MS: multiple sclerosis, R: right, L: left, B: bilateral, NP: not performed.

shows the preoperative and postoperative angle of squint in the primary position at distance. The preoperative deviation was distributed from +27 to +58 prism diopters (PD) in the 7 patients with unilateral paresis, and from +75 to +120 PD in the 3 patients with bilateral paresis. The postoperative deviation 1 month after surgery was distributed from orthophoria to +12 PD in unilateral paresis, and from +5 to +36 PD in bilateral paresis. The duration of follow-up after surgery ranged from 4 to 187 months (mean  $\pm$  SD, 58.3  $\pm$  69.8 months). At the final examination, the postoperative deviation was distributed from orthophoria to +14 PD in unilateral paresis, and from +2 to +37 PD in bilateral paresis. It is possible that the postoperative eye position was very stable as shown by the maximal angle change to esodeviation; it was only 3 PD (in patient 2) from 1 month after the surgery to the final examination, although the follow-up duration in patients 1, 4, and 9 was less than 12 months. The average correction after our procedure was 42.4  $\pm$  10.9 PD per

eye, when the total correction in patients who had both eyes operated on was divided in half.

In 9 patients, excluding Patient 5, who had no binocular function due to visual suppression, there was no field of single binocular vision before surgery. Seven (ie, patients 1, 3, 4, 6, 7, 8, and 10) of the 9 patients partially regained the field of single binocular vision at least in the primary position after surgery. Figure 2 shows the range of single binocular vision after surgery in these patients.

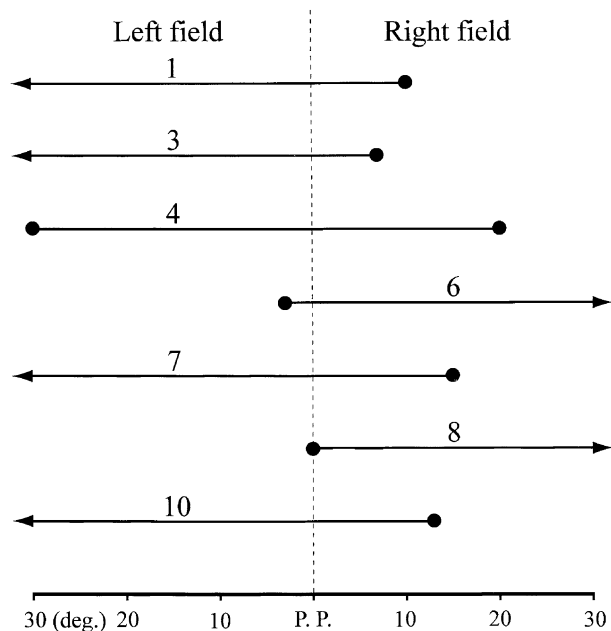
Patient 2, who had bilateral abducens palsy, could not regain the field of single binocular vision after the surgery in both eyes, due to an ocular deviation in horizontal version. However, she was satisfied with surgical correction from +120 to +12 PD, and her abnormal head posture greatly improved. In Patient 6, ocular deviation of +12 PD remained 1 month after surgery. He had no wish for further medial rectus recession, in spite of our recommendation. In Patient 9 with bilateral abducens palsy, ocular deviation of +36 PD remained 1 month

**Table 2.** Preoperative and Postoperative Angle of Deviation and Follow-up Duration After Surgery

Patient No.	Preoperative Deviation (PD)	Postoperative Deviation (PD)		Follow-up Duration (mo)
		After 1 month	At Final Examination	
1	+27	Orthophoria	Orthophoria	9
2*	+120	+9	+12	187
3	+35	+3	Orthophoria	20
4*	+75	+5	+2	6
5	+47	Orthophoria	Orthophoria	164
6	+58	+12	+14	48
7	+30	Orthophoria	Orthophoria	112
8	+40	+2	+3	13
9*	+94	+36	+37	4
10	+56	Orthophoria	Orthophoria	20

PD: prism diopters, mo: months.

\*Patients with bilateral abducens palsy.



**Figure 2.** The range of single binocular vision in the horizontal axis in 7 patients who partially regained the field of single binocular vision. The arrowheads mean that the area extends beyond 30° on either side. The seven numerals from 1 to 10 are the patient numbers. P.P.: primary position.

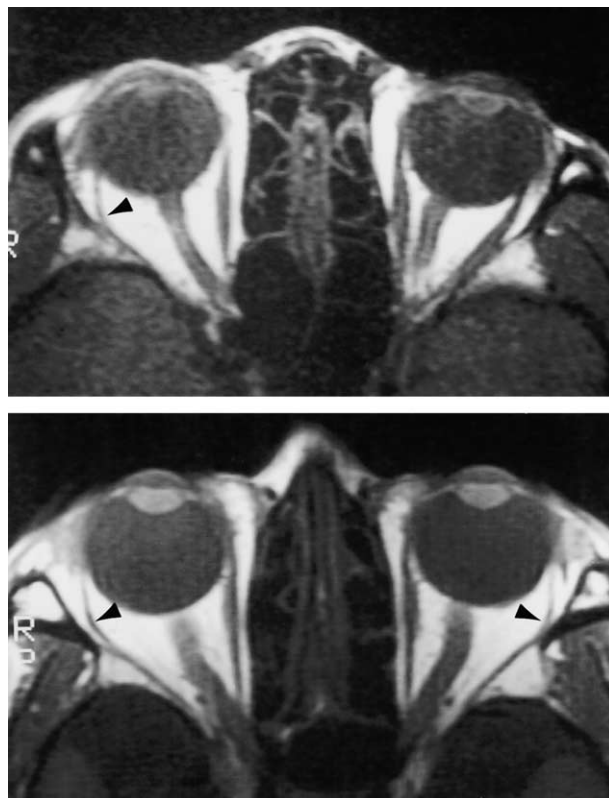after surgery in 1 eye, and the field of single binocular vision could not be regained because further muscle transposition in the other eye was impossible due to his poor general condition. These last 2 patients (patients 6 and 9) might have had better postoperative results if further operations could have been performed. Excluding patients 6 and 9, the average final deviation in the 8 patients was +2.1 PD. The final deviation in 7 of the 8 patients was less than +5 PD.

Figure 3 shows the representative orbital pictures in T1-weighted MRI after the surgery. The muscle belly of the paretic LR was very thin. It shows the obvious muscle atrophy that was observed in 5 of 6 patients who could be given an MRI examination, as in Table 1. Moreover, the belly of the paretic LR was laterally slack, instead of being tight. These MRI findings showed that the LR was floppy with little muscle tension at the primary eye position.

Anterior segment ischemia or other ocular complications after surgery were not observed in any patients. Furthermore, neither significant vertical deviation nor disturbance of vertical duction was shown.

### Discussion

By suturing the margin of the lateral halves of the vertical rectus muscle bellies onto the sclera, our procedure enabled us to horizontally transpose the vertical



**Figure 3.** (Top) The representative orbital magnetic resonance imaging (MRI) image for Patient 5 with right abducens palsy and (bottom) for Patient 2 with bilateral abducens palsy. The arrowheads show that the paretic lateral rectus is obviously atrophic and laterally slack. Note that the right eye is on the left side in these MRI images.

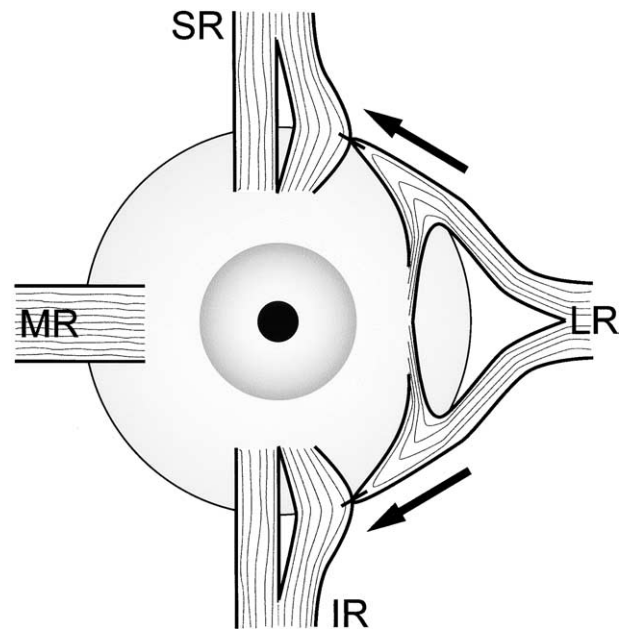
muscle bellies without tenotomy as in Hummelsheim's procedure, or without muscle union as in Jensen's procedure in which not only the vertical recti, but also the LR must be split. Thus we think that lateral rectus splitting as in Jensen's procedure is unnecessary for the following reasons.

The first concerns anterior segment ischemia. The anterior ciliary artery running through each rectus muscle plays a crucial role in the circulation of the anterior ocular segment.<sup>6</sup> There were many previous reports<sup>7-12</sup> concerning anterior segment ischemia due to anterior ciliary arterial insufficiency after strabismus surgery. This complication is closely related to the number of tenotomy procedures in the rectus muscles. It is generally regarded that anterior segment ischemia more often occurs when full thickness vertical muscle transposition is combined with horizontal rectus recession.<sup>8,10,11</sup> The fluorescein iris angiography studies in humans<sup>13</sup> and monkeys<sup>14</sup> show that the anterior ciliary arteries in the vertical recti play

a more crucial role in the blood supply to the anterior ocular segment than those in the horizontal recti. Therefore, vertical rectus transposition should be performed carefully. Compared to other procedures, Jensen's procedure is generally regarded as a safer one with less possibility of anterior segment ischemia because it does not require tenotomy of any recti.<sup>1</sup> Helveston<sup>2</sup> recommended Jensen's procedure for patients who require a combined MR recession. However, anterior segment ischemia cannot be completely avoided even in Jensen's procedure. There are some reports<sup>7,10,12</sup> that anterior segment ischemia occurred after Jensen's procedure. Moreover, one report showed that Jensen's procedure caused ischemia even in a healthy child.<sup>12</sup> A fluorescein iris angiography<sup>13</sup> study also showed that delayed filling occurred even after Jensen's procedure. Therefore, it is possible that even if only splitting and union of vertical recti and LR without tenotomy is performed, as in Jensen's procedure, vascular damage does occur. Moreover, Von Noorden<sup>7</sup> suggested that a circulatory disturbance may occur due to strangulation of the transposed bellies in Jensen's muscle union.

The second reason why lateral rectus splitting is unnecessary is concerned with the problem of the kinetics in Jensen's procedure. In the procedure, the LR belly must be divided into superior and inferior halves. Then, they are transposed at the temporo-superior and temporo-inferior halfway points, respectively. However, the original horizontal tension of the LR decreases while the vertical tension secondarily increases. This kinetic transformation in the LR is not suitable for the operative purposes. Furthermore, the MRI findings in our 5 patients suggested that the paretic LR was atrophic and floppy with little muscular tension. Even if some tension might remain in the paretic LR, there must be a substantial difference between the paretic LR tension and healthy vertical muscle tension. We doubt whether the healthy vertical rectus bellies can be retained at the halfway point by only joining the muscles together. Theoretically, the healthy transposed vertical rectus muscles may return to their original position, due to substantial differences between the healthy and paretic muscles. Consequently, the operative effect may be decreased, as shown in Figure 4. A previous report<sup>15</sup> also showed that the surgical effect in Jensen's procedures was reduced in two cases, although the cause was not mentioned.

Therefore, we concluded that splitting and transposing the paretic LR was not beneficial for the safety and effect of the surgery, and that only healthy vertical muscle bellies should be transposed by suturing them onto the sclera without any surgical treatment to the paretic LR. It is possible that our procedure causes less operative damage to the eye than Jensen's or Hummelsheim's procedure, and that the transposed muscle bellies in our procedure are



**Figure 4.** The possibility of transposed vertical recti returning to their original positions in a left eye after Jensen's procedure, as shown by arrows. MR: medial rectus, LR: lateral rectus, SR: superior rectus, IR: inferior rectus.

more stably fixed than in Jensen's procedure. However, we have performed our procedure in only 10 cases and did not perform a comparative study with Jensen's or Hummelsheim's procedure. Moreover, our procedure is easier and safer for further surgical correction in patients on whom a recession-resection procedure in the horizontal recti has already been performed, because our procedure requires neither surgical treatment to the horizontal recti nor tenotomy of the vertical recti. On the other hand, when botulinum toxic injection<sup>16-19</sup> to the MR is combined with our procedure, the surgery will be safer because the MR can remain surgically intact.

In our procedure, the average correction of esotropia was 42.4 PD per eye, while we were unable to separately evaluate the results with or without medial rectus recession due to the small number of patients. In Jensen's procedure, the average correction per eye was 31 PD reported by Frueh,<sup>20</sup> 38 PD by Selezinka,<sup>21</sup> 50 PD by Scott,<sup>22</sup> 51 PD by Cline,<sup>15</sup> or 41 PD by Maruo.<sup>23</sup> In Hummelsheim's procedure, it was 52 PD reported by Brooks,<sup>24</sup> or 41 PD by Neugebauer.<sup>25</sup> Therefore, our results concerning surgical correction of the eye position were similar to these previous results. In the 8 patients in whom the intended operation could be performed, the postoperative eye deviation was less than +5 PD in 7 eyes, and +12 PD in one. Seven of 9 patients who had binocular function could regain the field of single binocular vision

at least in the primary position, while 2 patients were unable to regain it because of poor abduction or the impossibility of further surgery. These results were in no way inferior to those in previous studies.<sup>15,21,22,25</sup>

In conclusion, this procedure without treatment of the LR or tenotomy of the transposed muscles can reduce operative damage to the eye more than Hummelsheim's or Jensen's procedure, and can enable patients to obtain postoperative results similar to those in previous reports.

## References

1. Helveston EM. Muscle transposition procedures. *Surv Ophthalmol* 1971;16:92–97.
2. Helveston EM. Extraocular muscle transfer. *Trans Am Acad Ophthalmol Otolaryngol* 1975;79:722–726.
3. Simons BD. Surgical management of ocular motor cranial nerve palsies. *Semin Ophthalmol* 1999;14:81–94.
4. Hummelsheim E. Weitere Erfahrungen mit partieller Sehnenüberpflanzung an den Augenmuskeln. *Arch Augenheilkd* 1908;62:71–74.
5. Jensen CDF. Rectus muscle union: a new operation for paralysis of the rectus muscles. *Trans Pac Coast Otoophthalmol Soc* 1964;45:359–387.
6. Wilcox LM, Keough EM, Connolly RJ, Hotte CE. The contribution of blood flow by the anterior ciliary arteries to the anterior segment in the primate eye. *Exp Eye Res* 1980;30:167–174.
7. Von Noorden GK. Anterior segment ischemia following the Jensen procedure. *Arch Ophthalmol* 1976;94:845–847.
8. Saunders RA, Sandall GS. Anterior segment ischemia syndrome following rectus muscle transposition. *Am J Ophthalmol* 1982;93:34–38.
9. Simon JW, Price EC, Krohel GB, Poulin RW, Reinecke RD. Anterior segment ischemia following strabismus surgery. *J Pediatr Ophthalmol Strabismus* 1984;21:179–184.
10. France TD, Simon JW. Anterior segment ischemia syndrome following muscle surgery: the AAPO&S experience. *J Pediatr Ophthalmol Strabismus* 1986;23:87–91.
11. Saunders RA, Phillips MS. Anterior segment ischemia after three rectus muscle surgery. *Ophthalmology* 1988;95:533–537.
12. Bleik JH, Cherfan GM. Anterior segment ischemia after the Jensen procedure in a 10-year-old patient. *Am J Ophthalmol* 1995;119:524–525.
13. Hayreh SS, Scott WE. Fluorescein iris angiography. II. disturbances in iris circulation following strabismus operation on the various recti. *Arch Ophthalmol* 1978;96:1390–1400.
14. Viridi PS, Hayreh SS. Anterior segment ischemia after recession of various recti. *Ophthalmology* 1987;94:1258–1271.
15. Cline RA, Scott WE. Long-term follow-up of Jensen procedures. *J Pediatr Ophthalmol Strabismus* 1988;25:264–269.
16. Fitzsimons R, Lee JP, Elston J. Treatment of sixth nerve palsy in adults with combined botulinum toxin chemodeneration and surgery. *Ophthalmology* 1988;95:1535–1542.
17. Rosenbaum AL, Kushner BJ, Kirschen D. Vertical rectus muscle transposition and botulinum toxin (Oculinum) to medial rectus for abducens palsy. *Arch Ophthalmol* 1989;107:820–823.
18. McManaway JW III, Buckley EG, Brodsky MC. Vertical rectus muscle transposition with intraoperative botulinum injection for treatment of chronic sixth nerve palsy. *Graefes Arch Clin Exp Ophthalmol* 1990;228:401–406.
19. Flanders M, Qahtani F, Gans M, Beneish R. Vertical rectus muscle transposition and botulinum toxin for complete sixth nerve palsy. *Can J Ophthalmol* 2001;36:18–25.
20. Frueh BR, Henderson JW, Arbor A. Rectus muscle union in sixth nerve paralysis. *Arch Ophthalmol* 1971;85:191–196.
21. Selezinka W, Sandall GS, Henderson JW. Rectus muscle union in sixth nerve paralysis. *Arch Ophthalmol* 1974;92:382–386.
22. Scott WE, Werner DB, Lennarson L. Evaluation of Jensen procedures by saccades and diplopic fields. *Arch Ophthalmol* 1979;97:1886–1889.
23. Maruo T, Iwashige H, Kubota N, et al. Results of surgery for paralytic esotropia due to abducens palsy. *Jpn J Ophthalmol* 1996;40:229–234.
24. Brooks SE, Olitsky SE, deB Ribeiro G. Augmented Hummelsheim procedure for paralytic strabismus. *J Pediatr Ophthalmol Strabismus* 2000;37:189–195.
25. Neugebauer A, Fricke J, Kirsch A, Rüssmann W. Modified transposition procedure of the vertical recti in sixth nerve palsy. *Am J Ophthalmol* 2001;131:359–363.