

# Chediak-Higashi Syndrome with Progressive Visual Loss

Kaori Sayanagi\*, Takashi Fujikado\*<sup>†</sup>, Takashi Onodera<sup>‡</sup> and Yasuo Tano\*

Departments of \*Ophthalmology; <sup>†</sup>Visual Science, Osaka University Graduate School of Medicine;

<sup>‡</sup>Department of Pediatrics, Suita Municipal Hospital, Osaka, Japan

---

**Background:** The change of visual function in Chediak-Higashi syndrome has not been well described.

**Cases:** The visual function of a 12-year-old Japanese girl with ocular albinism due to Chediak-Higashi syndrome was followed by periodic ophthalmological examinations.

**Observations:** A lack of pigmentation in the iris and ocular fundus, and pigmentary degeneration of the peripheral retina were observed. The visual loss and the constriction of visual field progressed with increasing age. The electroretinogram was extinguished at 12 years of age.

**Conclusions:** The constriction of the visual field may be due to the pigmentary degeneration of the ocular fundus. Ophthalmologists should be aware that progressive visual loss and the constriction of visual field can occur in patients with Chediak-Higashi syndrome as they grow older. **Jpn J Ophthalmol 2003;47:304–306** © 2003 Japanese Ophthalmological Society

**Key Words:** Chediak-Higashi syndrome, electroretinogram, visual acuity, visual field.

---

## Introduction

Chediak-Higashi syndrome (CHS) is an autosomal recessive disorder with photophobia, partial oculocutaneous albinism, nystagmus, recurrent infection, hepatosplenomegaly, abnormal granulation of leukocytes, and early death.<sup>1,2</sup> We examined a CHS patient who was followed until 12 years of age and who showed a progressive decrease of visual function and a constriction of her visual fields.

## Materials and Methods

A young Japanese girl with ocular albinism due to CHS was followed by periodic, complete ophthalmological examinations.

## Results

The patient had been examined by an ophthalmologist in March 1999, when she was 9 years old and complained

of miodesopsia in her left eye. Vitreous and subretinal hemorrhages were detected, and she was referred to the Osaka University Hospital.

A pediatric examination revealed hepatosplenomegaly and lymphadenopathy, and a blood smear showed abnormal granules in neutrophils and lymphocytes. The frequent incidence of fever from infection was reported in this patient. These findings confirmed the diagnosis of CHS. A brain magnetic resonance image (T2) showed a high intensity area around the ventricle. She was the first child, and her younger sister had died of CHS at the age of 4 years.

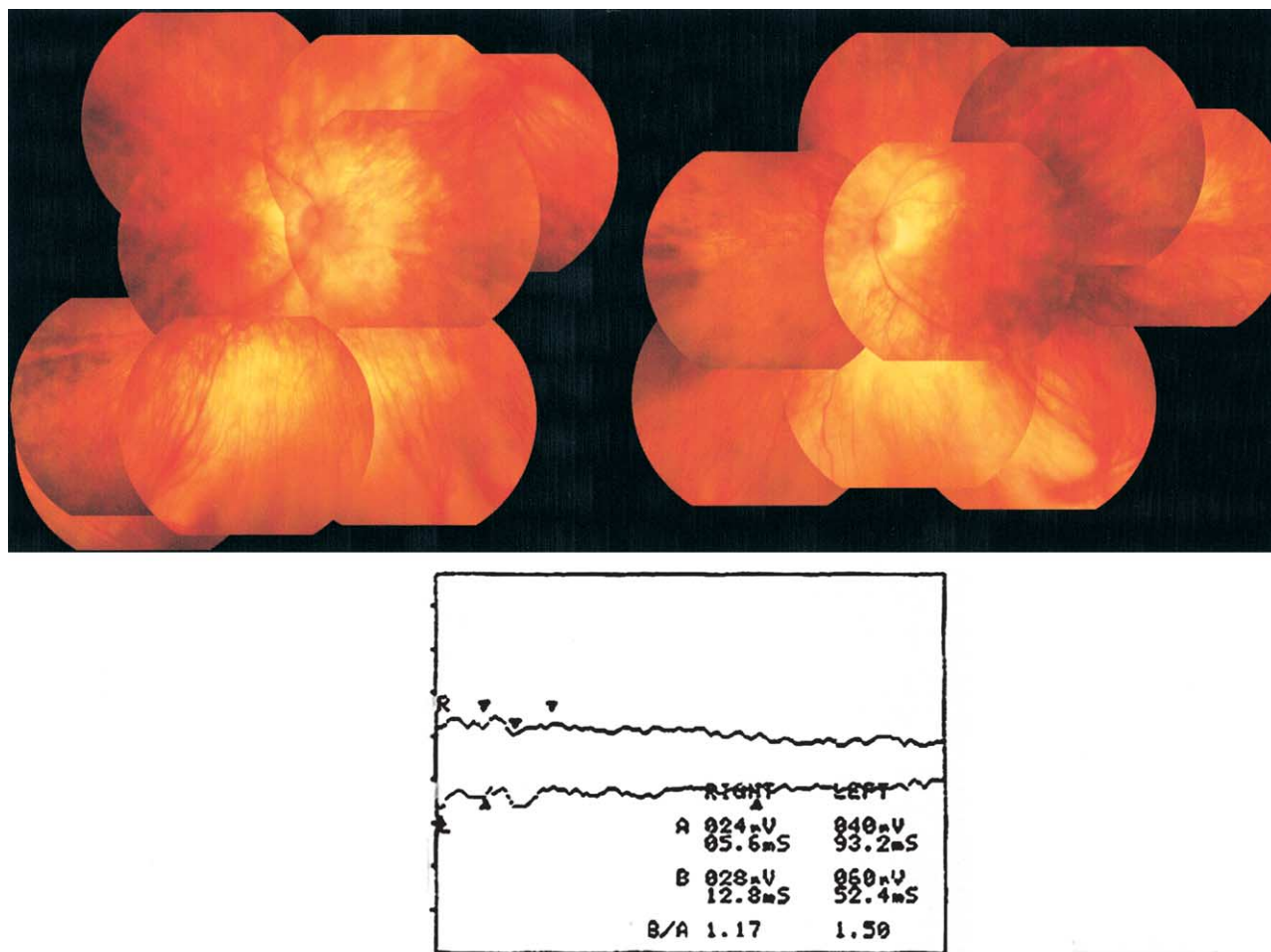
At her first visit, her best-corrected visual acuity (BCVA) was OD, 1.2 and OS, 0.2. The iris lacked pigmentation, and vitreous hemorrhage and ocular albinism were noted OU. Nystagmus was not observed. We waited for the vitreous hemorrhage to be absorbed before any treatment.

At the second visit in August 2000, her visual acuity was OD, 0.7 and OS, 0.4. Although the vitreous hemorrhage was almost absorbed, her BCVA in the left eye was only slightly improved. Ophthalmoscopy now showed pigmentary degeneration in the peripheral retina OU (Figure 1).

---

Received: August 29, 2002

Correspondence and reprint requests to: Takashi FUJIKADO, MD, Department of Visual Science, Osaka University Graduate School of Medicine, Room G4, 2-2 Yamadaoka, Suita, Osaka 565-0871, Japan



**Figure 1.** (Top right) Right ocular fundus and (top left) left ocular fundus of the patient in August 2000. We can see an albino fundus in the posterior pole, and pigmentary degeneration in the peripheral retina in both eyes. (Bottom) Results of electroretinography in April 2002, showing almost completely extinguished waveforms.

Approximately 1 year later in July 2001, she returned, complaining of photophobia and night blindness. Her visual acuity was OD, 0.5 and OS, 0.4, and a constriction of the visual field was observed OU.

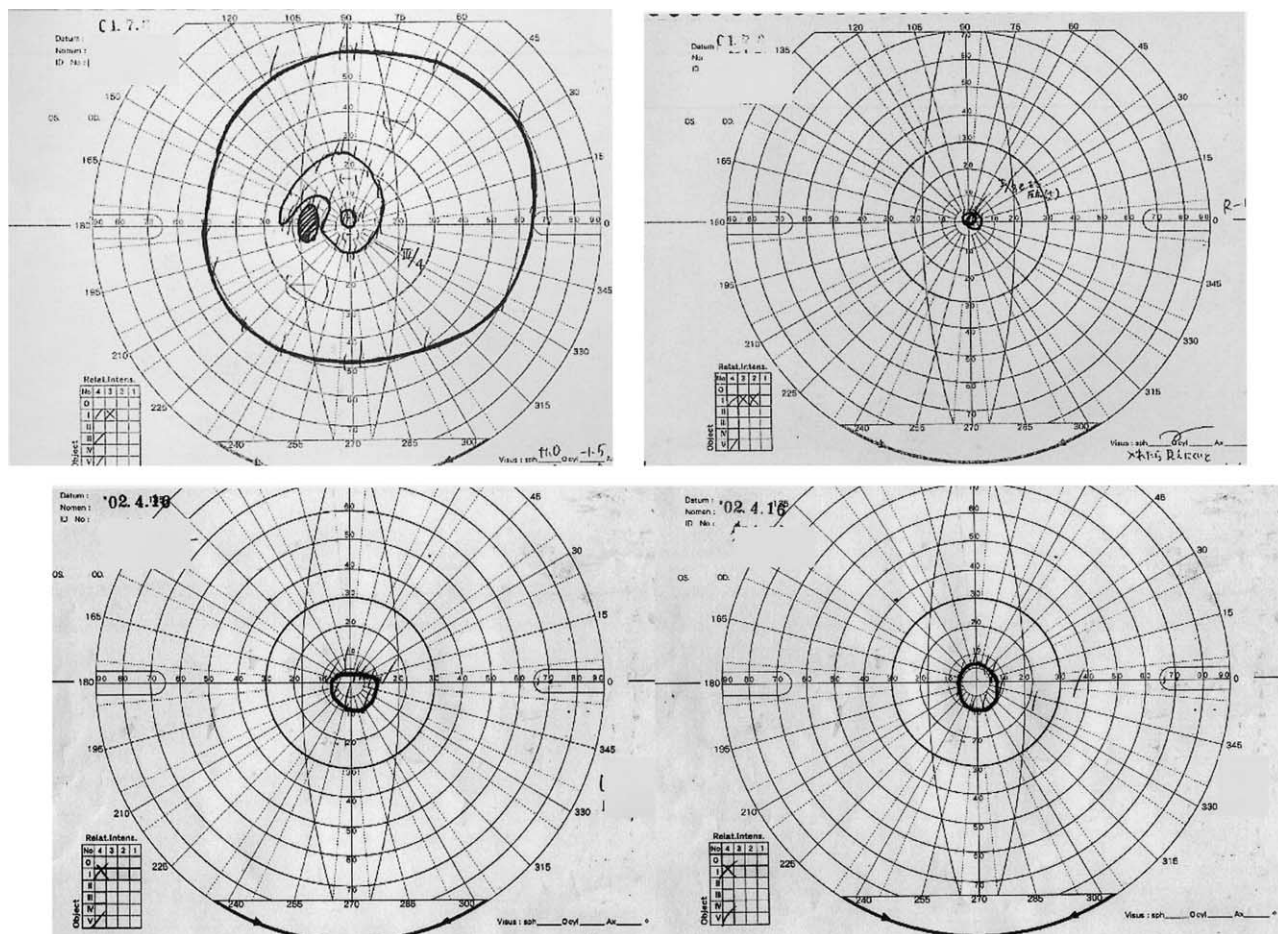
At her last visit in April 2002, her visual acuity was OD, 0.3 and OS, hand motion. The constriction of the visual field had markedly progressed (Figure 2), and the electroretinogram was extinguished OU (Figure 1).

### Discussion

Our case showed a progressive decrease of visual acuity and constriction of the visual field. The decrease of retinal function, as was also found by BenEzra and Mengistu,<sup>2</sup> was confirmed by electroretinography. As far

as we know, this is the first report of an older CHS patient who demonstrated a progressive decrease of visual functions with constriction due to this syndrome.

Mutation of the gene for CHS leads to abnormal CHS protein that causes a disturbance in the lysosomal secretions.<sup>3</sup> In an animal model of CHS, there was a fusion of premelanosomes with lysosomes, and the resultant destruction of the premelanosomes may induce the ocular hypopigmentation and degeneration of the retinal pigment epithelial (RPE) cells.<sup>4,5</sup> If the RPE degeneration increases with age, disturbances of retinal function may result as in retinitis pigmentosa of RPE origin, leading to a constriction of visual field. As ophthalmologists, we should be aware that progressive visual loss and the constriction of the visual field will occur in patients with CHS with ocular albinism as they grow older.



**Figure 2.** Goldmann perimetry of the right eye (top right) and the left eye (top left) in July 2001. Right field is constricted to  $<10^\circ$  and left field shows general depression. Goldmann perimetry of the right eye (bottom right) and the left eye (bottom left) on April 2002. Both fields are constricted to less than  $10^\circ$ .

This study was supported by Health Science Grant, Japan, and by a grant from the Ministry of Education, Culture, Sports, Science and Technology (no. 14571670), Japan.

### References

- Higashi O. Congenital gigantism of peroxidase granules. The first case ever reported of qualitative abnormality of peroxidase. *Tohoku J Exp Med* 1954;59:315.
- BenEzra D, Mengistu F. Chediak-Higashi syndrome: ocular findings. *J Pediatr Ophthalmol Strabismus* 1980;17:68-74.
- Nagle DL, Karim MA, Woolf EA, et al. Identification and mutation analysis of the complete gene for Chediak-Higashi syndrome. *Nat Genet* 1993;14:307-311.
- Collier LL, King EJ, Prieur DJ. Aberrant melanosome development in the retinal pigment epithelium of cats with Chediak-Higashi syndrome. *Exp Eye Res* 1985;41:305-311.
- Collier LL, King EJ, Prieur DJ. Age-related changes of the retinal pigment epithelium of cats with Chediak-Higashi syndrome. *Invest Ophthalmol Vis Sci* 1986;27:702-707.