

A Study of Laser Photocoagulation for Polypoidal Choroidal Vasculopathy

Mitsuko Yuzawa, Ryuzaburo Mori and Miho Haruyama

Department of Ophthalmology, Nihon University, Tokyo, Japan

Purpose: To evaluate the efficacy of laser photocoagulation for polypoidal choroidal vasculopathy (PCV) involving the macula.

Methods: The records of 38 patients (47 eyes) undergoing laser photocoagulation for PCV causing serosanguineous detachment involving the fovea were reviewed and the results were evaluated. Ten eyes underwent photocoagulation to induce a fusion scar covering whole lesions consisting of both abnormal vessels and polypoidal lesions. Thirty-seven eyes underwent photocoagulation for only polypoidal lesions. When serosanguineous detachment recurred, additional photocoagulation was performed, targeting the causative lesions. Photocoagulation was performed with an argon dye laser or multicolor krypton laser. Final visual acuity, macular changes at the final visit, and the number of photocoagulations were evaluated. Follow-up period after the first photocoagulation was at least 1 year.

Results: Of the 10 eyes undergoing photocoagulation of whole lesions, 9 showed absorption of exudate and/or blood after one photocoagulation, and maintained or improved visual acuity. Of the 37 eyes undergoing laser photocoagulation of only polypoidal lesions, 20 (54%) showed decreased visual acuity because of recurrent or persistent exudation and/or classic choroidal neovascularization or, alternatively, because of atrophy at the fovea; 32 of the 37 eyes had undergone photocoagulation at least twice or more.

Conclusion: Photocoagulation is recommended only for whole lesions. **Jpn J Ophthalmol 2003;47:379–384** © 2003 Japanese Ophthalmological Society

Key Words: Classic choroidal neovascularization, photocoagulation, polypoidal choroidal vasculopathy, serosanguineous detachment, visual outcome.

Introduction

Polypoidal choroidal vasculopathy (PCV) is a distinct clinical entity associated with multiple recurrent serosanguineous detachments of the retinal pigment epithelium and neurosensory retina, caused by leakage and bleeding from a peculiar choroidal vascular lesion.^{1,2} PCV involves a network of branching vessels external to the choriocapillaris and multiple, terminal reddish-orange, aneurismal, or polypoidal lesions.³ Indocyanine green angiography (IA) is useful for identifying these abnormalities and for distinguishing them from age-related macular degeneration^{3,4}

and chronic central serous chorioretinopathy.⁵ Although many patients undergoing laser photocoagulation have been reported, the efficacy and safety of this treatment have not yet been established.^{5,6} We had reported conducting laser photocoagulation on a small number of patients with PCV.^{7,8} As the number of cases increased and the follow-up period after photocoagulation lengthened, we reassessed the macular findings and visual outcomes after laser photocoagulation of the entire lesion, including networks of branching vessels and polypoidal lesions, and of polypoidal lesions only.

Materials and Methods

Thirty-eight patients (47 consecutive eyes; 29 men, 9 women, 54–82 years old, mean = 73 years) underwent

Received: August 1, 2002

Correspondence and reprint requests to: Mitsuko YUZAWA, MD, Department of Ophthalmology, Surugadai Hospital, Nihon University, 1-8-13 Surugadai, Kanda, Chiyoda-ku, Tokyo 101-8317, Japan. E-mail: yuzawam@med.nihon-u.ac.jp

their first laser photocoagulation for PCV at our hospital between June 1995 and December 1999 and were followed-up for at least 1 year. Another 6 patients who dropped out within 1 year after photocoagulation were excluded from the study. The 47 eyes did not show evidence of classic choroidal neovascularization (CNV) on fluorescein angiography (FA) before photocoagulation. The diagnosis of PCV was made based on IA findings; ie, the presence of a network of branching vessels and polypoidal lesions in the macular area. All 47 eyes showed serosanguineous detachment of the retinal pigment epithelium or neurosensory retina including the fovea, resulting from leakage and bleeding from the lesion. The uncertainty of the outcome of photocoagulation was discussed with the patients, and only those who consented to the treatment underwent laser photocoagulation. Photocoagulation targeting the whole lesion, ie, including both the network and polypoidal lesions, was performed when the lesion was present outside the fovea. When part of the network was under the fovea, only the polypoidal lesions causing leakage and/or bleeding situated outside the fovea were coagulated.

Intense photocoagulation, 200 μ m in diameter and 0.2 seconds in duration, to induce a fusion scar, was performed with an argon dye laser or multicolor krypton laser. Follow-up examinations were performed at 1 week, 1 month, 3 months, 6 months, and 1 year after photocoagulation and every 6 months thereafter, as a rule, and also when patients noticed symptoms. Visual acuity and macular changes were evaluated at each examination by indirect ophthalmoscopy and slit-lamp biomicroscopy with a contact lens. Both FA and IA were performed when serosanguineous detachment recurred. When IA showed leakage from polypoidal lesions outside the fovea, additional laser photocoagulation was performed. The follow-up period after the first photocoagulation ranged from 13–122 months, with a mean of 51 months. We assessed the number of photocoagulation treatments and final visual acuity by dividing the eyes into three groups based on follow-up periods of 13–36 months, 37–60 months, and 61 months or more. Improvement of visual acuity was defined as improvement of two or more lines. We also evaluated macular findings including subretinal classic CNV.

Results

The outcome in the 47 eyes, consisting of 1 eye for each of the 10 patients undergoing laser photocoagulation of whole lesions, and the 37 eyes of 28 patients undergoing laser photocoagulation of only polypoidal lesions, were evaluated.

Laser Photocoagulation of Whole Lesions

The frequency of laser photocoagulation of whole lesions was once in 9 eyes and twice in 1 eye. This second photocoagulation was performed targeting vessels that had caused persistent retinal detachment 3 months after the first photocoagulation. The number of photocoagulations did not increase as the follow-up period increased (Table 1). Serosanguineous detachment disappeared rapidly after photocoagulation. Neither recurrence of serosanguineous detachment, bleeding, nor subsequent development of subretinal classic CNV occurred during the follow-up period. Visual acuity improved in 2 eyes (20%), was maintained in 7 eyes (70%), and had deteriorated in 1 eye at the final follow-up (Figure 1). Decreased vision in this 1 eye was due to retinal atrophy noticed at the final follow-up examination at 31 months. It had resulted from longstanding detachment of the sensory retina involving the fovea (Table 2).

Photocoagulation of Only Polypoidal Lesions

The frequency of laser photocoagulation of only polypoidal lesions was once in 16 eyes, twice in 10 eyes, three times in 4 eyes, and four times or more in 7 eyes. Thirteen of the 20 eyes (63%) with a follow-up period of 13–36 months underwent photocoagulation once. On the other hand, 8 of the 13 eyes (62%) with a follow-up period of at least 61 months required three or more photocoagulations (Table 3). Additional photocoagulation was performed in 17 eyes targeting remaining or newly formed polypoidal lesions, which resulted in recurrent serosanguineous detachment. Classic CNV developed in 8 eyes during the follow-up period. This CNV consisted of subretinal grayish lesions surrounded by subretinal hemorrhage and/or accompanied by retinal detachment and a classic pattern of hyperfluorescence that could be seen on FA. Subretinal CNV developed adjacent to laser scars within 3 months of laser photocoagulation in 4 of the 8 eyes. Additional photocoagulation of CNV in 3 eyes and surgical removal of CNV in 1 eye were performed. Final visual acuity improved in 7 eyes (19%), was maintained in 10 eyes (27%), and deteriorated

Table 1. Relationship Between the Number of Photocoagulation Sessions and the Follow-up Period for 10 Eyes Undergoing Photocoagulation of Whole Lesions

No. of Photocoagulation Treatments	Follow-up period (months)			Total
	13–36	37–60	61+	
Once	5	3	1	9
Twice	1	–	–	1

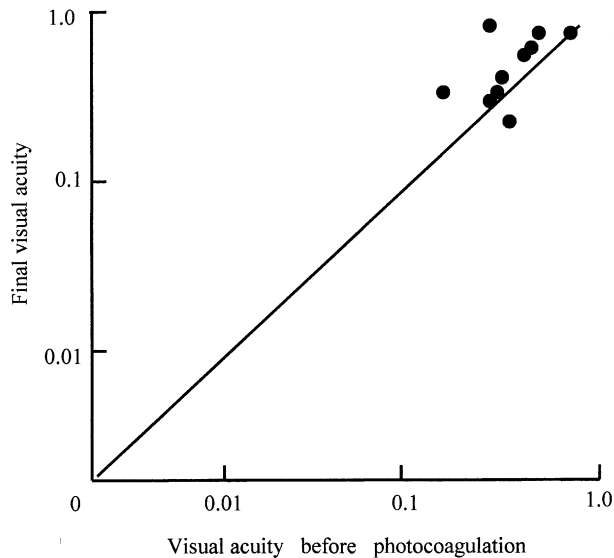


Figure 1. Visual outcome in 10 eyes undergoing laser photocoagulation of whole extra-foveal lesions.

in 20 eyes (54%) (Figure 2). Eight of the 20 eyes (40%) showed decreased vision at the final follow-up at 13–36 months after photocoagulation. In these 8 eyes, we observed subretinal classic CNV in 4, atrophy of the macula in 3, and vitreous hemorrhage in 1. On the other hand, in cases with a follow-up period of 61 months or more, 8 of the 13 eyes (62%) showed decreased vision at the final follow-up (Table 4). Seven of these 8 eyes showed persistent or recurrent neurosensory retinal detachment or atrophy caused by longstanding exudation at the macula. Decreased vision in 1 eye resulted from neurosensory retinal detachment due to subretinal classic CNV.

Case Reports

Photocoagulation of a Whole Lesion

Case 1. The patient was a 67-year-old man who had metamorphopsia of the left eye. Corrected visual acuity

Table 2. Visual Acuities of 10 Eyes Undergoing Photocoagulation of Whole Lesions

Visual Acuity	Follow-up Period (months)			Total
	13–36	37–60	61+	
Improvement	2			2
No change	3	3	1	7
Deterioration	1*			1

*Due to atrophy involving the fovea.

Table 3. Relationship Between the Number of Photocoagulation Sessions and Follow-up Period for 37 Eyes Undergoing Photocoagulation of Only Polypoidal Lesions

No. of Photocoagulation Treatments	Follow-up Period (months)			Total
	13–36	37–60	61+	
Once	13	2	1	16
Twice	4	2	4	10
Three times or more	3	–	8	11

was 0.02 in the right eye and 1.0 in the left eye. Ophthalmoscopic examination showed fibrous tissue, 2 disc diameters in size, involving the fovea in the right eye. Atrophy of the retinal pigment epithelium with two reddish lesions inferonasal to the macula and a shallow retinal detachment involving the fovea were observed in the left eye. At 14 months after his first visit, visual acuity in the left eye had decreased to 0.7. FA showed hyperfluorescence due to a window defect corresponding to the atrophy, and IA revealed the presence of an abnormal vasculature characteristic of PCV and many polypoidal lesions (Figure 3).

Photocoagulation was performed once, targeting both the abnormal vessels and the polypoidal lesions. Five years after photocoagulation, visual acuity was 0.9. Neither retinal detachment nor abnormal IA findings were observed (Figure 4).

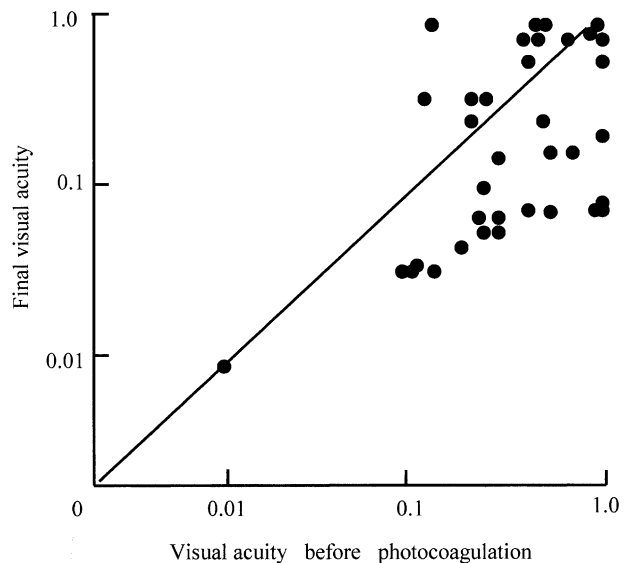


Figure 2. Visual outcome in 37 eyes undergoing laser photocoagulation of only polypoidal lesions.

Table 4. Final Visual Acuities of 37 Eyes Undergoing Photocoagulation of Only Polypoidal Lesions

Visual Acuity	Follow-up Period (months)			Total
	13–36	37–60	61+	
Improvement	5	–	2	7
No change	7	–	3	10
Deterioration	8	4	8	20

Photocoagulation of Only Polypoidal Lesions

Case 2. A 61-year-old man came to our hospital with decreased vision in his left eye. Visual acuity was 0.03 in the right eye and 0.3 in the left eye.

Retinal pigment epithelium (RPE)-choriocapillaris atrophy with some pigment deposition was observed in the macula of the right eye, and retinal detachment involving the fovea and a small hemorrhagic detachment infero-temporal to the fovea were observed in the left eye (Figure 5A). IA showed abnormal vasculature horizontally crossing the macula and small hyperfluorescent spots at the edge of the vasculature (Figures 5B, 5C).

Photocoagulation was performed targeting all the hyperfluorescent spots, which indicated polypoidal lesions. Both retinal detachment and RPE detachment subsided and visual acuity increased to 0.6 at 3 months after photocoagulation and to 0.9 at 17 months after photocoagulation. IA showed hypofluorescence corresponding to the laser scars (Figure 6).

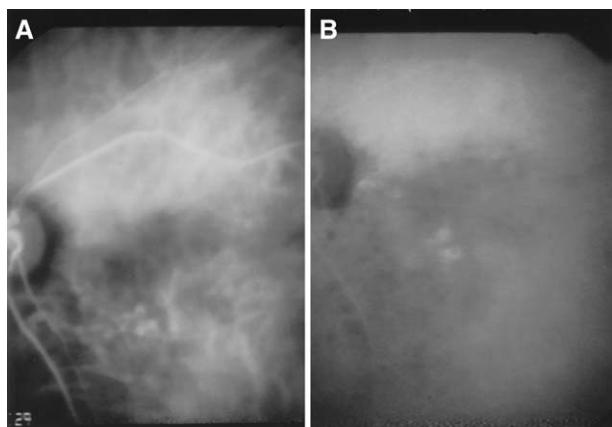


Figure 3. (A) Abnormal choroidal vascular lesion with many small hyperfluorescent lesions can be seen in the middle phase and (B) dye leakage corresponding to small hyperfluorescent lesions is apparent in the late phase of indocyanine green angiography. Obtained in case 1, four months after initial visit.

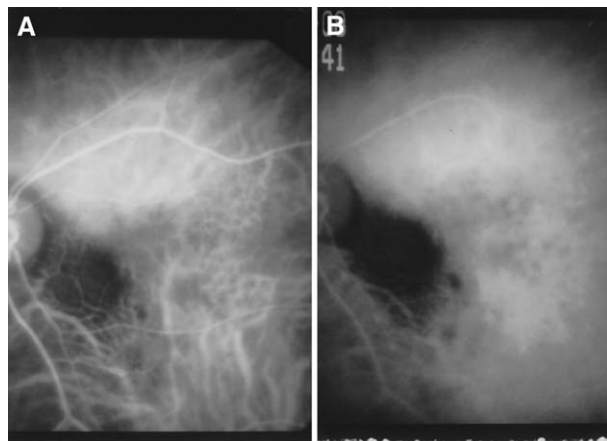


Figure 4. (A) Indocyanine green angiography from case 1, five years after photocoagulation shows no abnormal choroidal hyperfluorescence in the early or (B) late phases.

However, retinal detachment recurred and IA showed new abnormal vasculature and small hyperfluorescent areas, and visual acuity decreased to 0.3 at 4 years after photocoagulation due to retinal detachment. Photocoagulation of a suspected causative lesion was conducted twice.

The detachment persisted for 5 months (Figure 7A), visual acuity remained at 0.3, and IA showed abnormal choroidal vasculature and hyperfluorescent spots beyond the temporal edges of the laser scar (Figures 7B, 7C).

Discussion

Polypoidal choroidal vasculopathy is a distinct clinical entity resulting in multiple recurrent serosanguineous detachments of the retinal pigment epithelium and neurosensory retina. Vascular abnormalities causing serosanguineous detachment are reported to commonly originate in the temporal juxtaperipapillary choroidal vasculature in western countries.^{1–4} In other reports, they are common in the macular area and may cause decreased vision.⁶ Fifty percent of 14 eyes were reported to experience decreased vision in the natural course of PCV.⁹ However, optimal management is still controversial. It has been reported that photocoagulation should be considered when subretinal fluid or exudation is present.¹⁰ On the other hand, 24% of 17 eyes that underwent laser photocoagulation showed decreased vision, and the visual prognosis was worse than that for nonphotocoagulated eyes.⁶ Two eyes that underwent laser photocoagulation of polypoidal lesions were reported to have improved visual acuity and absorption of retinal detachment. However, CNV developed in 1 eye.⁵

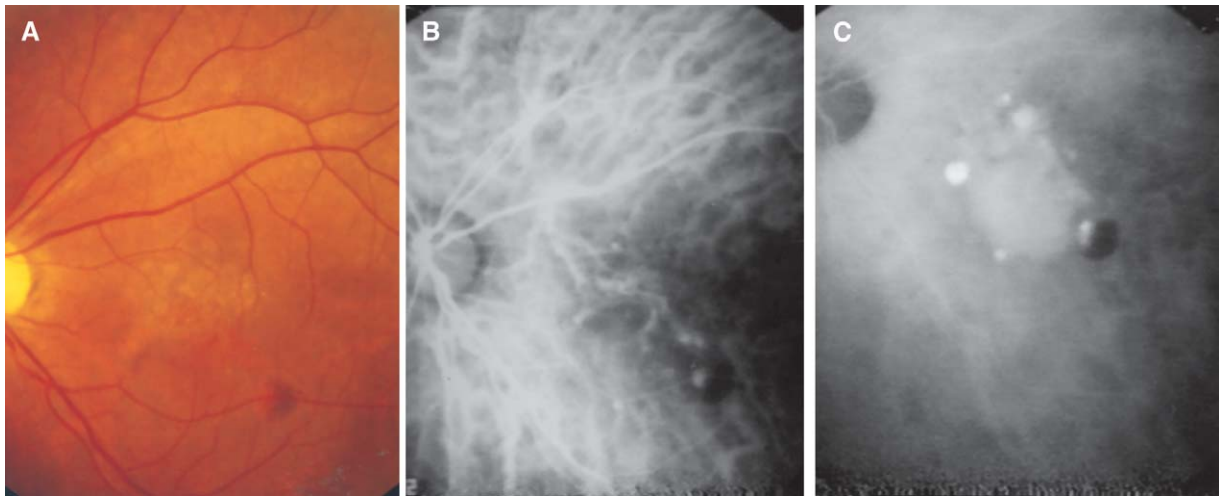


Figure 5. (A) Color photography of the left fundus in case 2 at the initial visit. Retinal detachment involving the fovea and a small hemorrhagic pigment epithelial detachment inferotemporal to the fovea are present. (B) An early-phase of indocyanine green angiography shows branching choroidal vessels horizontally crossing the macula and small hyperfluorescent spots at the edge of the vasculature. (C) Weak hyperfluorescence corresponding to branching choroidal vessels with intense hyperfluorescent spots are evident in the late phase.

In our study, 9 of the 10 eyes that underwent laser photocoagulation of whole extrafoveal lesions showed improvement or maintained visual acuity. This means that recurrent serosanguineous detachment is unlikely to occur after a whole lesion is coagulated unless a new lesion consisting of a vascular network and polypoidal lesion develops at another site. This method seems to be useful for improving and/or maintaining visual acuity. However, the usefulness of this photocoagulation procedure is questionable because of the small number of eyes in this study.

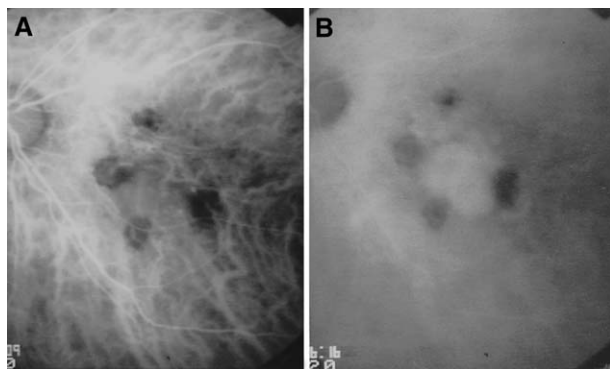


Figure 6. (A) Indocyanine green angiography after photocoagulation shows hypofluorescent spots corresponding to laser scars of all treated polypoidal lesions in the early phase. In the late phase (B), hyperfluorescence corresponding to branching choroidal vessels is the same as that before photocoagulation.

When only the polypoidal lesion that had caused the serosanguineous detachment, or only all polypoidal lesions were coagulated, the visual outcome was poor. This tendency became more pronounced as the follow-up period lengthened. This is thought to be due to damage to the retina at the fovea by recurrent serosanguineous detachment originating from remaining or newly formed polypoidal lesions from undetermined sources. The subretinal classic pattern of choroidal neovascular membrane development was another cause of decreased vision. CNV development adjacent to the laser scar within 3 months after laser photocoagulation might be stimulated by the preceding photocoagulation. It was also reported to develop 8 months after removal of submacular hemorrhage associated with PCV.¹¹ In PCV, CNV growing into subretinal space may occur as the natural course of the disease.⁸ These findings indicate that the prognosis for eyes undergoing photocoagulation of only polypoidal lesions worsens as the follow-up period lengthens, because of the recurrence of serosanguineous detachment originating from remaining or newly formed polypoidal lesions and/or secondary CNV, or atrophy at the fovea. Therefore, photocoagulation leaving a vascular network is apparently inadequate treatment. However, it might be useful to delay the progression of decreased vision, which may follow in the natural course of PCV. A prospective randomized clinical trial is needed to confirm the efficacy of photocoagulation of only polypoidal lesions when the network is under the fovea. Alternative treatment for whole lesions involving the fovea, such as photodynamic

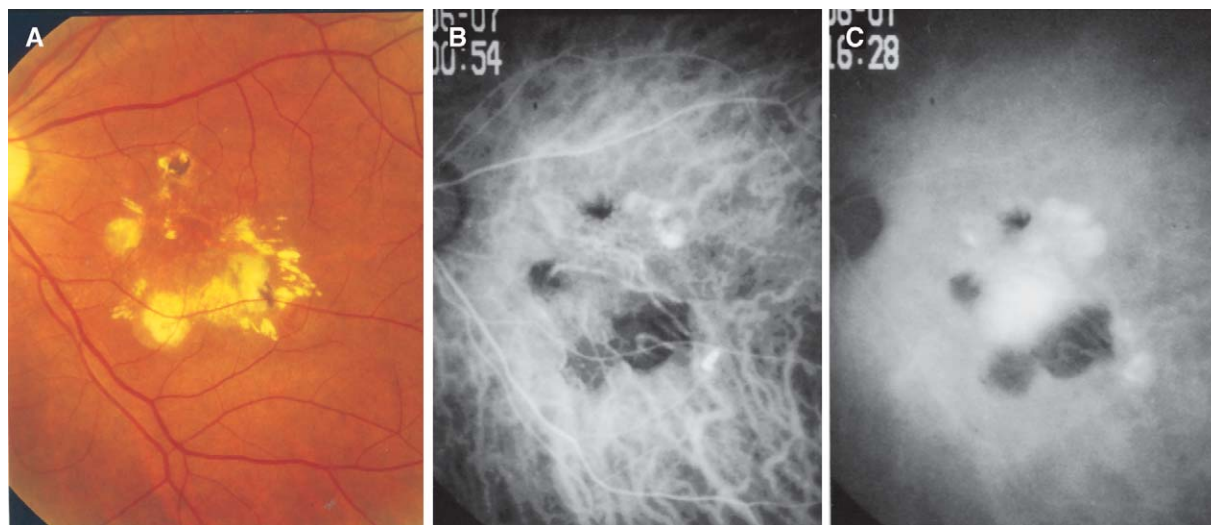


Figure 7. (A) Color photograph of the left fundus of case 2, fifty-three months after the first photocoagulation, shows retinal detachment with a small amount of hard exudates. (B) Indocyanine green angiography reveals hyperfluorescence, showing that abnormal choroidal vasculature is expanding temporal to the hypofluorescence due to laser scars, in the early phase. (C) Terminal hyperfluorescent spots are visible in the late phase.

therapy or transpupillary thermotherapy, should also be evaluated.

This study was supported by a Research Committee on Chorioretinal Degeneration and Optic Atrophy, The Ministry of Health, Labor, and Welfare of Japan.

References

1. Yannuzzi LA, Sorenson J, Spaide RF, et al. Idiopathic polypoidal choroidal vasculopathy (IPCV). *Retina* 1990;10:1–8.
2. Spaide RF, Yannuzzi LA, Slakter JS, et al. Indocyanine green videoangiography of idiopathic polypoidal choroidal vasculopathy. *Retina* 1995;15:100–110.
3. Yannuzzi LA, Wong DW, Sforzolini BS, et al. Polypoidal choroidal vasculopathy and neovascularized age-related macular degeneration. *Arch Ophthalmol* 1999;117:1503–1510.
4. Yannuzzi LA, Ciardella A, Spaide RF, et al. The expanding clinical spectrum of idiopathic polypoidal choroidal vasculopathy. *Arch Ophthalmol* 1997;115:478–485.
5. Yannuzzi LA, Freund KB, Goldbaum M, et al. Polypoidal choroidal vasculopathy masquerading as central serous chorioretinopathy. *Ophthalmology* 2000;107:767–777.
6. Uyama M, Matsubara TA, Fukushima I, et al. Idiopathic polypoidal choroidal vasculopathy in Japanese patients. *Arch Ophthalmol* 1999;117:1035–1042.
7. Yamanishi A, Kawamura A, Yuzawa M. Laser photocoagulation of idiopathic polypoidal vasculopathy. *Rinsho Ganka (Jpn J Clin Ophthalmol)* 1998;52:1691–1694.
8. Mori R, Yuzawa M, Haruyama M, Yamanishi A. Outcome of laser photocoagulation to treat polypoidal choroidal vasculopathy. *Nihon Ganka Kyo (Folia Ophthalmol Jpn)* 2001;52:284–290.
9. Uyama M, Wada M, Nagai Y, et al. Polypoidal choroidal vasculopathy: natural history. *Am J Ophthalmol* 2002;133:639–648.
10. Moorthy RS, Lyon AT, Rabb MF, et al. Idiopathic polypoidal choroidal vasculopathy of the macula. *Ophthalmology* 1998;105:1380–1385.
11. Shiraga F, Matsuo T, Tokoe S, et al. Surgical treatment of submacular hemorrhage associated with idiopathic polypoidal choroidal vasculopathy. *Am J Ophthalmol* 1999;128:147–154.