

# Visual Prognosis for Symptomatic Retinal Arterial Macroaneurysm

Toshie Tonotsuka, Masahito Imai, Katsuya Saito and Hiroyuki Iijima

*Department of Ophthalmology, Faculty of Medicine, University of Yamanashi, Yamanashi, Japan*

---

**Purpose:** To study the visual prognosis in eyes with symptomatic retinal arterial macroaneurysm (RAM).

**Methods:** Medical records were retrospectively reviewed for 62 patients (65 eyes) with symptomatic RAM.

**Results:** The median visual acuity at presentation was 0.4 for eyes with vitreous hemorrhage ( $n = 6$ ), 0.01 for eyes with premacular hemorrhage ( $n = 9$ ), 0.1 for eyes with submacular hemorrhage without premacular hemorrhage ( $n = 16$ ), 0.02 for eyes with submacular hemorrhage with premacular hemorrhage ( $n = 16$ ), and 0.3 for eyes with macular edema ( $n = 18$ ). The median value of the final visual acuity was 0.6 for vitreous hemorrhage, 0.7 for premacular hemorrhage, 0.1 for submacular hemorrhage without premacular hemorrhage, 0.1 for submacular hemorrhage with premacular hemorrhage, and 0.5 for macular edema.

**Conclusions:** The visual prognosis for eyes with symptomatic RAM depends on the macular pathology. Eyes with vitreous hemorrhage or premacular hemorrhage recover good vision, while the vision in those with submacular hemorrhage with or without premacular hemorrhage generally remains poor. New interventions including submacular surgery or pneumatic displacement of submacular hematoma should be evaluated in a future study in terms of visual prognosis for these eyes. **Jpn J Ophthalmol 2003;47:498–502** © 2003 Japanese Ophthalmological Society

**Key Words:** Pneumatic displacement of submacular hematoma, premacular hemorrhage, retinal arterial macroaneurysm, submacular surgery, visual prognosis.

---

## Introduction

Retinal arterial macroaneurysm (RAM) is a vascular dilatation usually seen within the first three orders of bifurcations in the retinal arterial vasculature.<sup>1</sup> This condition causes hemorrhages in various layers in the vitreoretinal tissues or macular edema, both of which may cause visual loss.<sup>2</sup> Several studies have demonstrated that eyes with RAM presenting with macular edema have the worst visual prognosis,<sup>3–5</sup> whereas others have claimed that the visual prognosis in those with submacular hemorrhage is the worst.<sup>6</sup> In our previous study written in Japanese,<sup>7</sup> final acuity was the poorest in eyes with RAM showing submacular hemorrhage.

The most popular therapeutic intervention for eyes with RAM is direct photocoagulation to the aneurysm itself to

reduce macular edema or to prevent rebleeding. Recently, other therapeutic interventions have been reported in the literature. Submacular hematoma can be removed by submacular surgery with tissue plasminogen activator (tPA).<sup>8–10</sup> The effectiveness of a nonsurgical intervention referred to as pneumatic displacement of submacular hemorrhage has also been reported.<sup>11,12</sup> In addition, photodisruption of the internal limiting membrane or the posterior hyaloid membrane using an Nd:YAG laser or argon laser to release the trapped blood in eyes with premacular hemorrhage may result in a quick recovery of vision.<sup>13–16</sup> To properly evaluate these new therapeutic interventions, more precise knowledge regarding the visual prognosis of the disease may be required. A retrospective evaluation of visual prognosis in eyes with RAM was therefore carried out in our clinic.

## Materials and Methods

We reviewed the medical charts of symptomatic patients with RAM who were seen in the University of

---

Received: November 7, 2002

Correspondence and reprint requests to: Hiroyuki IJIMA, MD, Department of Ophthalmology, Faculty of Medicine, University of Yamanashi, Tamaho, Yamanashi 409-3898, Japan. Tel.: +81 55 273 9657; fax: +81 55 273 6757; E-mail: hijimar@res-yamanashi-med.ac.jp

Yamanashi Hospital (formerly the Yamanashi Medical University Hospital) during the period from 1983 to June 2001. Those with follow-up periods of less than 30 days were excluded, as well as those with vision-threatening disorders other than RAM, such as glaucoma, uveitis, or high myopia. Sixty-two patients (65 eyes) were eligible for inclusion in the review. The subjects were 8 men and 54 women, with ages ranging from 50 to 92 with a mean of 74.4 years. The follow-up period ranged from 1 to 128 months with a mean of 13.8 months.

Each patient had been examined for best-corrected visual acuity on each visit. Examination by slit-lamp biomicroscopy was performed, and a color fundus photograph was taken at the initial examination. The diagnosis of RAM was made after confirmation of dye-filling in an aneurysm-like dilation of the arteriole by a fluorescein fundus angiogram or an indocyanine-green angiogram.

The study eyes were classified as follows, primarily on the basis of the macular pathology: vitreous hemorrhage (n = 6), premacular hemorrhage without submacular hemorrhage (n = 9), submacular hemorrhage without premacular hemorrhage (n = 16), both premacular and submacular hemorrhages (n = 16), or macular edema (n = 18). Eyes with premacular hemorrhage showed either subhyaloid hemorrhage, subinternal limiting membrane hemorrhage, or both. None of those with vitreous hemorrhage showed signs of premacular or submacular hemorrhages after the vitreous hemorrhage was cleared.

## Results

The clinical findings in each group are summarized in Tables 1 and 2. The initial and the final visual acuity in each group are shown in Figures 1 and 2.

The initial visual acuity in the 6 eyes with vitreous hemorrhage ranged from hand motion to 0.8. Three patients with dense vitreous hemorrhage that precluded visualization of the fundus were hospitalized. The affected eye was covered with an eye patch, with the fellow eye covered by a metal shield with a pinhole in the center to suppress voluntary eye movement. The patients were instructed to remain sitting during the daytime to accelerate gravitational settling of the blood in the vitreous. The blood in the vitreous usually precipitated in a couple of days, making it possible to visualize the fundus appearance. The other patients were instructed to rest at home. None of the patients underwent vitrectomy. After the intravitreal blood had been absorbed or had precipitated, prophylactic laser photocoagulation to the aneurysm itself, where leakage was demonstrated in the fluorescein fundus angiogram, was carried out in 5 of the 6 eyes. Laser photocoagulation to the aneurysm itself was performed using either argon blue, argon green, yellow dye, orange dye, red dye, or a yellow multicolor laser. The final visual acuity in these eyes with vitreous hemorrhage ranged from 0.5 to 1.0. All 6 eyes attained 0.5 or better visual acuity.

The initial visual acuity in the 9 eyes with premacular hemorrhage without submacular hemorrhage ranged from counting fingers to 0.7. Most eyes (6 of 9 eyes) showed severe visual loss of 0.01 or worse. Five eyes with premacular hemorrhage underwent Nd:YAG laser hyaloidotomy to release the preretinal blood into the vitreous cavity.<sup>15</sup> The final vision ranged from 0.2 to 0.9. Seven of 9 eyes (78%) attained 0.5 or better vision.

Sixteen eyes with submacular hemorrhage without premacular hemorrhage showed initial visual acuity ranging from 0.01 to 0.8. Eleven of these 16 eyes received direct laser photocoagulation to prevent recurrent hemorrhage. No other interventions were conducted. The final visual

**Table 1.** Subject Data at Presentation

	No. of Patients	Age (median)	Male/Female	Initial Visual Acuity*			
				Range (median)	Median	≤0.1 <sup>†</sup>	≥0.5 <sup>†</sup>
Vitreous hemorrhage	6	73–82 (78.5)	1/5	HM–0.8	0.4	3 (50)	3 (50)
Premacular hemorrhage	9	68–83 (77)	3/6	CF–0.7	0.01	7 (78)	1 (11)
Submacular Hemorrhage	16	59–92 (72.5)	0/16	0.01–0.8	0.1	12 (75)	3 (19)
Without premacular Hemorrhage							
Both premacular and Submacular Hemorrhage	16	65–87 (76)	3/13	CF–0.3	0.02	15 (94)	0 (0)
Macular edema	18	50–87 (72.5)	3/15	0.01–0.6	0.3	6 (33)	2 (11)

\*HM: hand motion, CF: counting fingers.

<sup>†</sup>Values in parentheses are percentages.

**Table 2.** Follow-up Data

	Follow-up Months (median)	Final Visual Acuity (best corrections)*				Intervention*	
		Range	Median	≤0.1	≥0.5	Direct Laser Photocoagulation	Nd:YAG Hyaloidotomy
Vitreous hemorrhage	2–62 (11)	0.5–1.0	0.6	0 (0)	6 (100)	5 (83)	0 (0)
Premacular hemorrhage	3–18 (5)	0.2–0.9	0.7	0 (0)	7 (78)	1 (11)	5 (56)
Submacular hemorrhage Without premacular Hemorrhage	2–84 (8)	0.03–1.0	0.1	9 (56)	7 (44)	11 (67)	0 (0)
Both premacular and Submacular Hemorrhage	1–47 (8)	0.01–0.6	0.1	9 (56)	3 (19)	8 (50)	4 (25)
Macular edema	2–128 (9)	0.06–1.0	0.5	4 (22)	11 (61)	12 (67)	0 (0)

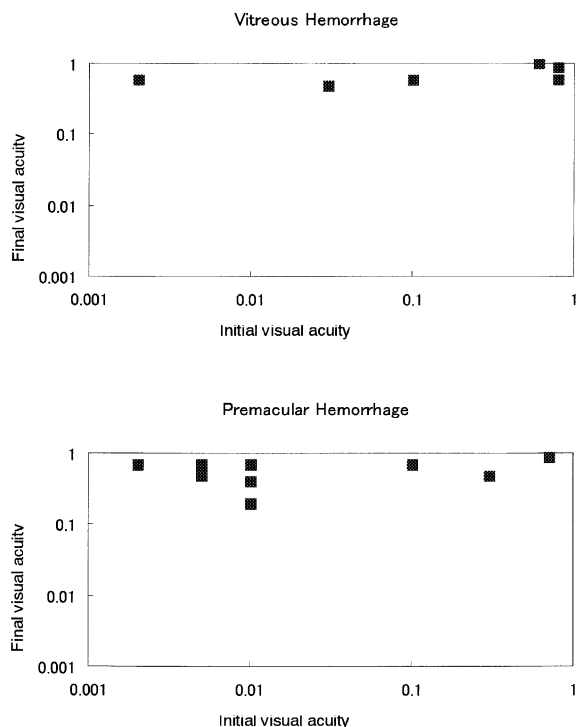
\*Values in parentheses are percentages.

acuity ranged from 0.03 to 1.0. Only 7 of the 16 eyes (44%) attained 0.5 or better vision. The median visual acuity was 0.1.

The 16 eyes with both submacular and premacular hemorrhage showed initial acuity ranging from counting fingers to 0.3. Eight eyes received direct laser photocoagulation to prevent recurrent hemorrhage, and 4 eyes received Nd:YAG laser hyaloidotomy to release the pre-retinal blood into the vitreous cavity. Two patients underwent pneumatic displacement of submacular hemorrhage.

A 76-year-old woman showed both premacular and submacular hemorrhages with visual acuity of 0.02 in her right eye. Because vision remained unchanged after the SF<sub>6</sub> gas injection followed by having the patient assume the prone position, this patient underwent surgery to remove the submacular hematoma. The final vision in her right eye has remained at 0.05 after 17 months. An 87-year-old man showed both premacular and submacular hemorrhages with visual acuity of counting fingers in his left eye. After C<sub>3</sub>F<sub>8</sub> gas injection the vitreous hemorrhage increased. He was treated by vitrectomy and C<sub>3</sub>F<sub>8</sub> gas tamponade. His vision was 0.02 at 2 months after surgery. The final visual acuity in eyes with both submacular and premacular hemorrhage ranged from 0.01 to 0.6. Only 3 of 16 (19%) attained 0.5 or better visual acuity.

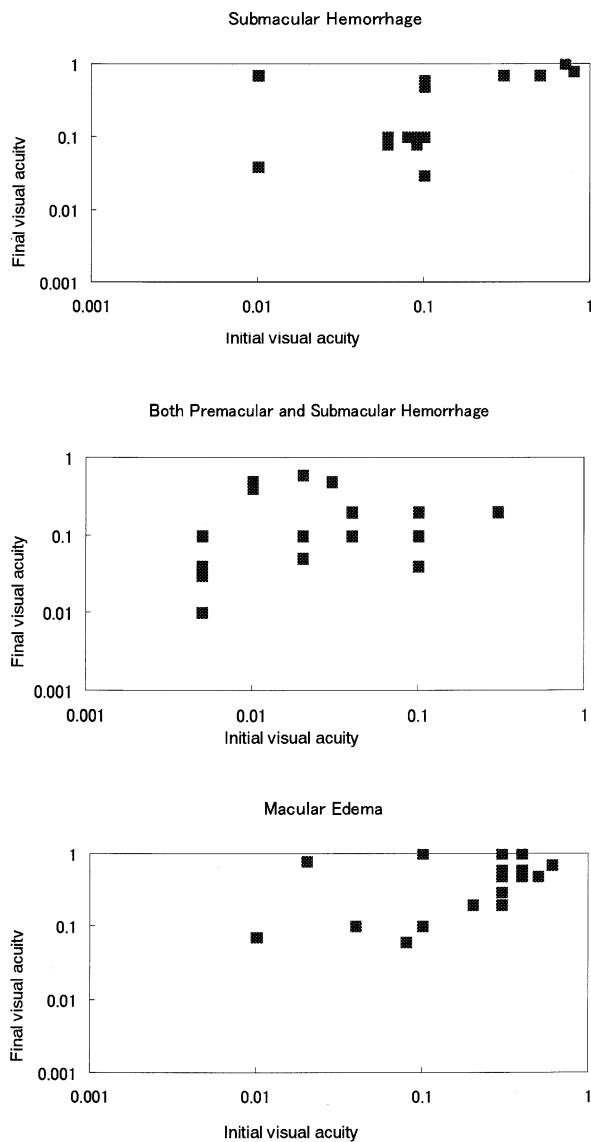
The initial visual acuity in 18 eyes with macular edema ranged from 0.01 to 0.6. Macular edema was identified both ophthalmoscopically and biomicroscopically. Fluorescein angiography disclosed leakage from the macroaneurysm in all eyes in this group; however, no eyes showed a cystoid pattern of dye pooling at the macula. Twelve of the 18 eyes received laser photocoagulation to the causal aneurysm to reduce edema. The final vision ranged from 0.06 to 1.0. Eleven of the 18 eyes (61%) attained 0.5 or better vision, while the vision in 4 of the 18 eyes (22%) remained 0.1 or worse.



**Figure 1.** Relationship between the initial visual acuity and the final visual acuity in the vitreous hemorrhage and premacular hemorrhage groups. Counting fingers and hand motion were plotted at 0.005 and 0.002, respectively.

## Discussion

Hemorrhage from ruptured RAM or edema from leaking RAM results in various degrees of visual loss depending on both the amount and location of the hemorrhage or edema. A severe visual loss of 0.1 or worse is generally observed at the first visit in eyes with macular hemorrhage independent of the retinal layers where the blood is located. The initial visual acuity in eyes with vitreous hemorrhage or macular edema in the



**Figure 2.** Relationship between the initial visual acuity and the final visual acuity in the submacular hemorrhage group, both premacular and submacular hemorrhage groups, and the macular edema group. Counting fingers and hand motion were plotted at 0.005 and 0.002, respectively.

present series, however, was relatively good, with a median initial visual acuity of 0.4 and 0.3, respectively.

The difference in visual prognosis among groups is apparent in Figures 1 and 2. Eyes with vitreous hemorrhage or premacular hemorrhage due to ruptured RAM eventually recovered better visual acuity compared with those with other macular pathology caused by RAM. The reason may be that the blood in the vitreous cavity, subhyaloid space, or subinternal limiting membrane rarely affects photoreceptors in the fovea under these conditions.

Some eyes with premacular hemorrhage underwent Nd:YAG laser photodisruption to shorten the disease period. It has been reported that premacular hemorrhage may eventually be absorbed and that the final visual acuity in eyes with Nd:YAG laser photodisruption and in those without it may not differ.<sup>2,3</sup> However, with this technique, patients can instantly be relieved of a severe visual handicap, with the resulting monocular vision otherwise likely to affect their social activity and general quality of life.<sup>15</sup>

The present results indicate the poorest visual prognosis in eyes with submacular hemorrhage with or without premacular hemorrhage. The final visual acuity was 0.1 or worse in more than half of these eyes. Bleeding into the subretinal space at the macula results in photoreceptor damage due to released toxins, outer retinal shear forces, and a diffusion barrier from choroidal circulation.<sup>17</sup> Because this photoreceptor damage due to subretinal hemorrhage may become irreversible within several days, prompt removal of the subretinal hematoma may be required to improve the visual prognosis.

Some researchers have claimed that eyes with submacular hemorrhage involving the center of the fovea can achieve fair visual acuity if submacular surgery with tPA is performed within 7 days after hemorrhage.<sup>10,18</sup> In the present study, most of the subjects were treated before this technique was clinically available, with the intervention having been performed only once after unsuccessful pneumatic displacement of the submacular hematoma. In these cases, the final vision was not much improved, probably because the submacular hematoma had existed for some time.

An alternative and less traumatic intervention is pneumatic displacement of the subretinal hematoma.<sup>11</sup> In this study, only 2 cases underwent this procedure, and in both cases the results were unsatisfactory. In 1 case, vitreous hemorrhage ensued and vitrectomy was required. Although we did not use tPA for the procedure, sudden dense vitreous hemorrhage has been reported after pneumatic displacement of a submacular clot using tPA.<sup>12,19</sup>

Because our experience with submacular surgery or pneumatic displacement of submacular hematoma is limited, the evaluation of these procedures should be determined based on more cases in the future.

The visual prognosis of eyes with macular edema due to RAM has been reported to be poor.<sup>3-5</sup> In the present series, some eyes showed a final visual acuity of <0.1, but the median vision was relatively good. Most eyes in this category underwent direct laser photocoagulation to stop leakage from the aneurysm, which may have contributed to the better visual prognosis compared with previous reports.

In conclusion, the visual prognosis in eyes with symptomatic RAM differs according to the pathology of the macula. Eyes with vitreous hemorrhage or premacular hemorrhage without submacular hemorrhage show better visual prognosis compared with eyes having other types of hemorrhage or macular edema. The visual prognosis of those with submacular hemorrhage with or without premacular hemorrhage is the poorest.

## References

1. Robertson DM. Macroaneurysms of the retinal arteries. *Trans Am Acad Ophthalmol Otolaryngol* 1973;77:OP55–OP67.
2. Rabb MF, Gagliano DA, Teske MP. Retinal arterial macroaneurysms. *Surv Ophthalmol* 1988;33:73–96.
3. Palestine AG, Robertson DM, Goldstein BG. Macroaneurysms of the retinal arteries. *Am J Ophthalmol* 1982;93:164–171.
4. Cleary PE, Kohner EM, Hamilton AM, Bird AC. Retinal macroaneurysms. *Br J Ophthalmol* 1975;59:355–361.
5. Lewis RA, Norton EW, Gass JD. Acquired arterial macroaneurysms of the retina. *Br J Ophthalmol* 1976;60:21–30.
6. Maruyama Y, Yamazaki S. Visual outcome in 53 eyes with retinal arteriolar macroaneurysm. *Rinsho Ganka (Jpn J Clin Ophthalmol)* 1991;45:1506–1512.
7. Saito K, Iijima H. Visual prognosis and macular pathology in eyes with retinal macroaneurysms. *Nippon Ganka Gakkai Zasshi (J Jpn Ophthalmol Soc)* 1997;1012:148–151.
8. Lim JJ, Drews-Botsch C, Sternberg P Jr, Capone A Jr, Aaberg TM Sr. Submacular hemorrhage removal. *Ophthalmology* 1995;102:1393–1399.
9. Ibanez HE, Williams DF, Thomas MA, et al. Surgical management of submacular hemorrhage. A series of 47 consecutive cases. *Arch Ophthalmol* 1995;113:62–69.
10. Humayun M, Lewis H, Flynn HW Jr, Sternberg P Jr, Blumenkranz MS. Management of submacular hemorrhage associated with retinal arterial macroaneurysms. *Am J Ophthalmol* 1998;126:358–361.
11. Ohji M, Saito Y, Hayashi A, Lewis JM, Tano Y. Pneumatic displacement of subretinal hemorrhage without tissue plasminogen activator. *Arch Ophthalmol* 1998;116:1326–1332.
12. Hassan AS, Johnson MW, Schneiderman TE, et al. Management of submacular hemorrhage with intravitreal tissue plasminogen activator injection and pneumatic displacement. *Ophthalmology* 1999;106:1900–1906; discussion 1906–1907.
13. Tassignon MJ, Stempels N, Van Mulders L. Retrohyaloid premacular hemorrhage treated by Q-switched Nd:YAG laser. A case report. *Graefes Arch Clin Exp Ophthalmol* 1989;227:440–442.
14. Raymond LA. Neodymium:YAG laser treatment for hemorrhages under the internal limiting membrane and posterior hyaloid face in the macula. *Ophthalmology* 1995;102:406–411.
15. Iijima H, Satoh S, Tsukahara S. Nd:YAG laser photodisruption for preretinal hemorrhage due to retinal macroaneurysm. *Retina* 1998;18:430–434.
16. Rennie CA, Newman DK, Snead MP, Flanagan DW. Nd:YAG laser treatment for premacular subhyaloid haemorrhage. *Eye* 2001;15:519–524.
17. Hochman MA, Seery CM, Zarbin MA. Pathophysiology and management of subretinal hemorrhage. *Surv Ophthalmol* 1997;42:195–213.
18. Saika S, Yamanaka A, Minamide A, et al. Subretinal administration of tissue-type plasminogen activator to speed the drainage of subretinal hemorrhage. *Graefes Arch Clin Exp Ophthalmol* 1998;236:196–201.
19. Kokame GT. Vitreous hemorrhage after intravitreal tissue plasminogen activator (t-PA) and pneumatic displacement of submacular hemorrhage. *Am J Ophthalmol* 2000;129:546–547.