

Reversible Horner's Syndrome and Dysthyroid Ocular Myopathy Associated with Hashimoto's Disease

Tamami Okamoto*, Manabu Kase*, Masahiko Yokoi* and Yasuo Suzuki†

*Department of Ophthalmology, Teine Keijin-kai Hospital, Sapporo, Japan;

†Department of Physiology, Hokkaido University School of Medicine, Sapporo, Japan

Background: Although it has been frequently stated that thyroid disease induces Horner's syndrome, there have been few reports describing the anatomical relation of goiter to the cervical preganglionic sympathetic nerve fibers in acquired Horner's syndrome, which is identified by the eye-drop test for adrenergic sensitivity.

Case: A 40-year-old woman with Hashimoto's disease presented with vertical diplopia, and blepharoptosis and miosis on the left side.

Observations: Computed tomography scan showed hypertrophy of the right inferior rectus muscle, which resulted from a dysthyroid process, causing the limitation of upward movement of the right eye. The eye-drop test for adrenergic sensitivity revealed that only the left pupil dilated significantly after administration of 5% tyramine, and the Mueller's muscle on the left side did not respond. These results suggest that Horner's syndrome was due to a preganglionic sympathetic lesion. Magnetic resonance imaging (MRI) of the neck showed chronic inflammatory lesions in both lobes of the thyroid gland identified by a high-intensity signal.

Conclusion: The reconstruction technique of MRI demonstrated that the swollen left lobe of the thyroid gland was compressing the pathway of the cervical preganglionic sympathetic nerve fibers. **Jpn J Ophthalmol 2003;47:587-590** © 2003 Japanese Ophthalmological Society

Key Words: Dysthyroid ocular myopathy, eye-drop test, Hashimoto's disease, Horner's syndrome, preganglionic sympathetic nerve.

Introduction

Horner's syndrome results from a disturbance of the oculosympathetic nervous system, which originates from the posterolateral hypothalamus, descends to the cervical spinal cord, and synapses in the superior cervical sympathetic ganglion. The fibers then ascend through the internal carotid plexus and innervate the Mueller's muscle, the pupillary dilator muscle, and the sweat glands of the face ipsilaterally. Patients with Horner's syndrome present with miosis, blepharoptosis, and facial anhidrosis.

Acquired Horner's syndrome is observed clinically with the lesion at different sites such as Wallenberg's syndrome,¹ thyroid disorders,²⁻⁶ or Raeder's syndrome.⁷

The involvement of the preganglionic sympathetic nerves occurs frequently in patients with goiter and following surgical injury to the thyroid gland.^{8,9} There are only a small number of reports on acquired Horner's syndrome that is caused by a preganglionic lesion and is identified by the instillation test for adrenergic supersensitivity.

The present case presented with Hashimoto's disease characterized by dysthyroid myopathy of the inferior rectus muscle with hypertrophy and Horner's syndrome, for which the preganglionic cervical sympathetic lesion was identified by eye-drop test.

Case Report

A 40-year-old woman was seen with a 3-month history of vertical diplopia and a 1-week episode of ipsilateral blepharoptosis.

Received: June 3, 2002

Correspondence and reprint requests to: Manabu KASE, MD, Department of Ophthalmology, Teine Keijin-kai Hospital, 1-12 Maeda, Teine-ku, Sapporo 0060811, Japan.

On the first examination, visual acuity was 0.05 (1.2×–5.5D) OD and 0.06 (1.0×–5.5D) OS. Intraocular pressure was 17 mm Hg in the right eye and 13 mm Hg in the left eye. Slit-lamp and ophthalmoscopic examinations revealed no abnormal findings. The patient had blepharoptosis, and the palpebral fissures were 10 mm and 3 mm on the right and left sides, respectively (Figure 1A). Both eyeballs moved conjugately except in the upward direction, where the right eye had limited movement (Figure 1B). There were no abnormalities in the sweat system. The diameter of the pupil was 2.5 mm in the right eye and 1.5 mm in the left eye in room light. Both pupils responded promptly to light and normally to near stimuli.

The eye-drop test was carried out to identify the site of the lesion. The pupillary area was measured with an infrared electropupillogram (Hamamatsu TV, Hamamatsu). The area of the pupil changed from 16.9 mm² and 14.5 mm² to 18.5 mm² and 15.1 mm² in the right and the left eyes, respectively, with the instillation of 1% neostigmine. The 5% tyramine test, on the other hand, enlarged the pupillary area from 17.0 mm² to 19.8 mm² in the right eye and from 13.1 mm² to 28.3 mm² in the left eye.

Computed tomography (CT) scan of the orbit showed a hypertrophy of the inferior rectus muscle on the right side (Figure 2). Magnetic resonance image (MRI) of the neck revealed bilateral, indistinct but circumscribed lesions identified by a high-intensity signal, which was larger on the left than on the right side (Figure 3A). The scan showed that the left lobe of the thyroid gland was significantly swollen. The reconstruction of cervical MRI with alignment shown by the oblique lines (B and C) in Figure 3A was done in order to clarify the anatomical

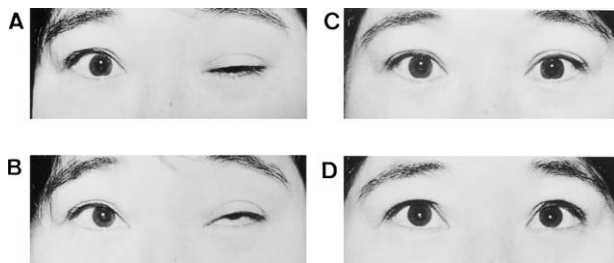


Figure 1. Patient with transient vertical diplopia and ipsilateral blepharoptosis recovered without treatment after 5 months of observation. Photographs of the face demonstrating the eye at the primary position (A and C) and on upward gaze (B and D). (A) and (B) were taken at the first examination, and (C) and (D) 5 months later. Blepharoptosis in the left eye can be observed in (A) and (B). The right eye has limited movement in upward direction (B). These ocular signs disappeared 5 months later (C and D).

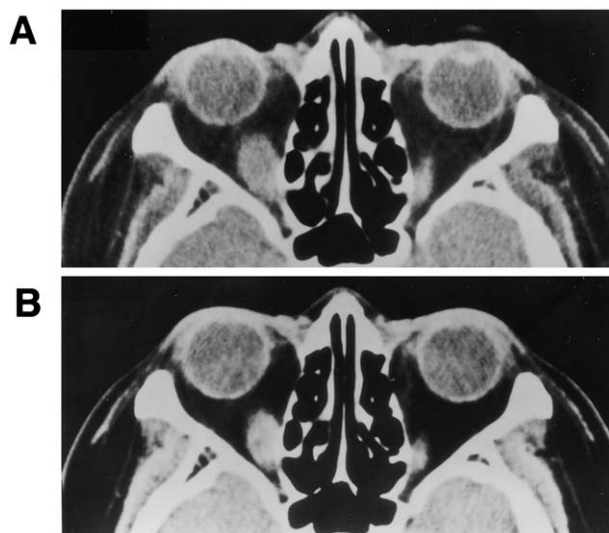


Figure 2. Computed tomographs at the first examination (A) and 5 months later (B). The right inferior rectus muscle is hypertrophied in (A).

relation of the thyroid gland to the cervical vertebra. The reconstruction demonstrated that the enlarged left lobe of the thyroid gland was compressing the left prevertebral fascia at the level of C-7 (arrows in Figure 3C), whereas the right prevertebral fascia was smooth and linear (Figure 3B).

Thyroid function tests showed that free T₃ was 3.0 pg/mL, free T₄ was 1.2 ng/dL, and thyroid-stimulating hormone (TSH) was 0.11 IU/mL. TSH receptor was 12.3%. Antimicrosomal complement fixation and thyroglobulin antibodies were 25,600× and <100, respectively. This patient was followed but no particular treatment was prescribed.

Five months later, blepharoptosis (Figure 1C), diplopia (Figure 1D) and anisocoria disappeared.

Discussion

The present patient was found to have transient miosis and blepharoptosis on the left side, and limitation of upward movement of the right eye caused by the hypertrophy of the inferior rectus muscle. These findings led to the diagnosis of Horner's syndrome in the left eye and dysthyroid ocular myopathy in the right eye. CT scan and MRI findings revealed that the lesions identified by high-intensity signals were observed in both lobes of the thyroid gland, being larger in the left lobe than in the right one, and suggesting Hashimoto's disease.

Only a small number of previous investigations have been concerned with the relationship between the occurrence of Horner's syndrome and Hashimoto's disease,

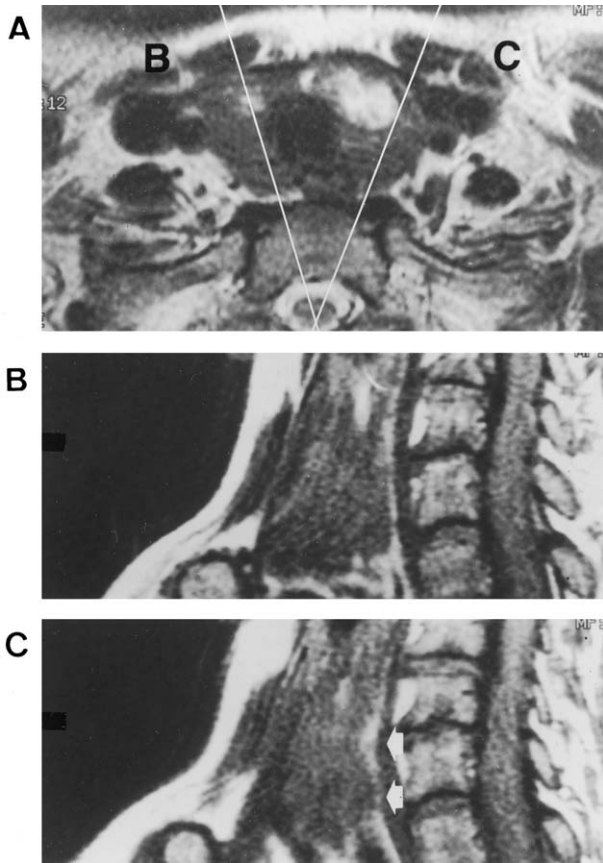


Figure 3. (A) T₂-weighted magnetic resonance image of the neck at the C₇ level shows the inflammatory lesions in both lobes of the thyroid gland identified by the high intensity signal on both sides (B), (C). T₁-weighted magnetic resonance images are reconstructed with alignment of the oblique lines indicated by B and C in (A). These images clearly showed the anatomical relationship between the swollen thyroid gland and the preganglionic fiber pathway (arrows).

even though goiters often induce Horner's syndrome.^{10–15} Horner's syndrome in the present case resulted from the involvement of the preganglionic sympathetic fibers because the pupil showed mydriasis to 5% tyramine but not to 1% neostigmine. On the other hand, the Mueller's muscle did not respond to the two transmitter drugs. It is likely that blepharoptosis was a sign of Horner's syndrome because CT scan and MRI revealed no abnormalities in the ocular muscles and the orbital tissues, and the left upper eyelid was elevated as soon as anisocoria resolved. Furthermore, MRI findings (Figure 3A) documented the swelling of the left lobe of the thyroid gland as well as chronic inflammatory changes. The reconstruction of MRI findings (Figure 3B and C) was performed in order to determine the anatomical relationship of the swollen thyroid gland to the preganglionic sympathetic nerve fibers. These preganglionic fibers originate from

the intermediolateral gray, leave the spinal cord with the ventral roots between C₈ and T₂, and ascend in the space between the prevertebral fascia anterior to the longus colli muscle and pretracheal fascia posterior to the thyroid gland. There was a significant difference in the configuration of the prevertebral fascia between the right and left sides, with the left fascia curved and protruding into the vertebral body cortex at the C₇ level. This suggested a site where the swollen thyroid gland compressed the preganglionic sympathetic trunk running between the prevertebral fascia and the long colli muscle. It is thus likely that the compression by the left lobe of the thyroid gland, enlarged by the inflammatory process, was responsible for the occurrence of Horner's syndrome. It has been clinically demonstrated that preganglionic lesions result usually in the failure of patients to sweat on the ipsilateral side of the face, whereas the lesions of localized C₇–T₁ are not accompanied by anhidrosis because the sudomotor fibers run with the sympathetic white rami from T₂–T₄.^{16,17} On the other hand, there were some reports on Horner's syndrome following a goiter, which showed no anhidrosis.² Thus, it is possible that the compression around the C₇ level in the present case spared the sudomotor fibers.

The right inferior rectus muscle was hypertrophied as noted in the CT scan (Figure 2), resulting in diplopia on upward gaze. It is well known that dysthyroid ocular myopathy occurs under hyperthyroid, euthyroid, or hypothyroid states^{10,15} and frequently involves the inferior rectus muscle first.¹⁸ It has been reported that dysthyroid ocular myopathy eventually develops and is associated with Hashimoto's disease, as in the present case. The hypertrophy of the inferior rectus muscle, therefore, was dysthyroid in origin because there were no signs suggesting ocular myositis or myasthenia gravis.

Reversible Horner's syndrome associated with a goiter has been described because successful removal of a goiter leads to the abatement of Horner's syndrome.⁵ It is, therefore, highly likely that the complete recovery from miosis and blepharoptosis observed during the follow-up period in this case was caused by the release of the compression of the swollen thyroid gland against the preganglionic sympathetic trunk.⁵ The dysthyroid ocular myopathy as manifested by the limitation of upward movement of the right eye also improved when Horner's syndrome disappeared.

References

1. Arai M. Wallenberg's syndrome following minor neck trauma: a case associated with atlanto-axial subluxation, an anomaly of the axis, and platelet activation. *Rinsho Shinkeigaku (Clin Neurol)* 1995;35:650–652.

2. Kezachian B, Lebrum C, Thomas P, et al. Horner's syndrome secondary to benign multinodular goitre with hyperthyroidism. *Eur J Med* 1993;2:440–441.
3. Cengiz K, Aukin A, Demirci A, Diren B. Intrathoracic goiter with hyperthyroidism, thoracheal compression, super vena cave syndrome and Horner's syndrome. *Chest* 1990;97:1005–1006.
4. Levin R, Newman SA, Login IS. Bilateral Horner's syndrome secondary to multinodular goiter. *Ann Intern Med* 1986;105:550–551.
5. Loway SR, Shunton RA, Jamieson G, Manche A. Benign multinodular goitre and reversible Horner's syndrome. *Br J Med* 1988;296:529–530.
6. Robinson D. Horner's syndrome: a rare complication of multinodular goitre. *N Z Med J* 1987;24:392.
7. Grimson BS, Thomson HS. Reader's syndrome: a clinical review. *Surv Ophthalmol* 1980;2:119–210.
8. Solomon P, Irish J, Gullane F. Horner's syndrome following a thyroidectomy. *J Otolaryngology* 1993;22:454–456.
9. Buhr HJ, Lehnet T, Raue F. New operative strategy in the treatment of metastasizing medullary carcinoma of the thyroid. *Eur J Surg Oncol* 1990;16:366–369.
10. Eversman JJ, Skillern PG, Senhauser DA. Hashimoto's thyroiditis and Graves' disease with exophthalmos without hyperthyroidism. *Cleve Clin Q* 1966;16:366–369.
11. Christy JH, Morse RS. Hypothyroid Graves' disease. *Am J Med* 1977;62:291–296.
12. Sergott RC, Glaser JS. Graves' ophthalmology. A clinical and immunologic review. *Surv Ophthalmol* 1981;26:1–21.
13. Bartley GB, Fatourechi V, Smith FJ. Identification of subgroup of euthyroid Graves' ophthalmopathy in an incidence cohort. *Am J Ophthalmol* 1996;121:284–290.
14. Solomon DH, Chopora IJ, Smith FJ. Identification of subgroup of euthyroid Graves' ophthalmopathy. *N Engl J Med* 1977;296:181–186.
15. Wall JR. Autoimmunity and Graves' ophthalmopathy. The eye and orbit in thyroid disease. New York: Raven Press, 1984:103–119.
16. Morris JGL, Lee J, Lim CL. Facial sweating in Horner's syndrome. *Brain* 1984;107:751–758.
17. Oono S, Saito I, Inukai G, Morisawa K. Traumatic Horner syndrome without anhidrosis. *J Neuroophthalmol* 1999;19:148–151.
18. Hay ID. Clinical presentation of Graves' ophthalmopathy. The eye and orbit in thyroid disease. New York: Raven Press, 1984:129–142.