

Ocular Manifestations and Prognosis of Secondary Glaucoma in Patients with Carotid-Cavernous Fistula

Kiyotaka Ishijima*, Kenji Kashiwagi*, Kenichi Nakano*,
Takashi Shibuya[†], Toyooki Tsumura[‡] and Shigeo Tsukahara*

*Department of Ophthalmology, University of Yamanashi Faculty of Medicine, Tamaho, Yamanashi, Japan;

[†]Eye Clinic, Ichikawa-daimon Municipal Hospital, Ichikawa-daimon, Yamanashi, Japan;

[‡]Eye Clinic, Yamanashi Red Cross Hospital, Kawaguchiko, Yamanashi, Japan

Purpose: To study the frequency of ocular manifestations and the prognosis of secondary glaucoma in cases of carotid-cavernous fistula (CCF).

Methods: A retrospective multicenter study was conducted to investigate causes, types, ocular symptoms, complications, treatment, and prognosis in subjects with CCF.

Results: Among the 43 patients diagnosed with CCF between 1984 and 2000, a total of 13 patients (14 eyes) showed ocular manifestations. CCF was idiopathic in 13 eyes of 12 subjects and resulted from head trauma in 1 eye of 1 subject. Among the ocular symptoms and complications, conjunctival hyperemia was most common, occurring at a rate of 92.9% of the eyes, followed by exophthalmos at 50%, retinal hemorrhaging at 50%, retinal venous dilation at 42.9%, vascular bruits at 28.6%, injection of Schlemm's canal at 21.4%, and external ophthalmoplegia at 21.4%. Elevated intraocular pressure (IOP) occurred at a rate of 64.3%, with maximum IOP ranging from 22–55 mm Hg. At the time of the final observation, IOP control was favorable in 6 of the 9 eyes showing elevated IOP; 5 of these 9 eyes showed a closed CCF, but none required antiglaucoma treatment, with the exception of 1 eye for which trabeculectomy was performed. IOP control was unfavorable in the remaining 3 eyes, and in 1 of these eyes CCF was not closed.

Conclusions: Secondary glaucoma is a frequently observed ocular manifestation of CCF, and closure of the fistula is the primary condition required for favorable IOP control. **Jpn J Ophthalmol 2003;47:603–608** © 2003 Japanese Ophthalmological Society

Key Words: Carotid-cavernous fistula, glaucoma, Matas procedure, trabeculectomy.

Introduction

Carotid-cavernous fistula (CCF) is a condition in which a fistula forms between the peripheral cavernous sinuses, causing damage to the internal carotid artery and its branches. Many of the symptoms and complications of this disorder occur due to elevated venous pressure in the cavernous sinus space, and these vary depending on the extent of shunting. The condition occurs as a result of trauma, and also in an idiopathic form. Cases with idiopathic CCF show a benign course generally, while

those with traumatic CCF sometimes require surgical procedures. Treatments include neurosurgical approaches, the Matas technique in which the carotid artery is compressed, and intracranial embolization by intravascular catheterization.¹

CCF is frequently accompanied by a variety of ocular symptoms and complications, such as conjunctival hyperemia, congestion of the retinal veins, occlusion of the retinal veins, vascular bruits, and external ophthalmoplegia, and it is known to frequently result in secondary glaucoma.^{2,3}

Several reports have appeared to date on the ocular events accompanying CCF,^{4–7} but few studies have focused on the therapeutic course of glaucoma secondary to CCF. For this reason, in the present study, we conducted

Received: August 28, 2002

Correspondence and reprint requests to: Kenji KASHIWAGI, MD, Department of Ophthalmology, University of Yamanashi Faculty of Medicine, 1110 Shimokato, Tamaho, Yamanashi 409-3898, Japan

a retrospective multicenter investigation of secondary glaucoma in patients with CCF.

Materials and Methods

The present cohort was chosen from among 43 patients in whom CCF was diagnosed by doctors other than ophthalmologists (eg, neurosurgeons and other physicians). The patients were then referred to either the ophthalmic outpatient clinic at the University of Yamanashi Hospital or its associated hospitals. A total of 13 patients were enrolled in this retrospective multicenter study from 1984 through 2000. Causes, types of fistula, ocular symptoms, complications, treatments, and prognoses were investigated. All data are expressed as mean \pm SD.

Results

A total of 13 cases of CCF (14 eyes) showed some abnormal ophthalmological findings. The group consisted of 5 men (5 eyes) and 8 women (9 eyes), ranging in age from 33 to 85 years (58 ± 14.8 years). CCF was idiopathic in 12 cases and was due to head trauma in 1 case. The follow-up period was 4.6 ± 2.7 years (6 months to 8.9 years). The ophthalmological findings are shown in Table 1. The majority of cases (13 of 14 eyes; 92.9%) had conjunctival hyperemia for a rate of 92.9%, followed by exophthalmos (7 eyes; 50%), retinal hemorrhaging (7 eyes; 50%), retinal vasodilation (6 eyes; 42.9%), vascular bruits (4 eyes; 28.6%), injection of Schlemm's canal (3 eyes; 21.4%), and external ophthalmoplegia (3 eyes; 21.4%).

Elevated IOP was observed in 9 of the 14 eyes (64.3%) (3 men and 6 women) throughout the follow-up period, with maximum pressure ranging from 22 to 55 mm Hg.

Table 1. Ophthalmological Manifestations

Manifestation	No. of Eyes (%)
Conjunctival hyperemia	13 (92.9)
IOP elevation*	9 (64.3)
Exophthalmos	7 (50.0)
Retinal hemorrhage	7 (50.0)
Retinal vasodilation	6 (42.9)
Bruit	4 (28.6)
Hyperemia of Schlemm's canal	3 (21.4)
External ophthalmoplegia	3 (21.4)

*IOP: intraocular pressure.

Tables 2 and 3 summarize the ophthalmological outcome of these 9 cases. Gonioscopy showed that 7 eyes had an open angle and that 2 eyes had a closed angle. Glaucomatous cupping was observed in 4 eyes and glaucomatous visual field defects were observed in 4 cases. By the final examination, the IOP in 6 eyes (66.7%) was maintained at <22 mm Hg and that in 3 eyes (33.3%) was the same or >22 mm Hg. In the 5 eyes in which it was confirmed that the CCF was closed, effective IOP control was achieved without any medication. On the other hand, of 4 eyes in which the CCF in 1 eye remained open and in 3 eyes in which the CCF was not confirmed to be closed, 3 eyes showed poor IOP control. Three eyes underwent surgical procedures, with one each receiving trabeculectomy, cyclocryo therapy, or cyclophotocoagulation. Three eyes received medical treatment, but their IOP was not well controlled.

A brief summary of each of the 9 cases with elevated IOP follows here.

Case 1

On initial examination, the IOP values were 27 mm Hg in the right eye and 17 mm Hg in the left. Conjunctival hyperemia, retinal vasodilation, and glaucomatous cupping were observed in the right eye. Gonioscopy revealed narrow angle (Shaffer's classification grade 2) and hyperemia of Schlemm's canal in the patient's right eye. Exophthalmos was 19 mm in the right eye and 13 mm in the left. The visual field showed left homonymous hemianopsia, and this was attributed to the effects of a cerebral infarction. Although cerebral angiography could not clearly identify the site of CCF, this case was diagnosed as a case of idiopathic CCF based on these findings. Laser iridotomy was performed on the right eye followed by medication with antiglaucoma eye drops (0.5% timolol maleate, 2% pilocarpine hydrochloride, 0.1% dipivefrin hydrochloride) and internal medicine (acetazolamide). After laser iridotomy, IOP was maintained within a normal range without medication, and there was no progression of either disc cupping or glaucomatous visual field defects.

Case 2

This patient had a history of head trauma. On initial examination, the IOP values were 13 mm Hg in the right eye and 14 mm Hg in the left. Conjunctival hyperemia and retinal vasodilation in the left eye were observed. Exophthalmos was measured at 13 mm in the right eye and 18 mm in the left. Cerebral angiography showed a direct communication between the left internal carotid artery and the cavernous sinus. This patient was diagnosed with left traumatic CCF.

Table 2. General Information on Patients with Intraocular Pressure Elevation

Case No.	Age (y)	Follow-up period (y)	Sex	Eye	Main complaint*	Exophthalmos	Bruit	Types of CCF [†]	Angiography/enhanced CT [‡]
1	73	8.9	F	R	Eyelid swelling	+	–	Idiopathic	UD
2	44	2.0	M	L	Conj. hyperemia	+	+	Traumatic	Direct CCF
3	65	5.9	F	R	Conj. hyperemia	+	–	Idiopathic	Dural AVM
4	62	2.5	F	R	Exophthalmos	+	+	Idiopathic	Dural AVM
5	61	8.0	F	R	Exophthalmos, conj. hyperemia	+	–	Idiopathic	Dural AVM
6	53	2.6	M	R	Blurred vision	–	–	Idiopathic	UD
7	84	0.5	F	L	Conj. hyperemia	–	–	Idiopathic	Dural AVM
8	69	8.9	F	R	Eyelid edema	–	–	Idiopathic	Dural AVM
9	85	4.9	F	L	Conj. hyperemia	–	–	Idiopathic	UD

*Conj.: conjunctival.

[†]CCF: carotid-cavernous fistula.

[‡]CT: computed tomography, UD: undetectable, AVM: arteriovenous malformation.

Case 3

On initial examination, the IOP values were 20 mm Hg in the right eye and 18 mm Hg in the left. Conjunctival hyperemia was observed in the right eye. The angle was wide open (Shaffer’s classification grade 4). Exophthalmos was measured at 17 mm in the right eye and 13.5 in the left. Cerebral angiography showed a right dural arteriovenous malformation (dural AVM).

Case 4

On initial examination, the IOP values were 33 mm Hg in the right eye and 14 mm Hg in the left. Conjunctival hyperemia was observed in the right eye. The angle was wide open (Shaffer’s classification grade 4), and hyperemia of Schlemm’s canal was observed. Exophthalmos was measured at 21 mm in the right eye and 14 mm in the left. Cerebral angiography showed a right dural AVM. The patient was treated with antiglaucoma eye drops (1% pilocarpine hydrochloride, 0.5% timolol maleate), but IOP control was poor. By the final examination, enlargement

of the optic disc cupping was observed and the glaucomatous visual field defect was categorized as Aulhorn’s classification stage 2. Because the patient refused to undergo any surgical procedure, only medication was continued.

Case 5

On initial examination, the IOP values were 32 mm Hg in the right eye and 16 mm Hg in the left. Conjunctival hyperemia, retinal vasodilation, and retinal hemorrhage were observed in the right eye. The visual field defect corresponding to scattered retinal hemorrhage was observed. Gonioscopy revealed a wide-open angle (Shaffer’s classification grade 4) and hyperemia of Schlemm’s canal in the right eye. Exophthalmos was measured at 18 mm in the right eye and 14 mm in the left.

Case 6

Initial examination showed that the IOP values were 55 mm Hg in the right eye and 18 mm Hg in the left.

Table 3. Information on Secondary Glaucoma of Patients with Intraocular Pressure (IOP) Elevation

Case No.	Type of Glaucoma	Maximum IOP (mm Hg)	Disc Cupping	Visual Field	CCF Treatment*	Outcome of Fistula [†]	Outcome of IOP Control	Glaucoma Treatment
1	Angle closure	30	+	+	None	Close	Good	None
2	Open angle	24	–	–	Ballooning	Close	Good	None
3	Open angle	22	–	–	Matas	NA	Good	None
4	Open angle	33	–	–	Matas	Open	Poor	Medication
5	Open angle	32	–	+	Embolization	Close	Good	None
6	Open angle	55	+	+	None	Close	Good	Trabeculectomy
7	Open angle	33	+	+	None	NA	Poor	Cycloceryo, medication
8	Open angle	35	–	–	None	Close	Good	Medication
9	Angle closure	36	+	+	None	NA	Poor	Medication Cyclophotocoagulation

*CCF: carotid-cavernous fistula.

[†]NA: not applicable.

Conjunctival hyperemia and vasodilation in the sclera and retina were observed in the right eye. The angle was wide open (Shaffer's classification grade 4). A kinetic visual field test showed an early-stage glaucomatous defect in the right eye. Cerebral angiography failed to clarify the site of the CCF, but right idiopathic CCF was diagnosed in the patient based on these findings.

Case 7

This patient has sisters with glaucoma. On initial examination, the IOP values were 12 mm Hg in the right eye and 30 mm Hg in the left. Conjunctival hyperemia was observed in the right eye. Gonioscopy revealed a wide-open angle (Shaffer's classification grade 4) and hyperemia of the Schlemm's canal. The visual field defect was categorized as Aulhorn's classification stage 5.

Case 8

On initial examination, the IOP values were 27 mm Hg in the right eye and 16 mm Hg in the left, and conjunctival hyperemia and scleral vasodilation were seen in the right eye (Figure 1a). Paralysis of the right abducens nerve was observed. The angle was wide open (Shaffer's classification grade 4). Contrast computed tomography revealed dilation of the superior ophthalmic vein (Figure 1b). The patient was treated with antiglaucoma eye drops (0.5% timolol maleate). Paralysis of the abducens nerve disappeared, and the conjunctival hyperemia and scleral vasodilation in the right eye also receded (Figure 2).

Case 9

Because the IOP in her left eye was not normalized by medical treatment, this patient was referred to the Yamanashi Medical University Hospital. On initial examination, she showed an IOP value of 17 mm Hg in the right eye, and upon treatment she showed an IOP of 25 mm Hg in the left eye. Conjunctival hyperemia and scleral

vasodilation were observed and the angle was closed (Shaffer's classification grade 1) in the left eye. The glaucomatous visual field defect was categorized as Aulhorn's classification stage 2. The IOP control was poor in spite of treatment using antiglaucoma eye drops (2% pilocarpine hydrochloride, 0.5% timolol maleate, 0.1% dipivefrin hydrochloride, latanoprost, 1% dorzolamide) and cyclophotocoagulation.

Discussion

Two mechanisms of IOP elevation due to CCF have been hypothesized: the open-angle and the closed-angle mechanism.^{8,9} The open-angle mechanism is thought to be a disturbance in outflow facility due to elevation of the episcleral venous pressure. In contrast, it is hypothesized that the closed-angle mechanism involves elevated venous pressure that causes congestion and edema of the choroid and ciliary body, thereby producing forward displacement of the lens-iris diaphragm and, ultimately, a shallow anterior chamber. It has been proposed that CCF may lead to the development of neovascular glaucoma due to ischemia by the obstruction of venous blood flow.^{4,10} In the present study, 7 eyes (77.8%) showed elevated IOP by the open-angle mechanism, and 2 eyes (22.2%) showed elevated IOP by the closed-angle mechanism. In previous reports,^{6,9} 85% of eyes showed elevated IOP by the open-angle mechanism, and 15% showed elevated IOP by the closed-angle mechanism, which is consistent with the present study.

In the present study, 6 of the 9 eyes (66.7%) with a history of IOP elevation during the follow-up period showed effective IOP control. In previous studies, good IOP control has been achieved in 79%⁷ and 96%⁶ of patients with CCF, and although these results are better than those in the present study, the studies cannot be compared directly. In addition, glaucomatous cupping

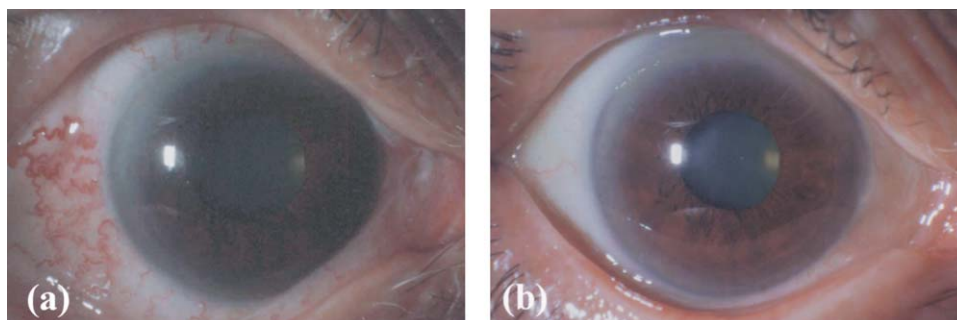


Figure 1. Biomicroscopic images of the right eye in case 8. Conjunctival hyperemia and scleral vasodilation were seen in the right eye on initial examination (a), but disappeared after the closure of carotid-cavernous fistula (b).

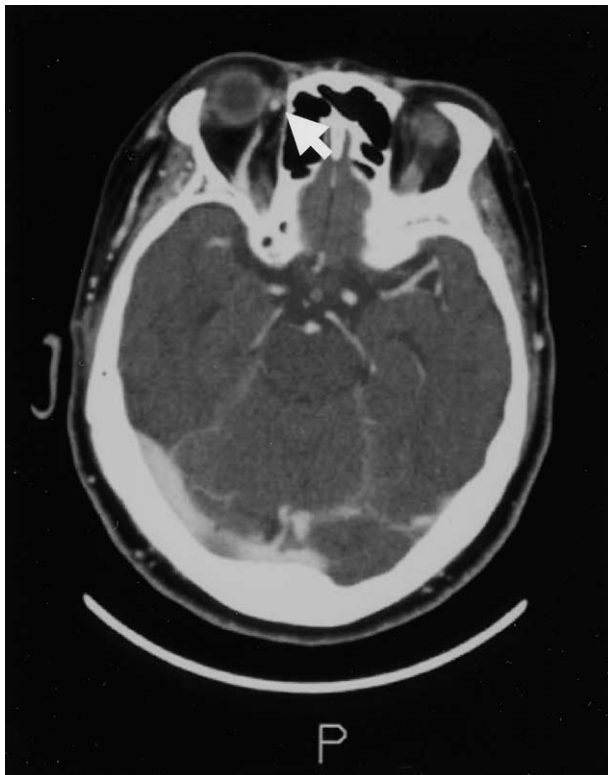

Figure 2. Enhanced computer tomograph of the head in case 8. The superior ophthalmic vein was visualized at an early contrast stage (arrow).

and glaucomatous visual field defects were more frequent in the present study than in a previous report.⁹ Although it has been reported that refractory cases of secondary glaucoma due to CCF are found in eyes with neovascular glaucoma and adhesive closure of the angle,⁹ there were no eyes with neovascular glaucoma and adhesive closure of the angle in the current study. Because the closure of the CCF played a key role in maintaining effective IOP control in the current study, the rate of CCF closure was considered to be responsible, at least in part, for the difference in frequency of glaucoma between the previous and the current study.

The elevated IOP in cases 1, 2, 5, 6, and 8 returned to the normal range after the closure of the CCF. Because it has been reported that chronic elevation of venous pressure sometimes results in neovascular glaucoma,^{4,11} immediate treatment to close the CCF is required.

For precise visualization of the signs and symptoms frequently associated with CCF, which is one of the most important factors influencing the prognosis of secondary glaucoma and other ocular manifestations, angiography and enhanced computed tomography are clearly the best tools.

Although surgical procedures and medical treatment were applied to 4 eyes, none showed effective IOP control except for case 6, whose CCF was possibly closed prior to surgery. Therefore, antiglaucoma treatments may less effectively control IOP in eyes with CCF than would CCF closure.

Filtering surgery is a method of treating CCF accompanying glaucoma.¹² However, it has been reported that severe complications may occur in cases treated in this manner.¹³ Trabeculectomy has been reported to be successful in normalizing IOP.¹² In the present study, trabeculectomy was carried out on only 1 eye, and there were no serious complications. However, in this subject, the CCF may have closed spontaneously prior to the operation, and the mechanism of IOP elevation could be due to an increase of outflow resistance at the area of the trabecular meshwork as a result of chronic elevation of episcleral venous pressure, as previously described,¹⁴ although the precise mechanism is unknown. Careful attention is needed when applying trabeculectomy in the treatment of CCF.

In the current study, an elevated IOP was observed in 64.3% (9/14) of eyes. The current results clearly show that IOP elevation frequently occurs in cases with conjunctival hyperemia as an ophthalmological manifestation in CCF.

The most effective treatment of the manifestations of CCF is closure of the CCF. Madsen et al reported a spontaneous closure of the CCF in 11% of their patients.¹⁵ Because embolization imposes a considerable systemic burden on the patient, the use of this procedure in the elderly is problematic. Indeed, case 9 did not undergo embolization because of the risk of accompanying complications. In such cases, it is considered important to use procedures with a relatively low level of invasiveness, such as the Matas procedure, in an effort to close the CCF to as great a degree as possible.

Although the initial cohort in the present study included both CCF patients with and those without ocular manifestations, we cannot assume that the observed frequency of ocular manifestation in CCF was representative of that in the general population, because the total number of cases was relatively small. Further studies will thus be needed to determine the occurrence rate of ocular manifestations.

Finally, we investigated the frequency of ocular manifestations and the prognosis of eyes with CCF only in patients who had been referred from outpatient clinics of the associated hospitals of the University of Yamaguchi. It will be necessary in future studies to examine not only patients who were referred but also those who were

observed by doctors in other departments of the associated hospitals.

The authors deeply appreciate Dr. Hiroyuki Iijima's excellent comments.

References

1. Phatouros CC, Meyers PM, Dowd CF, et al. Carotid artery cavernous fistulas. *Neurosurg Clin N Am* 2000;11:67–84, viii.
2. Phillips PH. Carotid-cavernous fistulas. *Neurosurg Clin N Am* 1999;10:653–665, ix.
3. Duke PS. Carotico-cavernous fistula and glaucoma. *Aust N Z J Surg* 1967;36:288–297.
4. Sugar HS. Neovascular glaucoma after carotid-cavernous fistula formation. *Ann Ophthalmol* 1979;11:1667–1669.
5. Slusher MM, Lenington BR, Weaver RG, et al. Ophthalmic findings in dural arteriovenous shunts. *Ophthalmology* 1979; 86:720–731.
6. Khator P, Scott IU, Gedde SJ, et al. Visual acuity and intraocular pressure outcomes in patients with carotid-cavernous fistulas [ARVO abstract]. *Invest Ophthalmol Vis Sci* 2001;42:S823 (abstract no. 4419).
7. Kupersmith MJ, Berenstein A, Flamm E, et al. Neuroophthalmologic abnormalities and intravascular therapy of traumatic carotid cavernous fistulas. *Ophthalmology* 1986;93:906–912.
8. Phelps CD, Thompson HS, Ossoinig KC. The diagnosis and prognosis of atypical carotid-cavernous fistula (red-eyed shunt syndrome). *Am J Ophthalmol* 1982;93:423–436.
9. Weinreb RN, Karwatowski WSS. The glaucomas. In: Ritch R, Shields B, Krupin T, eds. *The glaucomas*. St. Louis: Mosby, 1996:1143–1155.
10. Barke RM, Yoshizumi MO, Hepler RS, et al. Spontaneous dural carotid-cavernous fistula with central retinal vein occlusion and iris neovascularization. *Ann Ophthalmol* 1991;23:11–17.
11. Fiore PM, Latina MA, Shingleton BJ, et al. The dural shunt syndrome. I. Management of glaucoma. *Ophthalmology* 1990; 97:56–62.
12. Pfau B, Rohrschneider K, Kruse FE, et al. Goniotripanation combined with sinus surgery as a transitional measure in spontaneous carotid artery-cavernous sinus fistulas. *Ophthalmologie* 1993;90:567–569.
13. Walsh TJ. *Neuroophthalmology clinical signs and symptoms*. Philadelphia: Lea & Febiger, 1985.
14. Nordmann J, Lobstein A, Gerhard JP. A propos de 14 cas de glaucoma par hypertension veineuse d'origine extraoculaire. *Ophthalmol Suppl* 1961;142:501–505.
15. Madsen PH. Carotid-cavernous fistulae. A study of 18 cases. *Acta Ophthalmol* 1970;48:731–751.